A 45-year-old man with diabetes mellitus is admitted to the intensive care unit due to community-acquired pneumonia, septic shock, and respiratory failure. Two days ago, he developed fever, productive cough, and shortness of breath that has progressively worsened. The patient is intubated and placed on mechanical ventilation. He is also started on intravenous fluids, broad-spectrum antibiotics, and a norepinephrine infusion. On the third day of hospitalization, hemoglobin level drops from 14 g/dL to 12 g/dL. Nasogastric suctioning reveals bright red blood. This patient's bleeding is most likely a result of which of the following processes?

- A. Autoimmune parietal cell destruction (2%)
- B. Gastrin-secreting tumor (1%)
- C. Granuloma formation (2%)
- D. *Helicobacter pylori* infection (6%)
- E. Malignant transformation (1%)
- ✓ F. Stress-related mucosal injury (85%)

Omitted
Correct answer
F

85%
Answered correctly

02 secs
Time Spent

02/27/2020
Last Updated

Explanation

Stress-related mucosal disease

Shock, trauma, burns | Intracranial disease

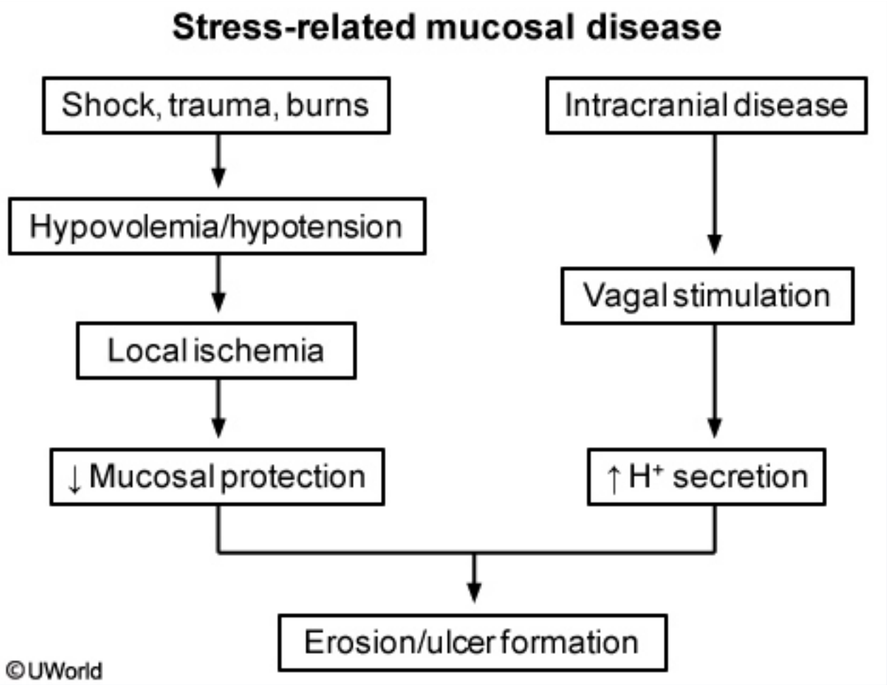

Stress-related mucosal disease is characterized by acute gastric mucosal defects that develop in response to severe **physiologic stress** (eg, shock, extensive burns, sepsis, severe trauma, intracranial injury). Patients often have multiple, small (<1 cm), circular lesions in the stomach, ranging from superficial erosions to full-thickness ulcers. Ulcers may perforate or **bleed**, as in this patient.

The pathogenesis of these ulcers most often involves impaired mucosal protection due to **local ischemia** caused by systemic hypotension and splanchnic vasoconstriction. Ulcers arising in the proximal duodenum in association with severe trauma/burns are called **Curling ulcers**. Ulcers arising in the esophagus, stomach, or duodenum in patients with intracranial injury are particularly prone to perforation and are called **Cushing ulcers**. Cushing ulcers are a consequence of **direct vagus nerve stimulation** caused by elevated intracranial pressure, resulting in acetylcholine release and hypersecretion of gastric acid.

(Choice A) Chronic gastritis with antral sparing is characteristic of autoimmune gastritis. CD4+ T cell-mediated parietal cell destruction causes impaired gastric acid and intrinsic factor secretion, resulting in achlorhydria and pernicious anemia, respectively.

Stress-related mucosal disease is characterized by acute gastric mucosal defects that develop in response to severe **physiologic stress** (eg, shock, extensive burns, sepsis, severe trauma, intracranial injury). Patients often have multiple, small (<1 cm), circular lesions in the stomach, ranging from superficial erosions to full-thickness ulcers. Ulcers may perforate or **bleed**, as in this patient.

The pathogenesis of these ulcers most often involves impaired mucosal protection due to **local ischemia** caused by systemic hypotension and splanchnic vasoconstriction. Ulcers arising in the proximal duodenum in association with severe trauma/burns are called **Curling ulcers**. Ulcers arising in the esophagus, stomach, or duodenum in patients with intracranial injury are particularly prone to perforation and are called **Cushing ulcers**. Cushing ulcers are a consequence of **direct vagus nerve stimulation** caused by elevated intracranial pressure, resulting in acetylcholine release and hypersecretion of gastric acid.

(Choice A) Chronic gastritis with antral sparing is characteristic of autoimmune gastritis. CD4+ T cell-mediated parietal cell destruction causes impaired gastric acid and intrinsic factor secretion, resulting in achlorhydria and pernicious anemia, respectively.

(Choice B) Zollinger-Ellison syndrome is caused by a gastrin-secreting tumor (gastrinoma) that is usually located in the small intestine or pancreas. Patients classically have multiple peptic ulcers that may involve the distal duodenum and are more likely to respond poorly to therapy.

(Choice C) Granulomatous gastritis is most often idiopathic but may be associated with Crohn disease, sarcoidosis, or mycobacterial infection. It is characterized by intramucosal epithelioid granulomas that cause narrowing of the antrum secondary to transmural inflammation, which can result in gastric outlet obstruction.

(Choice D) Peptic ulcers in the stomach or duodenum are most commonly due to *Helicobacter pylori* infection or nonsteroidal anti-inflammatory drug use. *H pylori* infection is also associated with chronic antral-predominant gastritis.

(Choice E) Gastric adenocarcinoma can occur as the intestinal subtype (ie, bulky mass composed of glandular structures) or diffuse subtype (ie, gross stomach wall thickening with signet-ring cells on microscopy). Risk factors for gastric adenocarcinoma include chronic gastritis, cigarette smoking, *H pylori* infection, and a diet high in salt/nitrosamines.

Educational objective:
Stress-related mucosal disease is usually caused by local ischemia in the setting of severe physiologic stress (eg, shock, extensive burns, sepsis, severe trauma). Ulcers arising in the setting of severe trauma/burns are called Curling ulcers. Ulcers arising from intracranial injury are caused by

impaired gastric acid and intrinsic factor secretion, resulting in achlorhydria and pernicious anemia, respectively.

(Choice B) Zollinger-Ellison syndrome is caused by a gastrin-secreting tumor (gastrinoma) that is usually located in the small intestine or pancreas. Patients classically have multiple peptic ulcers that may involve the distal duodenum and are more likely to respond poorly to therapy.

(Choice C) Granulomatous gastritis is most often idiopathic but may be associated with Crohn disease, sarcoidosis, or mycobacterial infection. It is characterized by intramucosal epithelioid granulomas that cause narrowing of the antrum secondary to transmural inflammation, which can result in gastric outlet obstruction.

(Choice D) Peptic ulcers in the stomach or duodenum are most commonly due to *Helicobacter pylori* infection or nonsteroidal anti-inflammatory drug use. *H pylori* infection is also associated with chronic antral-predominant gastritis.

(Choice E) Gastric adenocarcinoma can occur as the intestinal subtype (ie, bulky mass composed of glandular structures) or diffuse subtype (ie, gross stomach wall thickening with signet-ring cells on microscopy). Risk factors for gastric adenocarcinoma include chronic gastritis, cigarette smoking, *H pylori* infection, and a diet high in salt/nitrosamines.

Educational objective:
Stress-related mucosal disease is usually caused by local ischemia in the setting of severe physiologic stress (eg, shock, extensive burns, sepsis, severe trauma). Ulcers arising in the setting of severe trauma/burns are called Curling ulcers. Ulcers arising from intracranial injury are caused by direct vagal stimulation and are called Cushing ulcers.

References

- Stress-related mucosal disease in the intensive care unit: an update on prophylaxis.
- Stress ulceration: prevalence, pathology and association with adverse outcomes.

Pathology	Gastrointestinal & Nutrition	Stress gastric ulcer
Subject	System	Topic

Copyright © UWorld. All rights reserved.

A 28-year-old man with vague abdominal pain, low-grade fever, and diarrhea is treated with antibiotics without significant improvement in his symptoms. Several weeks after symptom onset, the patient develops a skin lesion over the abdomen. His temperature is 37.8 C (100 F), blood pressure is 120/70 mm Hg, and pulse is 88/min. On physical examination, the abdomen is mildly distended and tender to palpation. Bowel contents appear to be draining to the surface of the skin in the right lower abdominal quadrant. This patient most likely suffers from which of the following conditions?

A. Acute appendicitis

B. Crohn disease

C. Mesenteric adenitis

D. Pseudomembranous colitis

E. Ulcerative colitis

Submit

A 28-year-old man with vague abdominal pain, low-grade fever, and diarrhea is treated with antibiotics without significant improvement in his symptoms. Several weeks after symptom onset, the patient develops a skin lesion over the abdomen. His temperature is 37.8 C (100 F), blood pressure is 120/70 mm Hg, and pulse is 88/min. On physical examination, the abdomen is mildly distended and tender to palpation. Bowel contents appear to be draining to the surface of the skin in the right lower abdominal quadrant. This patient most likely suffers from which of the following conditions?

- A. Acute appendicitis (7%)
- ✓ B. Crohn disease (68%)
- C. Mesenteric adenitis (11%)
- D. Pseudomembranous colitis (7%)
- E. Ulcerative colitis (5%)

Omitted
Correct answer
B

68%
Answered correctly

02 secs
Time Spent

06/07/2020
Last Updated

Explanation

	Crohn disease	Ulcerative colitis
Involvement	• Anywhere mouth to anus (mostly ileum & colon) • Perianal disease with rectal sparing	• Rectum (always) & colon • Continuous lesions

	Crohn disease	Ulcerative colitis
Involvement	• Anywhere mouth to anus (mostly ileum & colon) • Perianal disease with rectal sparing • Skip lesions	• Rectum (always) & colon • Continuous lesions
Microscopy	• Noncaseating granulomas	• No granulomas
Gross findings	• Transmural inflammation • Linear mucosal ulcerations • Cobblestoning, creeping fat	• Mucosal & submucosal inflammation • Pseudopolyps
Clinical manifestations	• Abdominal pain (often RLQ) • Watery diarrhea (bloody if colitis)	• Abdominal pain (varying locations) • Bloody diarrhea
Intestinal complications	• Fistulae, abscesses • Strictures (bowel obstruction)	• Toxic megacolon

RLQ = right lower quadrant.

Crohn disease and ulcerative colitis are collectively referred to as inflammatory bowel disease. They may have similar clinical manifestations, but they also have key distinguishing features (Table).

Crohn disease typically presents with **prolonged diarrhea** and **abdominal pain**. Diarrhea can be bloody if the colon is involved. Constitutional symptoms (eg, low-grade fever, fatigue), malabsorption, and weight loss are also common. **Transmural inflammation** of the bowel wall may result in the formation of fistulas and fibrotic strictures, causing bowel obstruction. Fistulas can form between 2 adjacent loops of bowel (enteroenteric fistula), between the bowel and another organ (eg, bladder, vagina), or between the bowel and skin of the abdominal wall (**enterocutaneous fistula**). Perianal fistulas and abscesses are also often seen.

Ulcerative colitis typically presents with bloody diarrhea associated with abdominal pain and tenesmus. Fistula formation does not usually occur as inflammation is confined to the mucosa and submucosa **(Choice E)**.

RLQ = right lower quadrant.

Crohn disease and ulcerative colitis are collectively referred to as inflammatory bowel disease. They may have similar clinical manifestations, but they also have key distinguishing features (Table).

Crohn disease typically presents with **prolonged diarrhea** and **abdominal pain**. Diarrhea can be bloody if the colon is involved. Constitutional symptoms (eg, low-grade fever, fatigue), malabsorption, and weight loss are also common. **Transmural inflammation** of the bowel wall may result in the formation of fistulas and fibrotic strictures, causing bowel obstruction. Fistulas can form between 2 adjacent loops of bowel (enteroenteric fistula), between the bowel and another organ (eg, bladder, vagina), or between the bowel and skin of the abdominal wall (**enterocutaneous fistula**). Perianal fistulas and abscesses are also often seen.

Ulcerative colitis typically presents with bloody diarrhea associated with abdominal pain and tenesmus. Fistula formation does not usually occur as inflammation is confined to the mucosa and submucosa **(Choice E)**.

(Choice A) Right lower quadrant abdominal pain, fever, nausea, and vomiting are classic symptoms of acute appendicitis. If untreated, appendicitis may progress to peritonitis or abscess formation, but fistula formation is not common.

(Choice C) Mesenteric adenitis most often occurs in children age 5-14. Many cases are thought to be associated with *Yersinia enterocolitica* infection. Clinical manifestations may include fever, right lower quadrant abdominal pain, and nausea/vomiting, but fistulas are not characteristic.

(Choice D) Pseudomembranous colitis is typically caused by *Clostridium difficile* infection and presents with diarrhea, abdominal pain, and fever in a patient who has recently been hospitalized or treated with antibiotics. Fistulas are not typically seen.

Educational objective:
Crohn disease typically presents with prolonged diarrhea and abdominal pain. Constitutional symptoms (eg, low-grade fever, fatigue), malabsorption, and weight loss are also common. Transmural inflammation of the bowel wall may result in the formation of fistulas (eg, enteroenteric, enterocutaneous), abscesses, and fibrotic strictures.

References

- Diagnosis and management of Crohn's disease.
- Natural history and long-term clinical course of Crohn's disease.

A 45-year-old woman comes to the office for progressive itchiness and fatigue. She also notes yellowing of the eyes and skin. Physical examination shows scleral icterus, multiple excoriations on both the upper and the lower extremities, and hepatomegaly. Laboratory results are as follows:

Liver function studies

Total bilirubin	5.3 mg/dL
Alkaline phosphatase	982 U/L
Aspartate aminotransferase (SGOT)	89 U/L
Alanine aminotransferase (SGPT)	67 U/L
Gamma-glutamyl transpeptidase	450 U/L

Liver biopsy reveals dense lymphocytic infiltration of the portal triads, as well as granulomatous destruction of intralobular bile ducts. Which of the following is the most likely diagnosis?

A. Acute hepatitis B
B. Autoimmune hepatitis
C. Primary biliary cholangitis
D. Primary sclerosing cholangitis
E. Sarcoidosis

Submit

follows:

Liver function studies

Total bilirubin	5.3 mg/dL
Alkaline phosphatase	982 U/L
Aspartate aminotransferase (SGOT)	89 U/L
Alanine aminotransferase (SGPT)	67 U/L
Gamma-glutamyl transpeptidase	450 U/L

Liver biopsy reveals dense lymphocytic infiltration of the portal triads, as well as granulomatous destruction of intralobular bile ducts. Which of the following is the most likely diagnosis?

A. Acute hepatitis B (1%)

B. Autoimmune hepatitis (4%)

✓ C. Primary biliary cholangitis (75%)

D. Primary sclerosing cholangitis (14%)

E. Sarcoidosis (3%)

Omitted
Correct answer
C

75%
Answered correctly

02 secs
Time Spent

03/31/2020
Last Updated

Explanation

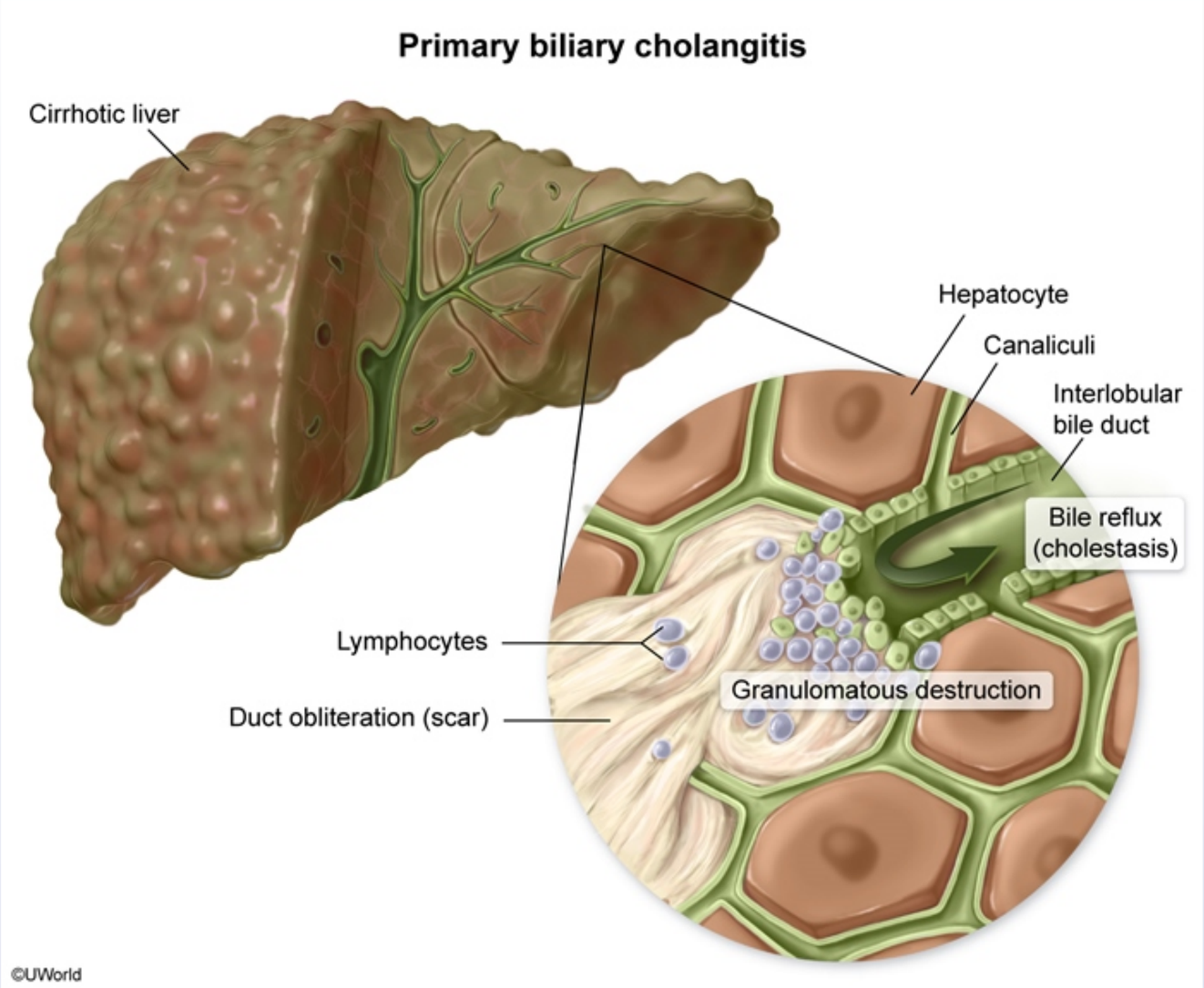

This patient with fatigue, pruritus, jaundice, and elevated alkaline phosphatase has liver biopsy results consistent with **primary biliary cholangitis**.

This patient with fatigue, pruritus, jaundice, and elevated alkaline phosphatase has liver biopsy results consistent with **primary biliary cholangitis** (PBC), a chronic autoimmune disorder that disproportionately affects **middle-aged women**. PBC is characterized by T-cell–mediated destruction of the small intralobular bile ducts, which is visualized histologically as a **dense lymphocytic inflammation** of portal tracts with **granulomatous destruction of interlobular bile ducts** (ie, florid duct lesions).

PBC typically develops insidiously; **fatigue** and **pruritus** are often the presenting symptoms. **Cholestasis** results in a characteristic pattern of liver injury (ie, **elevated alkaline phosphatase**, elevated gamma-glutamyl transferase, direct hyperbilirubinemia, normal or mildly elevated aminotransferases) and examination findings (eg, hepatomegaly, jaundice). Hypercholesterolemia is also common due to reduced cholesterol excretion. Elevated **antimitochondrial antibodies** are highly characteristic.

(Choices A and B) Acute hepatitis B and autoimmune hepatitis (AIH) both result in a hepatocellular, not a cholestatic, pattern of liver injury. Hepatitis B is characterized histologically by lobular mononuclear inflammation, hepatocyte balloon degeneration, and ground-glass hepatocytes, whereas AIH results in portal and periportal lymphoplasmacytic infiltration of the liver (ie, interface hepatitis).

(Choice D) Primary sclerosing cholangitis causes a cholestatic pattern of liver injury but it is identified histologically by fibrous obliteration of bile ducts, as well as concentric periductal deposition of connective tissue in an onion skin–like pattern. It is strongly associated with ulcerative colitis.

(Choice E) Sarcoidosis can cause a cholestatic pattern of liver injury but is characterized by noncaseating granulomas with hepatic fibrosis and a multinucleated giant cell formation. The dense portal lymphocytic infiltration characteristic of PBC is not seen. In addition, most patients have symptoms of systemic sarcoidosis (eg, cough, hilar lymphadenopathy).

Educational objective:
Primary biliary cholangitis is an autoimmune disorder that most commonly affects middle-aged women and is characterized by fatigue, pruritus, jaundice, cholestasis (eg, elevated alkaline phosphatase, elevated gamma-glutamyl transferase, direct hyperbilirubinemia), and antimitochondrial antibodies. Histologic findings include dense lymphocytic portal tract inflammation with granulomatous destruction of interlobular bile ducts (ie, florid duct lesions).

References

- Primary biliary cirrhosis: pathophysiology, clinical presentation and therapy.
- Pathogenesis of primary biliary cirrhosis.

This patient with fatigue, pruritus, jaundice, and elevated alkaline phosphatase has liver biopsy results consistent with **primary biliary cholangitis** (PBC), a chronic autoimm ion of the small intralobular bi us **destruction of interlobul**

PBC typically develops ins liver injury (ie, **elevated al** aminotransferases) and e excretion. Elevated **antim**

(Choices A and B) Acute Hepatitis B is characterize es, whereas AIH results in po

(Choice D) Primary scler le ducts, as well as concentr tis.

(Choice E) Sarcoidosis c d a multinucleated giant cell f symptoms of systemic sar

Educational objective:
Primary biliary cholangitis jaundice, cholestasis (eg, ial antibodies. Histologic finc florid duct lesions).

References

- Primary biliary cirrhosi
- Pathogenesis of primary biliary cirrhosis

Exhibit Display

Patterns of liver injury

Hepatocellular	Cholestatic
• AST & ALT >> alkaline phosphatase • ↑ Bilirubin	• Alkaline phosphatase >> AST & ALT • ↑ Bilirubin • ↑ Gamma-glutamyl transferase

AST = aspartate transaminase; **ALT** = alanine aminotransferase.

Add To New Card | Existing Card

Settings

1 2 3 4 5 6 7 8 9 10 11 12 13 14 15 16 17 18 19 20 21 22 23 24 25 26 27 28 29 30

Item 3 of 40
Question Id: 403

Mark | Previous | Next | Full Screen | Tutorial | Lab Values | Notes | Calculator | Reverse Color | Text Zoom | Settings

This patient with fatigue, pruritus, jaundice, and elevated alkaline phosphatase has liver biopsy results consistent with **primary biliary cholangitis**.

Exhibit Display

Noncaseating granuloma

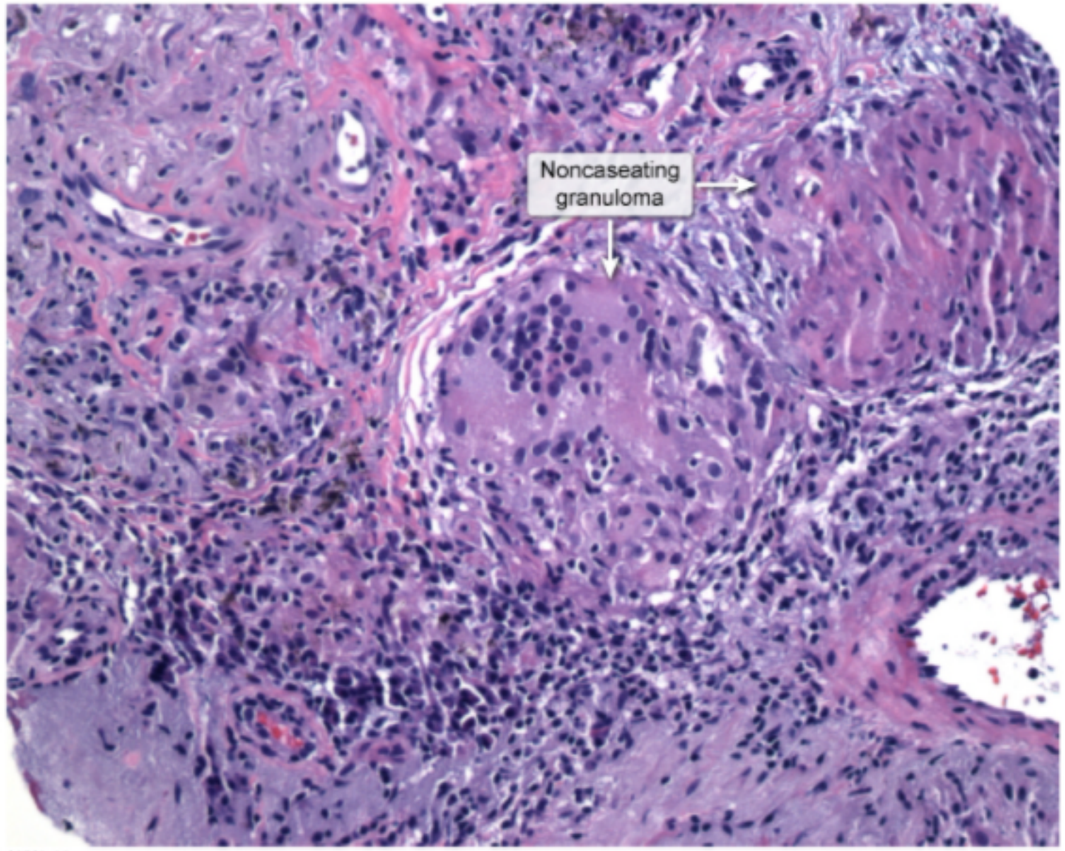

Zoom In | Zoom Out | Reset | Add To New Card | Existing Card

- Pathogenesis of primary biliary cirrhosis

Block Time Remaining: 00:00:06
TUTOR

3 | Feedback | Suspend | End Block

A 46-year-old woman comes to the office due to dysphagia. The patient has had difficulty swallowing both liquids and solid foods as well as frequent episodes of regurgitation and cough while eating. She has also had weakness in her extremities and a rash. The patient has no prior medical problems and takes no medications. Vital signs are within normal limits. Physical examination shows an erythematous eruption on the upper eyelids. The oropharynx is clear and cardiopulmonary and abdominal examinations are unremarkable. She has difficulty lifting her arms above her head and standing from a sitting position. Which of the following is the most likely cause of this patient's dysphagia?

A. Atrophy and fibrous replacement of the distal esophageal muscularis propria

B. Diffuse eosinophil-predominant inflammation of the esophageal mucosa

C. Inflammation and degeneration of the esophageal myenteric plexus

D. Outpouching of hypopharyngeal mucosa through weakened muscle

E. Perifascicular atrophy of muscle fibers in the proximal esophageal muscularis propria

Submit

A 46-year-old woman comes to the office due to dysphagia. The patient has had difficulty swallowing both liquids and solid foods as well as frequent episodes of regurgitation and cough while eating. She has also had weakness in her extremities and a rash. The patient has no prior medical problems and takes no medications. Vital signs are within normal limits. Physical examination shows an erythematous eruption on the upper eyelids. The oropharynx is clear and cardiopulmonary and abdominal examinations are unremarkable. She has difficulty lifting her arms above her head and standing from a sitting position. Which of the following is the most likely cause of this patient's dysphagia?

- A. Atrophy and fibrous replacement of the distal esophageal muscularis propria (24%)
- B. Diffuse eosinophil-predominant inflammation of the esophageal mucosa (7%)
- C. Inflammation and degeneration of the esophageal myenteric plexus (18%)
- D. Outpouching of hypopharyngeal mucosa through weakened muscle (2%)
- ✓ E. Perifascicular atrophy of muscle fibers in the proximal esophageal muscularis propria (46%)

Omitted
Correct answer
E

46%
Answered correctly

02 secs
Time Spent

03/01/2020
Last Updated

Explanation

This patient has painless **proximal muscle weakness**; in association with the heliotrope **rash** on her eyelids, this presentation is consistent with **dermatomyositis**, an inflammatory myopathy that primarily affects **striated muscle** and skin. Diagnostic findings include elevated muscle enzymes (eg, creatinine kinase) and positive autoantibodies (ie, antinuclear antibody [high sensitivity, low specificity], anti–Jo-1 [low sensitivity, high specificity]). Muscle biopsy in dermatomyositis shows perimysial inflammatory infiltrates and atrophy involving the fibers around the periphery of muscle fascicles (**perifascicular atrophy**).

This patient has painless **proximal muscle weakness**; in association with the heliotrope **rash** on her eyelids, this presentation is consistent with **dermatomyositis**, an inflammatory myopathy that primarily affects **striated muscle** and skin. Diagnostic findings include elevated muscle enzymes (eg, creatinine kinase) and positive autoantibodies (ie, antinuclear antibody [high sensitivity, low specificity], anti–Jo-1 [low sensitivity, high specificity]). Muscle biopsy in dermatomyositis shows perimysial inflammatory infiltrates and atrophy involving the fibers around the periphery of muscle fascicles **(perifascicular atrophy)**.

The **oropharynx and upper esophagus** also contain skeletal muscle that can be affected in dermatomyositis and polymyositis, leading to **dysphagia** and pulmonary aspiration. Other important complications of inflammatory myopathies include interstitial lung disease and **myocarditis** (due to involvement of striated cardiac muscle).

(Choice A) Progressive systemic sclerosis (scleroderma) commonly affects the esophagus, leading to atrophy and fibrous replacement of the distal esophageal muscularis propria. Clinical features include dysphagia, reflux esophagitis, and aspiration. However, the dermal manifestations include sclerodactyly, digital ulcers, and calcinosis cutis, rather than a heliotrope rash. Also, dermatomyositis affects only the striated muscle in the oropharynx and upper esophagus (eg, choking, aspiration), whereas scleroderma can affect the lower esophagus.

(Choice B) Eosinophilic esophagitis typically presents with dysphagia, epigastric pain, recurrent esophageal reflux, and food impaction. Skin rash and extremity weakness would be unexpected.

(Choice C) Achalasia is caused by inflammation and degeneration of the esophageal myenteric plexus, resulting in impaired relaxation of the smooth muscle in the distal esophagus and lower esophageal sphincter. It typically presents with dysphagia, regurgitation, and heartburn but is not associated with rash or skeletal muscle weakness.

(Choice D) Zenker diverticulum develops immediately above the upper esophageal sphincter, with posterior mucosal herniation between the fibers of the cricopharyngeus muscle. Although it presents with dysphagia, regurgitation, and aspiration, it is not associated with rash or muscular weakness.

Educational objective:
Dermatomyositis is characterized by proximal muscle weakness resembling polymyositis, with additional inflammatory features affecting the skin (eg, heliotrope rash, Gottron papules). In both conditions, involvement of striated muscle in the oropharynx and heart can lead to dysphagia, pulmonary aspiration, and myocarditis.

The **oropharynx and upper esophagus** also contain skeletal muscle that can be affected in dermatomyositis and polymyositis, leading to **dysphagia** and pulmonary aspiration. Other important complications of inflammatory myopathies include interstitial lung disease and **myocarditis** (due to involvement of striated cardiac muscle).

(Choice A) Progressive systemic sclerosis (scleroderma) commonly affects the esophagus, leading to atrophy and fibrous replacement of the distal esophageal muscularis propria. Clinical features include dysphagia, reflux esophagitis, and aspiration. However, the dermal manifestations include sclerodactyly, digital ulcers, and calcinosis cutis, rather than a heliotrope rash. Also, dermatomyositis affects only the striated muscle in the oropharynx and upper esophagus (eg, choking, aspiration), whereas scleroderma can affect the lower esophagus.

(Choice B) Eosinophilic esophagitis typically presents with dysphagia, epigastric pain, recurrent esophageal reflux, and food impaction. Skin rash and extremity weakness would be unexpected.

(Choice C) Achalasia is caused by inflammation and degeneration of the esophageal myenteric plexus, resulting in impaired relaxation of the smooth muscle in the distal esophagus and lower esophageal sphincter. It typically presents with dysphagia, regurgitation, and heartburn but is not associated with rash or skeletal muscle weakness.

(Choice D) Zenker diverticulum develops immediately above the upper esophageal sphincter, with posterior mucosal herniation between the fibers of the cricopharyngeus muscle. Although it presents with dysphagia, regurgitation, and aspiration, it is not associated with rash or muscular weakness.

Educational objective:
Dermatomyositis is characterized by proximal muscle weakness resembling polymyositis, with additional inflammatory features affecting the skin (eg, heliotrope rash, Gottron papules). In both conditions, involvement of striated muscle in the oropharynx and heart can lead to dysphagia, pulmonary aspiration, and myocarditis.

Pathology	Gastrointestinal & Nutrition	Polymyositis and dermatomyositis
Subject	System	Topic

Copyright © UWorld. All rights reserved.

A 24-year-old woman comes to the office due to recurrent bloody diarrhea and right-sided abdominal pain. She has had these symptoms intermittently for several years but has not sought medical attention. Colonoscopy shows evidence of inflammation and dysplasia. The patient subsequently undergoes a colectomy of the involved region; findings are shown in the image.

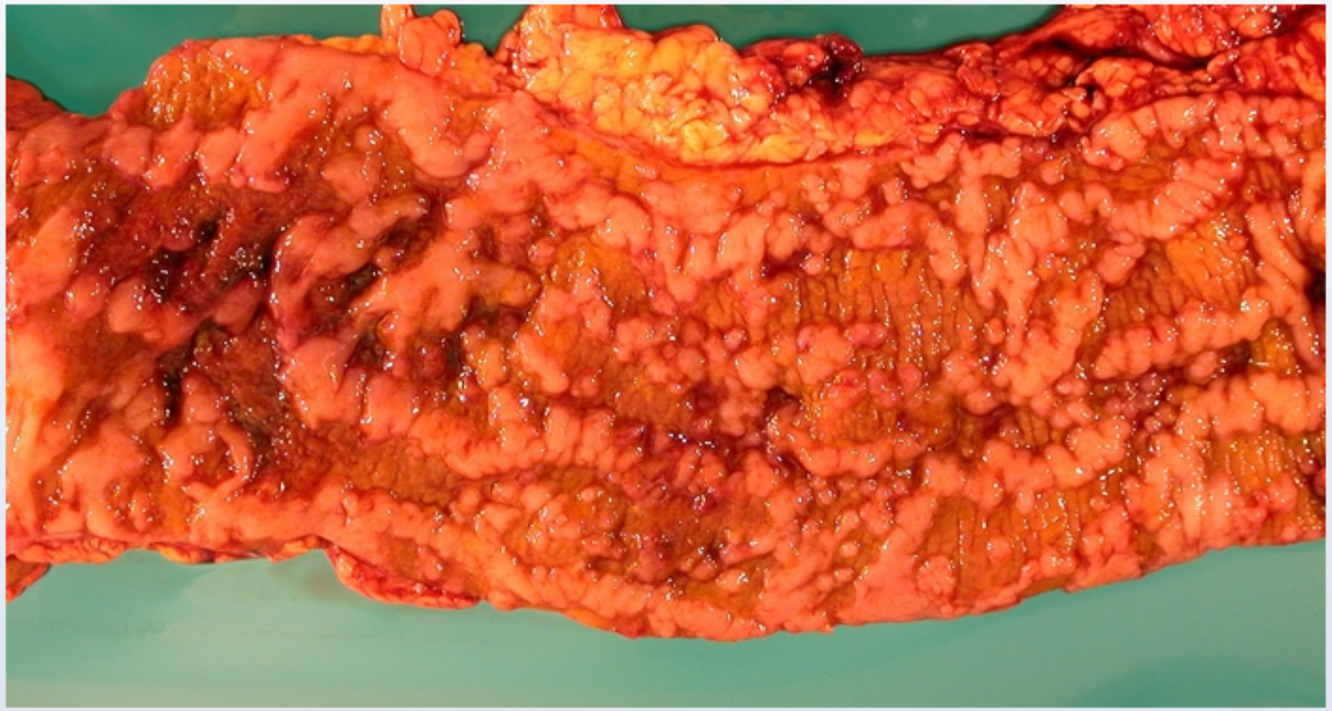

The intestinal wall was thickened overall. Which of the following is the most likely diagnosis?

- A. Amoebic dysentery
- B. Collagenous microscopic colitis
- C. Crohn disease

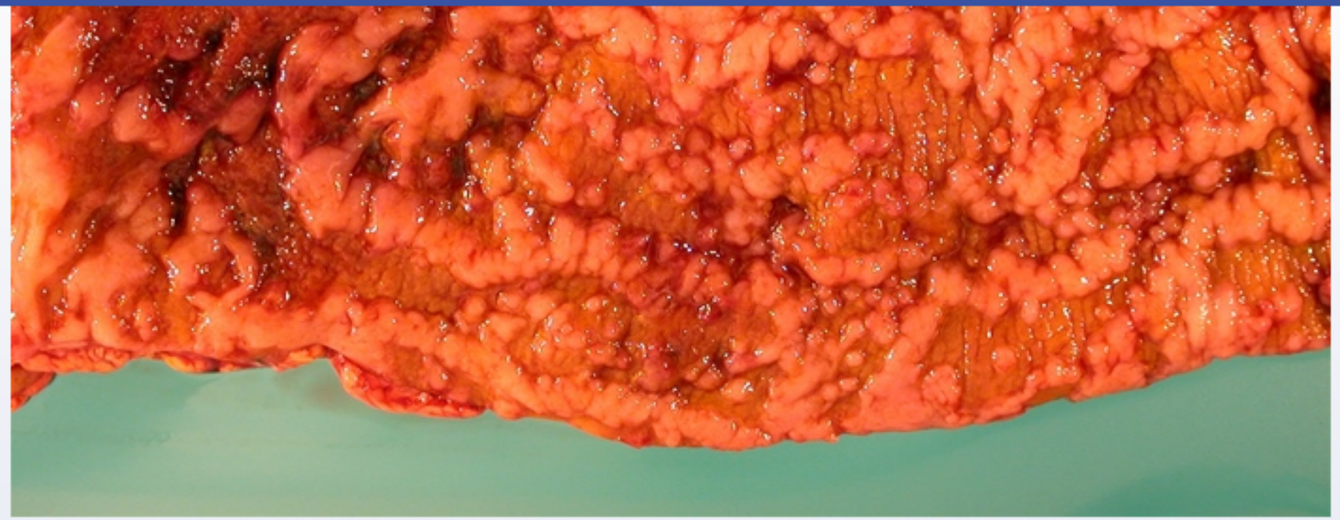

The intestinal wall was thickened overall. Which of the following is the most likely diagnosis?

A. Amoebic dysentery

B. Collagenous microscopic colitis

C. Crohn disease

D. Graft-versus-host disease

E. Pseudomembranous colitis

F. Ulcerative colitis

Submit

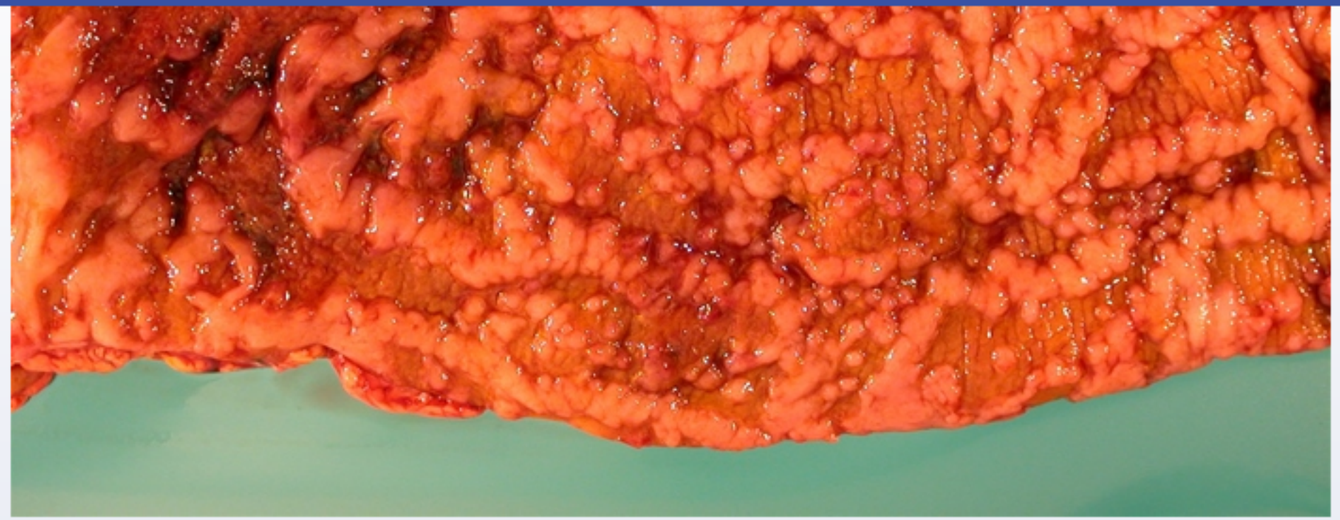

The intestinal wall was thickened overall. Which of the following is the most likely diagnosis?

- A. Amoebic dysentery (0%)
- B. Collagenous microscopic colitis (1%)
- ✓ C. Crohn disease (67%)
- D. Graft-versus-host disease (0%)
- E. Pseudomembranous colitis (1%)
- F. Ulcerative colitis (29%)

Omitted
Correct answer

67%
Answered correctly

06 secs
Time Spent

03/30/2020
Last Updated

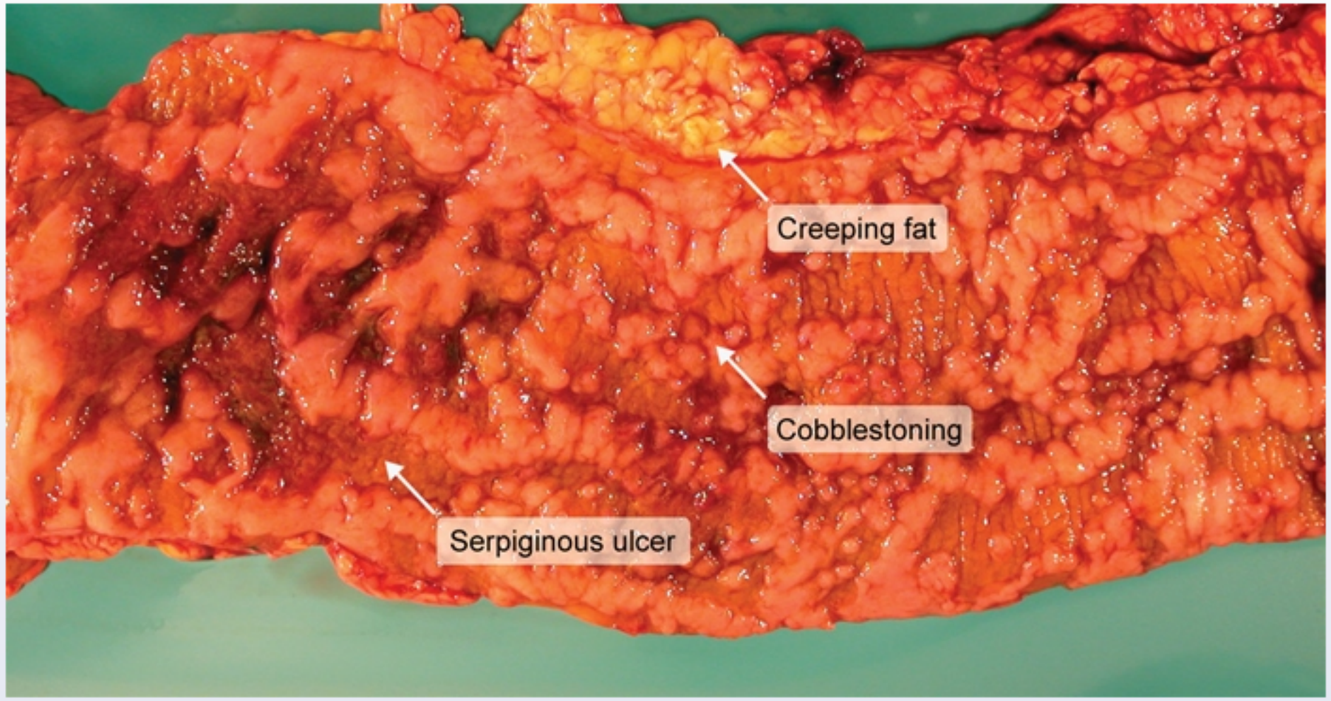

Crohn disease (CD) is an inflammatory bowel disease characterized by patchy inflammation that can occur throughout the entire gastrointestinal (GI) tract; patients commonly complain of relapsing and remitting abdominal pain, diarrhea (with or without blood), and weight loss. CD typically involves the ileum; however, up to 20% of patients have only colonic involvement. Unlike ulcerative colitis, which is characterized by continuous inflammation of the colon limited to the mucosa and submucosa, inflammation in CD is **transmural** (full thickness) and **segmental** in nature. This leads to recognizable manifestations on gross pathology, including:

- Skip lesions – sharply delineated ulcerations surrounded by normal bowel
- "**Cobblestone**" appearance – serpiginous (ie, wavy, snakelike) depressed ulcerations that separate elevated islands of healthy tissue (giving the mucosa an appearance of a cobblestone street)
- **Bowel wall thickening** – due to inflammation involving all layers of the bowel wall leading to edema, hypertrophy of the muscularis mucosa,

leads to recognizable manifestations on gross pathology, including:

- Skip lesions – sharply delineated ulcerations surrounded by normal bowel
- "**Cobblestone**" appearance – serpiginous (ie, wavy, snakelike) depressed ulcerations that separate elevated islands of healthy tissue (giving the mucosa an appearance of a cobblestone street)
- **Bowel wall thickening** – due to inflammation involving all layers of the bowel wall leading to edema, hypertrophy of the muscularis mucosa, and fibrosis
- **Creeping fat** – mesenteric fat becomes wrapped around the bowel, possibly in response to intestinal bacteria translocation

In addition, the transmural inflammation frequently leads to complications such as abscesses, strictures, and fistulas.

(Choice A) Amoebic dysentery caused by *Entamoeba histolytica* causes hematochezia, abdominal pain, and ulcerations; however, the ulcers are classically flask-shaped and smaller than those seen with inflammatory bowel disease.

(Choice B) Collagenous colitis can cause chronic watery diarrhea (>5-10 episodes daily) but is commonly seen in middle-aged women and is not associated with bleeding, ulcerations, inflammation, or abdominal pain.

(Choice D) Graft-versus-host disease of the GI tract can cause abdominal pain and ulcerations, but it typically causes severe diarrhea (up to 10 L daily) and occurs as a complication of allogeneic stem cell transplant.

(Choice E) Pseudomembranous colitis occurs from *Clostridium difficile* infection (CDI). It causes abdominal pain and diarrhea that can result in toxic megacolon. A white/yellow, patchy pseudomembrane, composed of inflammatory cells, fibrin, and cellular debris, is often visualized. In addition, CDI is typically associated with recent antibiotic use.

(Choice F) Ulcerative colitis is characterized by contiguous inflammation that extends from the rectum. Ulcerations are shallow and involve only the mucosa and submucosa; pseudopolyps (areas of granulation tissue that appear polyp-like due to surrounding ulcerations) are seen; bowel wall thickening is not as prominent as with CD.

Educational objective:
Crohn disease is an inflammatory bowel disease characterized by patchy inflammation that can occur throughout the entire gastrointestinal tract. Gross pathology demonstrates skip lesions, cobblestoning of the mucosa, bowel wall thickening, and creeping fat.

Settings

1 2 3 4 5 6 7 8 9 10 11 12 13 14 15 16 17 18 19 20 21 22 23 24 25 26 27 28 29 30

Item 5 of 40
Question Id: 407

Mark | Previous | Next | Full Screen | Tutorial | Lab Values | Notes | Calculator | Reverse Color | Text Zoom | Settings

leads to recognizable manifestations on gross pathology, including:

Exhibit Display

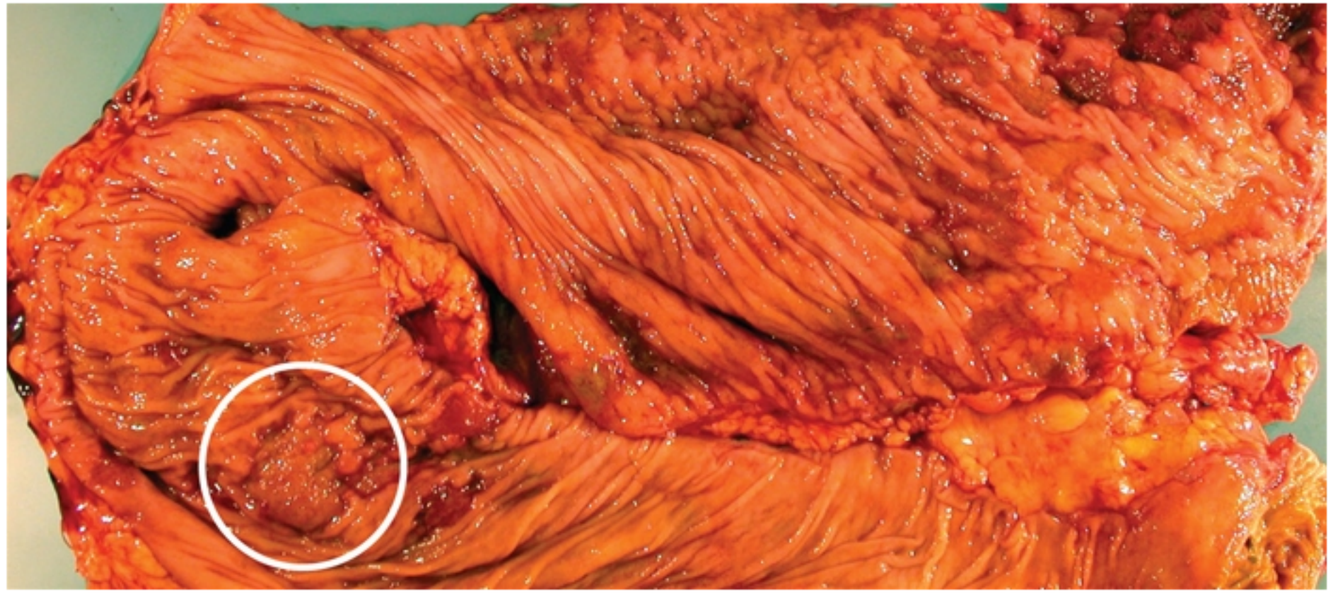

Zoom In | Zoom Out | Reset | Add To New Card | Existing Card

Gross pathology demonstrates skin lesions, cobblestoning of the mucosa, bowel wall thickening, and creeping fat

Block Time Remaining: 00:00:14
TUTOR

5 | Feedback | Suspend | End Block

leads to recognizable manifestations on gross pathology, including:

Exhibit Display

Pseudomembranous colitis

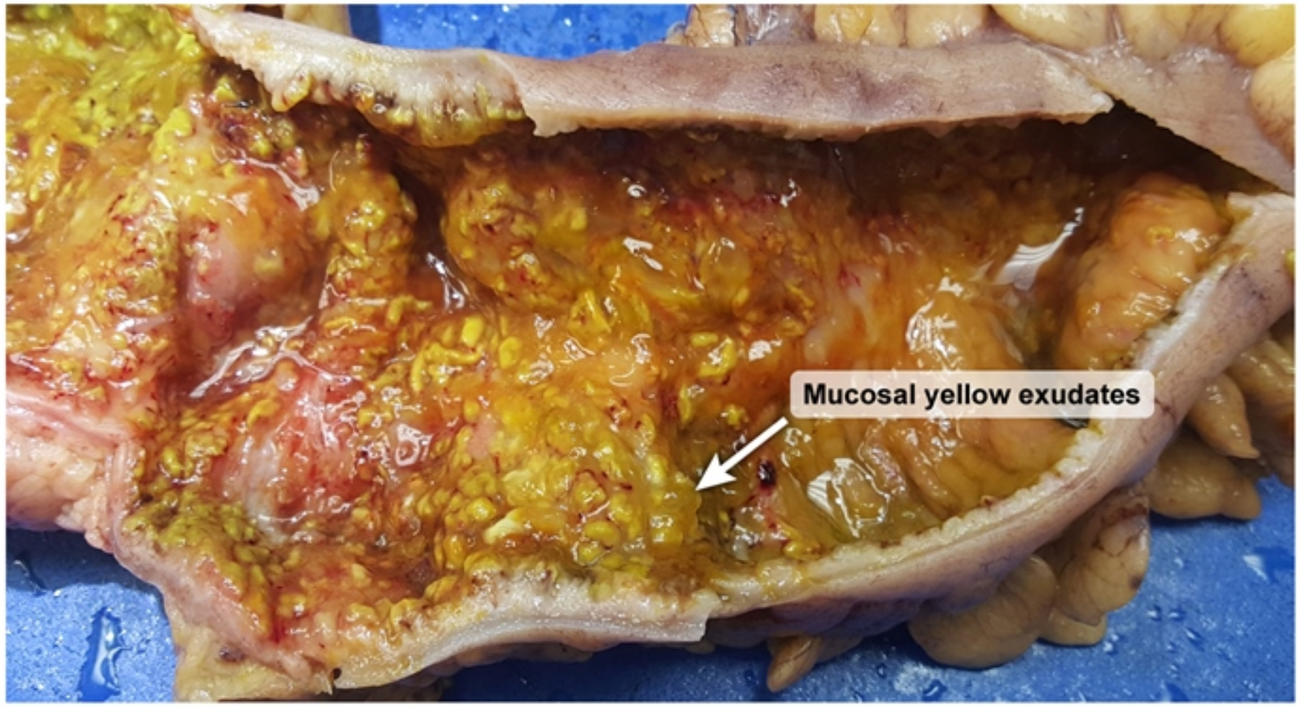

©UWorld

Zoom In Zoom Out Reset Add To New Card | Existing Card

Gross pathology demonstrates skin lesions, cobblestoning of the mucosa, bowel wall thickening, and creeping fat.

leads to recognizable manifestations on gross pathology, including:

Exhibit Display

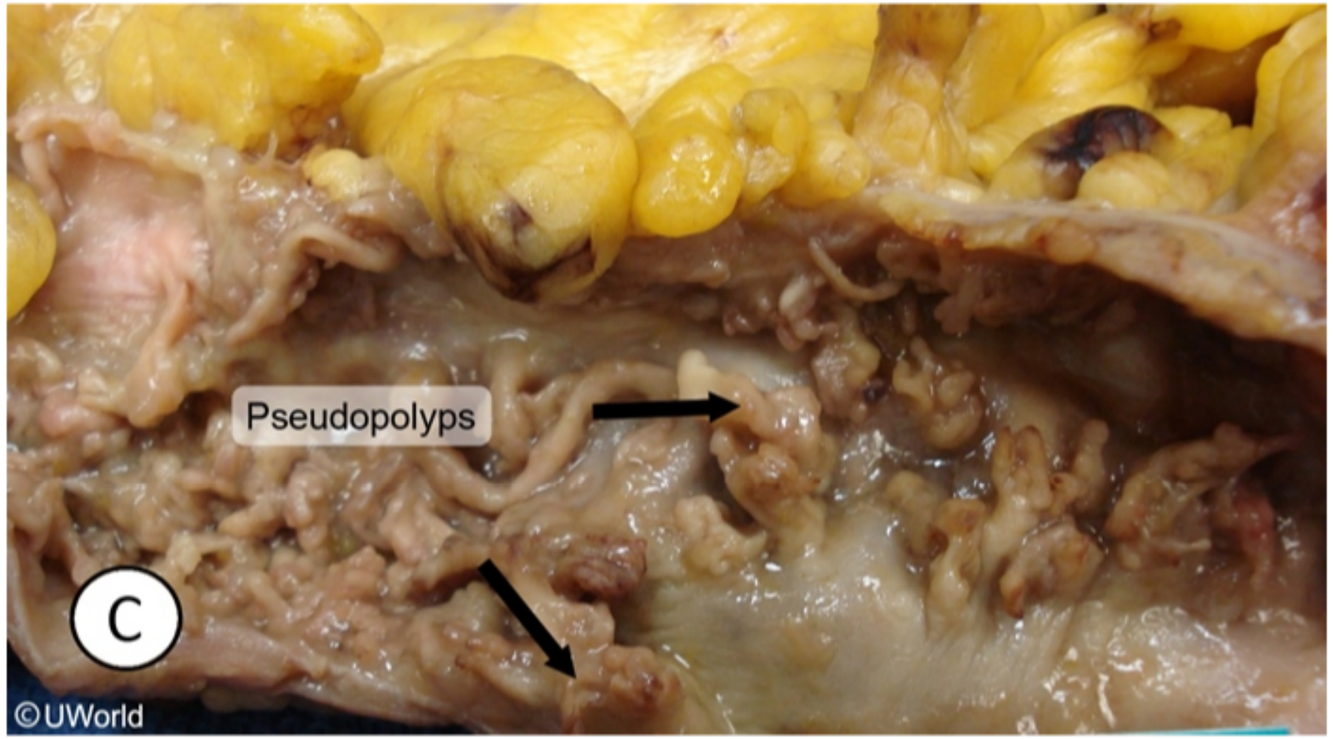

Zoom In Zoom Out Reset Add To New Card | Existing Card

Cross pathology demonstrates skin lesions, cobblestoning of the mucosa, bowel wall thickening, and creeping fat.

and fibrosis

- **Creeping fat** – mesenteric fat becomes wrapped around the bowel, possibly in response to intestinal bacteria translocation

In addition, the transmural inflammation frequently leads to complications such as abscesses, strictures, and fistulas.

(Choice A) Amoebic dysentery caused by *Entamoeba histolytica* causes hematochezia, abdominal pain, and ulcerations; however, the ulcers are classically flask-shaped and smaller than those seen with inflammatory bowel disease.

(Choice B) Collagenous colitis can cause chronic watery diarrhea (>5-10 episodes daily) but is commonly seen in middle-aged women and is not associated with bleeding, ulcerations, inflammation, or abdominal pain.

(Choice D) Graft-versus-host disease of the GI tract can cause abdominal pain and ulcerations, but it typically causes severe diarrhea (up to 10 L daily) and occurs as a complication of allogeneic stem cell transplant.

(Choice E) Pseudomembranous colitis occurs from *Clostridium difficile* infection (CDI). It causes abdominal pain and diarrhea that can result in toxic megacolon. A white/yellow, patchy pseudomembrane, composed of inflammatory cells, fibrin, and cellular debris, is often visualized. In addition, CDI is typically associated with recent antibiotic use.

(Choice F) Ulcerative colitis is characterized by contiguous inflammation that extends from the rectum. Ulcerations are shallow and involve only the mucosa and submucosa; pseudopolyps (areas of granulation tissue that appear polyp-like due to surrounding ulcerations) are seen; bowel wall thickening is not as prominent as with CD.

Educational objective:
Crohn disease is an inflammatory bowel disease characterized by patchy inflammation that can occur throughout the entire gastrointestinal tract. Gross pathology demonstrates skip lesions, cobblestoning of the mucosa, bowel wall thickening, and creeping fat.

Pathology	Gastrointestinal & Nutrition	Inflammatory bowel disease
Subject	System	Topic

Copyright © UWorld. All rights reserved.

A 46-year-old Caucasian male who presented with abdominal pain is diagnosed with a rare vascular tumor. This type of tumor is oftentimes associated with past arsenic or polyvinyl chloride exposure. Immunohistochemical staining of the tumor cells is positive for the CD 31 cell marker. The patient most likely has which of the following conditions?

- A. Cavernous hemangioma
- B. Pyogenic granuloma
- C. Cystic hygroma
- D. Port-wine stain
- E. Kaposi's sarcoma
- F. Lymphangiosarcoma
- G. Liver angiosarcoma
- H. Vascular ectasia
- I. Glomus tumor

Submit

A 46-year-old Caucasian male who presented with abdominal pain is diagnosed with a rare vascular tumor. This type of tumor is oftentimes associated with past arsenic or polyvinyl chloride exposure. Immunohistochemical staining of the tumor cells is positive for the CD 31 cell marker. The patient most likely has which of the following conditions?

- A. Cavernous hemangioma (4%)
- B. Pyogenic granuloma (1%)
- C. Cystic hygroma (1%)
- D. Port-wine stain (2%)
- E. Kaposi's sarcoma (2%)
- F. Lymphangiosarcoma (8%)
- ✓ G. Liver angiosarcoma (76%)
- H. Vascular ectasia (1%)
- I. Glomus tumor (2%)

Omitted
Correct answer
G

76%
Answered correctly

02 secs
Time Spent

02/03/2020
Last Updated

Explanation

H. Vascular ectasia (1%)

I. Glomus tumor (2%)

Omitted
Correct answer
G

76%
Answered correctly

02 secs
Time Spent

02/03/2020
Last Updated

Explanation

This patient has a carcinogen-related neoplasm composed of cells that express CD 31, which is PECAM1 (platelet endothelial cell adhesion molecule). PECAM1, a member of the immunoglobulin family of proteins, is expressed on the surface of endothelial cells and functions in leukocyte migration through the endothelium. The patient's tumor thus appears to have arisen from vascular endothelial cells. The most likely diagnosis is liver angiosarcoma, a rare malignant vascular endothelial cell neoplasm that is associated with carcinogen exposure. Implicated chemicals include arsenic (exposure to pesticides), thorotrast (a former radioactive contrast medium), and polyvinyl chloride (a plastic widely used in industry).

Educational Objective:
Hepatic angiosarcoma is associated with exposure to carcinogens such as arsenic, thorotrast, and polyvinyl chloride. Tumor cells express CD 31, an endothelial cell marker.

Pathology	Gastrointestinal & Nutrition	Hepatocellular cancer
Subject	System	Topic

Copyright © UWorld. All rights reserved.

A 45-year-old man comes to the office due to several months of diarrhea. The patient experiences watery diarrhea shortly after eating, occasional abdominal discomfort, easy fatigability, and unintentional weight loss. He has a history of Crohn disease for which he takes mesalamine. The patient also takes prednisone intermittently for disease exacerbations, and 6 months ago he was treated with metronidazole for a perianal abscess. Surgical history includes several intestinal resections due to complications of Crohn disease. He does not use tobacco or illicit drugs but drinks alcohol occasionally. Physical examination shows conjunctival pallor. The abdomen is nondistended, soft, and nontender. Vibratory and position sense are decreased in the lower extremities. Stool guaiac test is negative. Laboratory studies show macrocytic anemia and a low vitamin B_{12} level. Which of the following is the most likely cause of this patient's presenting symptoms?

- A. Hormone-induced luminal secretion
- B. Infection with a protozoan parasite
- C. Infection with gram-positive, PAS-positive bacilli
- D. Loss of intestinal absorptive area
- E. Medication adverse effect
- F. Pancreatic enzyme deficiency
- G. Postprandial rapid fluid shifts

Submit

A 45-year-old man comes to the office due to several months of diarrhea. The patient experiences watery diarrhea shortly after eating, occasional abdominal discomfort, easy fatigability, and unintentional weight loss. He has a history of Crohn disease for which he takes mesalamine. The patient also takes prednisone intermittently for disease exacerbations, and 6 months ago he was treated with metronidazole for a perianal abscess. Surgical history includes several intestinal resections due to complications of Crohn disease. He does not use tobacco or illicit drugs but drinks alcohol occasionally. Physical examination shows conjunctival pallor. The abdomen is nondistended, soft, and nontender. Vibratory and position sense are decreased in the lower extremities. Stool guaiac test is negative. Laboratory studies show macrocytic anemia and a low vitamin B_{12} level. Which of the following is the most likely cause of this patient's presenting symptoms?

- A. Hormone-induced luminal secretion (0%)
- B. Infection with a protozoan parasite (2%)
- C. Infection with gram-positive, PAS-positive bacilli (2%)
- ✓ D. Loss of intestinal absorptive area (87%)
- E. Medication adverse effect (2%)
- F. Pancreatic enzyme deficiency (2%)
- G. Postprandial rapid fluid shifts (1%)

Omitted
Correct answer
D

87%
Answered correctly

02 secs
Time Spent

05/24/2020
Last Updated

Explanation

This patient likely has **short bowel syndrome**, a malabsorptive condition that typically occurs in patients with massive **small bowel resection** and/or **Crohn disease**. Extensive intestinal disease or resection results in loss of absorptive surface area and a decrease in intestinal transit time, leading to postprandial voluminous diarrhea and weight loss due to **malabsorption** of macro- and micronutrients.

Loss of functional distal ileum may specifically result in **vitamin B_{12} deficiency** with macrocytic anemia, peripheral neuropathy, and subacute combined degeneration of the spinal cord (eg, impaired vibration and position sense).

(Choice A) VIPoma is a pancreatic neuroendocrine tumor that secretes vasoactive intestinal polypeptide, resulting in secretory watery diarrhea (persists with fasting) and flushing. Malabsorption of macro- and micronutrients is not characteristic.

(Choice B) Giardia is a protozoan parasite that may cause chronic diarrhea and malabsorption; however, infection typically occurs in high-risk individuals such infants, campers/hikers drinking from mountain streams, those who are immunocompromised, and travelers to resource-limited areas.

(Choice C) Whipple disease is a rare multisystemic disorder caused by *Tropheryma whipplei*, a gram-positive, periodic acid-Schiff (PAS)-positive bacilli. Patients typically present with migratory polyarthritis followed by abdominal pain and malabsorptive diarrhea. Neurologic symptoms (eg, cognitive dysfunction, myoclonus) and cardiac disease (eg, endocarditis) are also characteristic.

(Choice E) Numerous medications can cause diarrhea as an adverse effect; however, this is unlikely in this patient with malabsorption, vitamin B_{12} deficiency, and weight loss in the setting of Crohn disease and intestinal resection.

(Choice F) Chronic pancreatitis is most commonly caused by alcohol abuse and typically presents with abdominal pain and pancreatic insufficiency. Patients often have chronic diarrhea/malabsorption due to lack of digestive enzymes (exocrine insufficiency) and diabetes mellitus due to endocrine insufficiency.

(Choice G) Dumping syndrome may occur after gastric bypass surgery or damage to the pyloric sphincter. Emptying of hyperosmolar chyme into the small intestine causes a rapid shift of fluid from the serum to the intestine, resulting in postprandial gastrointestinal (eg, nausea/vomiting, cramps, diarrhea) and vasomotor symptoms (eg, diaphoresis, flushing).

Educational objective:

bacilli. Patients typically present with migratory polyarthritis followed by abdominal pain and malabsorptive diarrhea. Neurologic symptoms (eg, cognitive dysfunction, myoclonus) and cardiac disease (eg, endocarditis) are also characteristic.

(Choice E) Numerous medications can cause diarrhea as an adverse effect; however, this is unlikely in this patient with malabsorption, vitamin B_{12} deficiency, and weight loss in the setting of Crohn disease and intestinal resection.

(Choice F) Chronic pancreatitis is most commonly caused by alcohol abuse and typically presents with abdominal pain and pancreatic insufficiency. Patients often have chronic diarrhea/malabsorption due to lack of digestive enzymes (exocrine insufficiency) and diabetes mellitus due to endocrine insufficiency.

(Choice G) Dumping syndrome may occur after gastric bypass surgery or damage to the pyloric sphincter. Emptying of hyperosmolar chyme into the small intestine causes a rapid shift of fluid from the serum to the intestine, resulting in postprandial gastrointestinal (eg, nausea/vomiting, cramps, diarrhea) and vasomotor symptoms (eg, diaphoresis, flushing).

Educational objective:
Short bowel syndrome typically occurs in patients with massive small bowel resection and/or Crohn disease due to loss of intestinal absorptive surface area and a decrease in intestinal transit time. Patients usually present with postprandial voluminous diarrhea and weight loss due to malabsorption. Loss of functional distal ileum may result in vitamin B_{12} deficiency.

References

- Short bowel syndrome: a review of management options.
- The pathophysiology of malabsorption.
- Short bowel syndrome and malabsorption - causes and prevention.

Pathology	Gastrointestinal & Nutrition	Short Bowel Syndrome
Subject	System	Topic

Copyright © UWorld. All rights reserved.

A 38-year-old woman comes to the office due to jaundice, nausea, and abdominal discomfort. Vital signs are within normal limits. Scleral icterus and hepatomegaly are present. Laboratory results are as follows:

Liver function studies

Total bilirubin	4.7 mg/dL
Alkaline phosphatase	110 U/L
Aspartate aminotransferase (SGOT)	791 U/L
Alanine aminotransferase (SGPT)	634 U/L

Anti–smooth muscle antibody titers are elevated. Which of the following histologic findings is most likely to be seen on biopsy of this patient's liver?

A. Ground-glass hepatocytes with central ballooning degeneration
B. Hepatic steatosis and ballooning degeneration
C. Hepatocyte necrosis with portal infiltration of neutrophils
D. Periductal fibrosis and luminal obliteration of biliary ducts
E. Portal and periportal lymphoplasmacytic cell infiltration

Submit

A 38-year-old woman comes to the office due to jaundice, nausea, and abdominal discomfort. Vital signs are within normal limits. Scleral icterus and hepatomegaly are present. Laboratory results are as follows:

Liver function studies

Total bilirubin	4.7 mg/dL
Alkaline phosphatase	110 U/L
Aspartate aminotransferase (SGOT)	791 U/L
Alanine aminotransferase (SGPT)	634 U/L

Anti–smooth muscle antibody titers are elevated. Which of the following histologic findings is most likely to be seen on biopsy of this patient's liver?

A. Ground-glass hepatocytes with central ballooning degeneration (5%)
B. Hepatic steatosis and ballooning degeneration (6%)
C. Hepatocyte necrosis with portal infiltration of neutrophils (9%)
D. Periductal fibrosis and luminal obliteration of biliary ducts (35%)
✓ E. Portal and periportal lymphoplasmacytic cell infiltration (41%)

Omitted
Correct answer
E

41%
Answered correctly

02 secs
Time Spent

03/23/2020
Last Updated

This patient with jaundice, hepatomegaly, elevated transaminases, and high anti–smooth muscle antibody titers most likely has **autoimmune hepatitis** (AIH). AIH occurs most commonly in women with other autoimmune conditions (eg, type 1 diabetes mellitus). It is often asymptomatic but may present with fatigue, weight loss, nausea, and/or signs of acute hepatitis (eg, jaundice, abdominal discomfort). Characteristic laboratory abnormalities include a **hepatocellular pattern** of liver injury (ie, predominant transaminase elevation with normal alkaline phosphatase and variable bilirubin) and the formation of a variety of autoantibodies, particularly **anti–smooth muscle**, which is highly specific for AIH. Hypergammaglobulinemia is also typical.

The pathogenesis of AIH is incompletely understood but likely involves exposure to an environmental trigger in genetically predisposed patients, leading to regulatory T-cell dysfunction. It ultimately results in loss of self-tolerance, with an **immune response against hepatic antigens**. This is demonstrated histologically by **lymphocyte and plasma cell** infiltration of **portal and periportal** regions of the liver.

(Choice A) Chronic hepatitis B is characterized histologically by ground-glass hepatocytes, which result from the accumulation of hepatitis B surface antigen within their cytoplasm, as well as central balloon degeneration, which reflects hepatocytes undergoing apoptosis.

(Choice B) Hepatic steatosis (ie, lipid accumulation in the cytoplasm of hepatocytes) and ballooning degeneration most commonly occur in alcoholic hepatitis and nonalcoholic fatty liver disease. Elevated anti–smooth muscle antibody titers do not occur.

(Choice C) Acetaminophen overdose can lead to hepatic inflammation and necrosis with neutrophilic infiltration (unlike AIH, which is characterized by lymphoplasmocytic infiltrates). Patients often have vomiting, diaphoresis, and confusion.

(Choice D) Primary sclerosing cholangitis causes periductal fibrosis and luminal obliteration of the biliary ducts, which can lead to cholestasis. High alkaline phosphatase levels and near-normal aminotransferases are expected.

Educational objective:
Autoimmune hepatitis results from an immune response against hepatic antigens, leading to a lymphoplasmacytic infiltrate in the portal and periportal regions of the liver. Manifestations include fatigue, weight loss, nausea, and/or signs of acute hepatitis (eg, jaundice, abdominal discomfort). Characteristic laboratory abnormalities include a hepatocellular pattern of liver injury, anti–smooth muscle autoantibodies, and hypergammaglobulinemia.

Pathology Gastrointestinal & Nutrition Autoimmune hepatitis

abnormalities include a **hepatocellular pattern** of liver injury (ie, predominant transaminase elevation with normal alkaline phosphatase and variable bilirubin) and the formation of a variety of autoantibodies, particularly **anti–smooth muscle**, which is highly specific for AIH. Hypergammaglobulinemia is also typical.

The pathogenesis of AIH is incompletely understood but likely involves exposure to an environmental trigger in genetically predisposed patients, leading to regulatory T-cell dysfunction. It ultimately results in loss of self-tolerance, with an **immune response against hepatic antigens**. This is demonstrated histologically by **lymphocyte and plasma cell** infiltration of **portal and periportal** regions of the liver.

(Choice A) Chronic hepatitis B is characterized histologically by ground-glass hepatocytes, which result from the accumulation of hepatitis B surface antigen within their cytoplasm, as well as central balloon degeneration, which reflects hepatocytes undergoing apoptosis.

(Choice B) Hepatic steatosis (ie, lipid accumulation in the cytoplasm of hepatocytes) and ballooning degeneration most commonly occur in alcoholic hepatitis and nonalcoholic fatty liver disease. Elevated anti–smooth muscle antibody titers do not occur.

(Choice C) Acetaminophen overdose can lead to hepatic inflammation and necrosis with neutrophilic infiltration (unlike AIH, which is characterized by lymphoplasmocytic infiltrates). Patients often have vomiting, diaphoresis, and confusion.

(Choice D) Primary sclerosing cholangitis causes periductal fibrosis and luminal obliteration of the biliary ducts, which can lead to cholestasis. High alkaline phosphatase levels and near-normal aminotransferases are expected.

Educational objective:
Autoimmune hepatitis results from an immune response against hepatic antigens, leading to a lymphoplasmacytic infiltrate in the portal and periportal regions of the liver. Manifestations include fatigue, weight loss, nausea, and/or signs of acute hepatitis (eg, jaundice, abdominal discomfort). Characteristic laboratory abnormalities include a hepatocellular pattern of liver injury, anti–smooth muscle autoantibodies, and hypergammaglobulinemia.

Pathology	Gastrointestinal & Nutrition	Autoimmune hepatitis
Subject	System	Topic

Copyright © UWorld. All rights reserved.

A 54-year-old man comes to the office with abdominal pain, chronic diarrhea, and recent weight loss. He has had episodic abdominal pain in the past, but lately it has become persistent and worsens after eating. The patient does not use tobacco or illicit drugs but does consume alcohol regularly. An upright abdominal x-ray reveals calcifications in the epigastric area. Which of the following is the most likely cause of his diarrhea?

- A. Bile salt malabsorption
- B. Digestive enzyme deficiency
- C. Elevated portal venous pressure
- D. Excessive gastrin production
- E. Immune-mediated enteropathy
- F. Nutrient absorption interference by alcohol

Submit

A 54-year-old man comes to the office with abdominal pain, chronic diarrhea, and recent weight loss. He has had episodic abdominal pain in the past, but lately it has become persistent and worsens after eating. The patient does not use tobacco or illicit drugs but does consume alcohol regularly. An upright abdominal x-ray reveals calcifications in the epigastric area. Which of the following is the most likely cause of his diarrhea?

- A. Bile salt malabsorption (11%)
- ✓ B. Digestive enzyme deficiency (70%)
- C. Elevated portal venous pressure (1%)
- D. Excessive gastrin production (8%)
- E. Immune-mediated enteropathy (2%)
- F. Nutrient absorption interference by alcohol (4%)

Omitted
Correct answer
B

70%
Answered correctly

01 sec
Time Spent

02/03/2020
Last Updated

Explanation

Pathogenesis of chronic alcoholic pancreatitis

Normal | **Chronic alcoholism**

Pathogenesis of chronic alcoholic pancreatitis

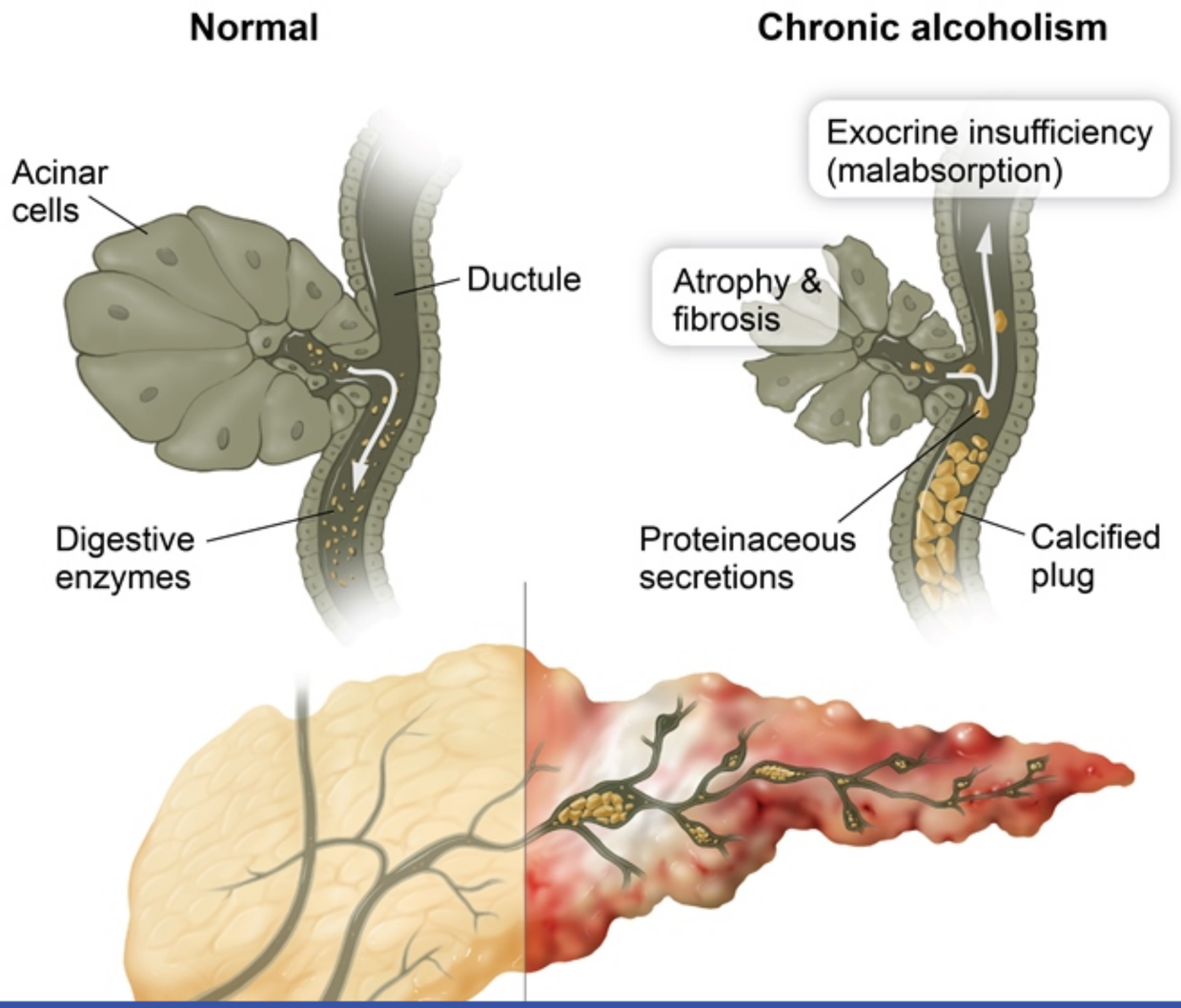

©UWorld

This patient's epigastric calcifications and history of alcohol use make **chronic alcoholic pancreatitis** the most likely diagnosis. It is thought that alcohol-related chronic pancreatitis develops in part due to alcohol-induced secretion of protein-rich fluid. These proteinaceous secretions can precipitate within the pancreatic ducts, forming **ductal plugs** that may **calcify** and be detectable on abdominal imaging.

Ductal obstruction by such concretions may cause **exocrine insufficiency** due to atrophy of the pancreatic acinar cells and pancreatic fibrosis. Pancreatic exocrine insufficiency (eg, failure to secrete adequate amylases, proteases, and lipases) leads to **malabsorption** with consequent **diarrhea/steatorrhea**. **Weight loss** and bulky, frothy stools are typical clinical findings. This patient's abdominal pain is most likely due to the pancreatitis itself.

(Choice A) Bile salt malabsorption typically occurs with conditions affecting the terminal ileum (eg, ileal resection, Crohn ileitis). Patients may have diarrhea as a result of excessive bile salt accumulation in the colon (cholerheic enteropathy).

(Choice C) Portal hypertension (eg, due to liver cirrhosis) causes varices at sites of portocaval anastomoses, leading to anorectal varices, caput medusae over the abdomen, and esophageal varices. Bleeding esophageal varices can cause hematemesis and melena. Ascites is another sign of portal hypertension.

(Choice D) Gastrinomas (duodenal/pancreatic gastrin-secreting neuroendocrine tumors) cause hydrochloric acid hypersecretion, which can result in multiple and/or refractory peptic ulcers. Patients may also have diarrhea/malabsorption as digestive enzymes become deactivated by high gastric acid output.

(Choice E) Celiac disease classically presents with malabsorption due to immune-mediated enteropathy involving the proximal small intestine. This condition is triggered by the ingestion of foods containing gluten (eg, wheat).

(Choice F) Chronic alcohol use may result in the interference of nutrient/vitamin absorption due to intestinal mucosal injury. However, this patient's abdominal pain and epigastric calcifications suggest that his diarrhea is most likely a consequence of chronic pancreatitis.

Educational objective:
Diarrhea, weight loss, and epigastric calcifications in a patient with chronic alcoholism suggest chronic pancreatitis with resulting pancreatic exocrine insufficiency and malabsorption.

References

(Choice A) Bile salt malabsorption typically occurs with conditions affecting the terminal ileum (eg, ileal resection, Crohn ileitis). Patients may have diarrhea as a result of excessive bile salt accumulation in the colon (cholerheic enteropathy).

(Choice C) Portal hypertension (eg, due to liver cirrhosis) causes varices at sites of portocaval anastomoses, leading to anorectal varices, caput medusae over the abdomen, and esophageal varices. Bleeding esophageal varices can cause hematemesis and melena. Ascites is another sign of portal hypertension.

(Choice D) Gastrinomas (duodenal/pancreatic gastrin-secreting neuroendocrine tumors) cause hydrochloric acid hypersecretion, which can result in multiple and/or refractory peptic ulcers. Patients may also have diarrhea/malabsorption as digestive enzymes become deactivated by high gastric acid output.

(Choice E) Celiac disease classically presents with malabsorption due to immune-mediated enteropathy involving the proximal small intestine. This condition is triggered by the ingestion of foods containing gluten (eg, wheat).

(Choice F) Chronic alcohol use may result in the interference of nutrient/vitamin absorption due to intestinal mucosal injury. However, this patient's abdominal pain and epigastric calcifications suggest that his diarrhea is most likely a consequence of chronic pancreatitis.

Educational objective:
Diarrhea, weight loss, and epigastric calcifications in a patient with chronic alcoholism suggest chronic pancreatitis with resulting pancreatic exocrine insufficiency and malabsorption.

References

- Evaluation of chronic diarrhea.
- Chronic pancreatitis.

Pathology	Gastrointestinal & Nutrition	Chronic pancreatitis
Subject	System	Topic

Copyright © UWorld. All rights reserved.

Exhibit Display

Chronic pancreatitis

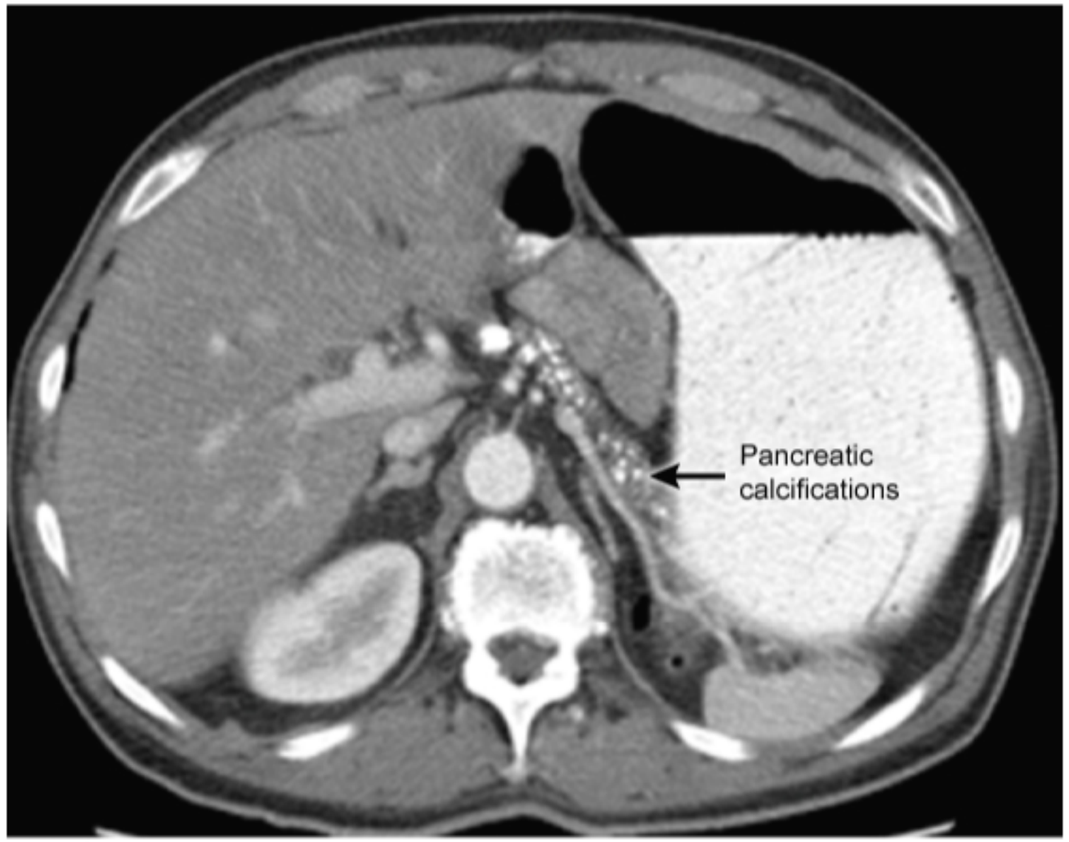

©UWorld

Zoom In | Zoom Out | Reset | Add To New Card | Existing Card

medusae over the abdomen, and esophageal varices. Bleeding esophageal varices can cause hematemesis and melena. Ascites is another sign

A 50-year-old woman comes to the office for a preventive examination. She feels well and has no ongoing symptoms. Medical and family histories are unremarkable. The patient does not use tobacco or alcohol. Blood pressure is 132/76 mm Hg and pulse is 72/min. BMI is 25 kg/m^2. Physical examination is normal. The patient is up to date on breast and cervical screening but has not undergone colon cancer screening. She is referred for colonoscopy, during which a single colon polyp is discovered. The polyp is removed and sent for histologic analysis. Which of the following pathologic findings is associated with the greatest risk of malignant transformation in this patient?

- A. 1-cm sessile hyperplastic polyp
- B. 2-cm sessile lymphoid polyp
- C. 2-cm tubular adenomatous polyp
- D. 2-cm villous adenomatous polyp
- E. 3-cm pedunculated hamartomatous polyp

Submit

A 50-year-old woman comes to the office for a preventive examination. She feels well and has no ongoing symptoms. Medical and family histories are unremarkable. The patient does not use tobacco or alcohol. Blood pressure is 132/76 mm Hg and pulse is 72/min. BMI is 25 kg/m^2. Physical examination is normal. The patient is up to date on breast and cervical screening but has not undergone colon cancer screening. She is referred for colonoscopy, during which a single colon polyp is discovered. The polyp is removed and sent for histologic analysis. Which of the following pathologic findings is associated with the greatest risk of malignant transformation in this patient?

A. 1-cm sessile hyperplastic polyp (5%)

B. 2-cm sessile lymphoid polyp (3%)

C. 2-cm tubular adenomatous polyp (3%)

✓ D. 2-cm villous adenomatous polyp (85%)

E. 3-cm pedunculated hamartomatous polyp (2%)

Omitted
Correct answer
D

85%
Answered correctly

02 secs
Time Spent

04/10/2020
Last Updated

Explanation

Common colonic polyps	
Neoplastic	**Non-neoplastic**
	• Hyperplastic

Common colonic polyps	
Neoplastic	**Non-neoplastic**
• Serrated • Adenomatous (villous > tubular)	• Hyperplastic • Inflammatory • Juvenile • Submucosal

Colonic polyps may be differentiated as non-neoplastic and neoplastic. Most are non-neoplastic and do not increase the risk of colon adenocarcinoma; such types include:

1. Hyperplastic polyps, the most common non-neoplastic polyp, are typically small and composed of well-differentiated mucosal cells that form glands and crypts **(Choice A)**.
2. Inflammatory polyps, seen in ulcerative colitis and Crohn disease, are composed of regenerating intestinal mucosa and inflammatory cells.
3. Submucosal polyps, are typically composed of lipomas or lymphoid aggregates that bulge up into the mucosa **(Choice B)**.

Neoplastic polyps include **adenomatous polyps** (ie, tubular, villous, tubulovillous) and serrated polyps (ie, sessile serrated polyp, traditional serrated adenoma). These polyps have the potential to transform into colonic adenocarcinoma. **Increasing polyp size** is the most important characteristic that **correlates with malignancy risk**; the risk is increased in polyps >10 mm and is greatest in those >4 cm. Other risk factors include degree of dysplasia and histologic pattern. Villous adenomas are more likely to undergo malignant transformation than tubular adenomas **(Choice C)**.

(Choice E) Hamartomatous polyps consist of disorganized mucosal glands, smooth muscle, and connective tissue. Sporadic juvenile polyps are solitary hamartomatous lesions that are not associated with increased risk of colon cancer. Multiple hamartomatous polyps frequently occur in Peutz-Jeghers and juvenile polyposis syndromes, both of which confer an increased risk of malignancy.

Educational objective:
Adenomatous and serrated polyps (ie, sessile serrated polyp, traditional serrated adenoma) are neoplastic polyps that have malignancy potential. Increasing polyp size is the most important risk factor for cancer; villous histology and high-grade dysplasia are additional risk factors.

• Adenomatous (villous > tubular)	• Juvenile • Submucosal

Colonic polyps may be differentiated as non-neoplastic and neoplastic. Most are non-neoplastic and do not increase the risk of colon adenocarcinoma; such types include:

1. Hyperplastic polyps, the most common non-neoplastic polyp, are typically small and composed of well-differentiated mucosal cells that form glands and crypts **(Choice A)**.
2. Inflammatory polyps, seen in ulcerative colitis and Crohn disease, are composed of regenerating intestinal mucosa and inflammatory cells.
3. Submucosal polyps, are typically composed of lipomas or lymphoid aggregates that bulge up into the mucosa **(Choice B)**.

Neoplastic polyps include **adenomatous polyps** (ie, tubular, villous, tubulovillous) and serrated polyps (ie, sessile serrated polyp, traditional serrated adenoma). These polyps have the potential to transform into colonic adenocarcinoma. **Increasing polyp size** is the most important characteristic that **correlates with malignancy risk**; the risk is increased in polyps >10 mm and is greatest in those >4 cm. Other risk factors include degree of dysplasia and histologic pattern. Villous adenomas are more likely to undergo malignant transformation than tubular adenomas **(Choice C)**.

(Choice E) Hamartomatous polyps consist of disorganized mucosal glands, smooth muscle, and connective tissue. Sporadic juvenile polyps are solitary hamartomatous lesions that are not associated with increased risk of colon cancer. Multiple hamartomatous polyps frequently occur in Peutz-Jeghers and juvenile polyposis syndromes, both of which confer an increased risk of malignancy.

Educational objective:
Adenomatous and serrated polyps (ie, sessile serrated polyp, traditional serrated adenoma) are neoplastic polyps that have malignancy potential. Increasing polyp size is the most important risk factor for cancer; villous histology and high-grade dysplasia are additional risk factors.

Pathology	Gastrointestinal & Nutrition	Colonic polyps
Subject	System	Topic

Copyright © UWorld. All rights reserved.

Settings

1 2 3 4 5 6 7 8 9 10 11 12 13 14 15 16 17 18 19 20 21 22 23 24 25 26 27 28 29 30

Item 10 of 40
Question Id: 427

Mark | Previous | Next | Full Screen | Tutorial | Lab Values | Notes | Calculator | Reverse Color | Text Zoom | Settings

- Adenomatous (villous > tubular)
- Juvenile

Exhibit Display

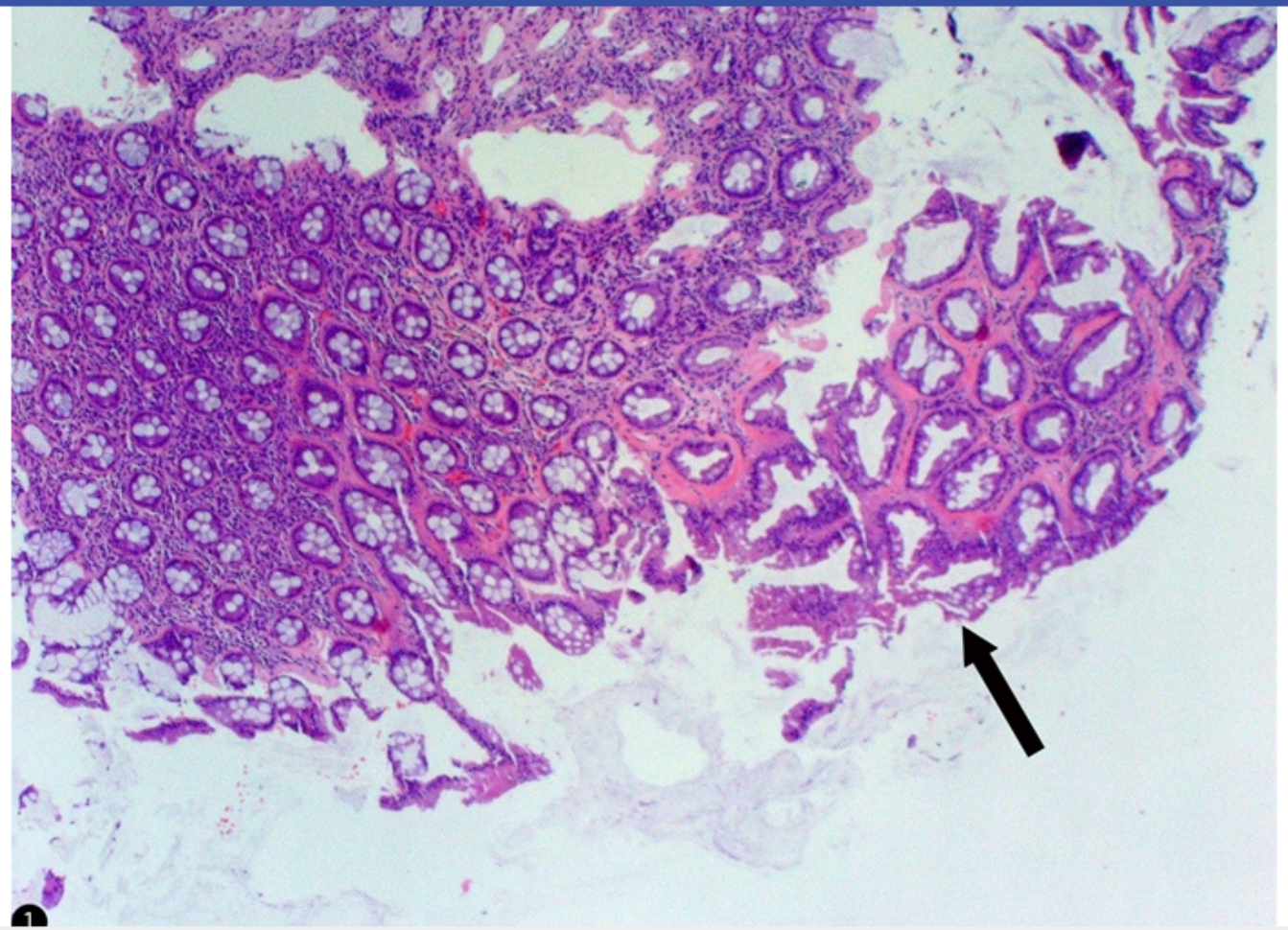

Zoom In | Zoom Out | Reset | Add To New Card | Existing Card

Block Time Remaining: 00:00:23
TUTOR

8 | Feedback | Suspend | End Block

Settings

1 2 3 4 5 6 7 8 9 10 11 12 13 14 15 16 17 18 19 20 21 22 23 24 25 26 27 28 29 30

Item 10 of 40
Question Id: 427

Mark | Previous | Next | Full Screen | Tutorial | Lab Values | Notes | Calculator | Reverse Color | Text Zoom | Settings

- Adenomatous (villous > tubular)
- Juvenile

Exhibit Display

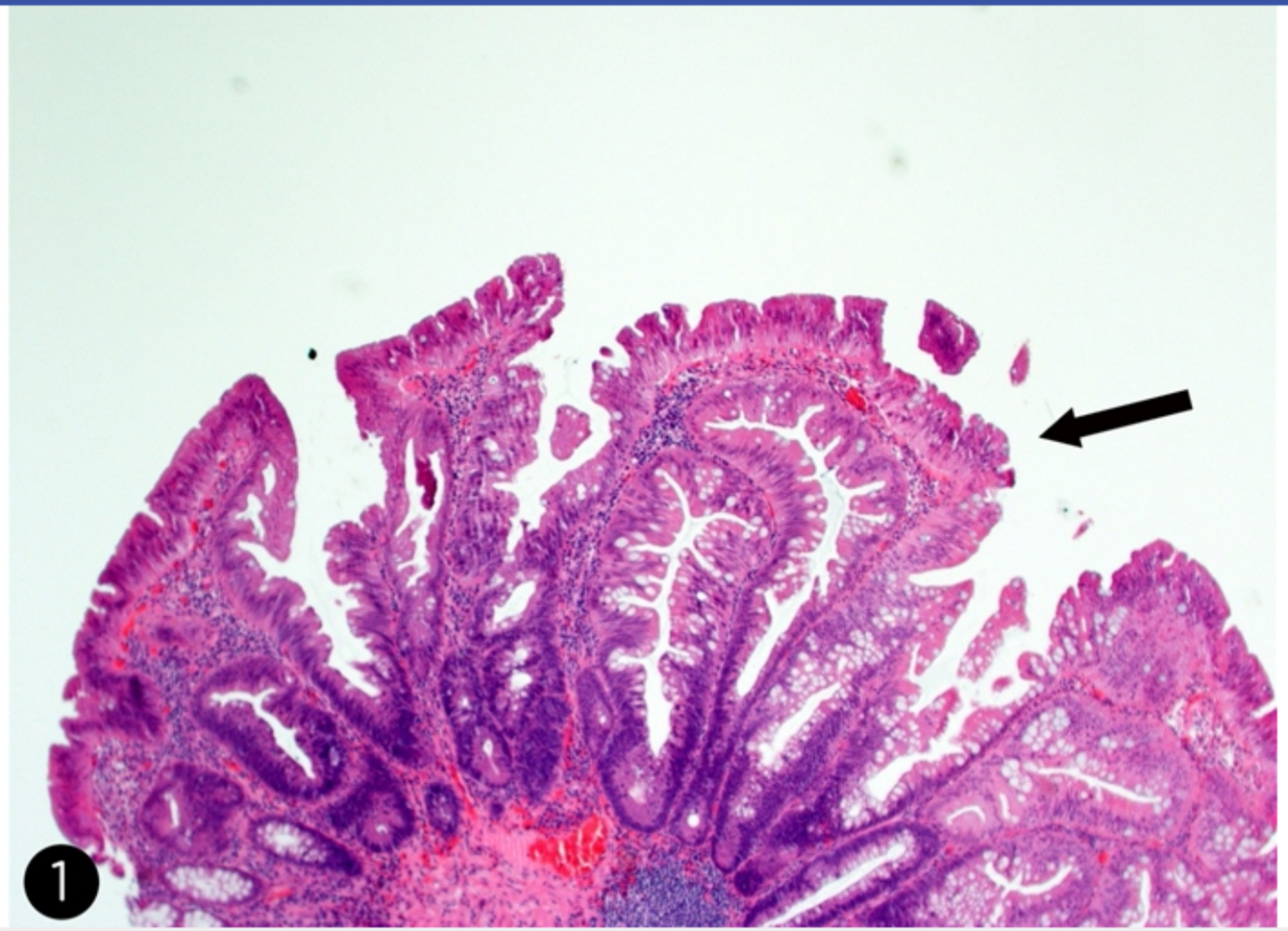

Zoom In | Zoom Out | Reset | Add To New Card | Existing Card

Block Time Remaining: 00:00:23
TUTOR

8 | Feedback | Suspend | End Block

Settings

1
2
3
4
5
6
7
8
9
10
11
12
13
14
15
16
17
18
19
20
21
22
23
24
25
26
27
28
29
30

Item 10 of 40
Question Id: 427

Mark | Previous | Next | Full Screen | Tutorial | Lab Values | Notes | Calculator | Reverse Color | Text Zoom | Settings

- Adenomatous (villous > tubular)
- Juvenile

Exhibit Display

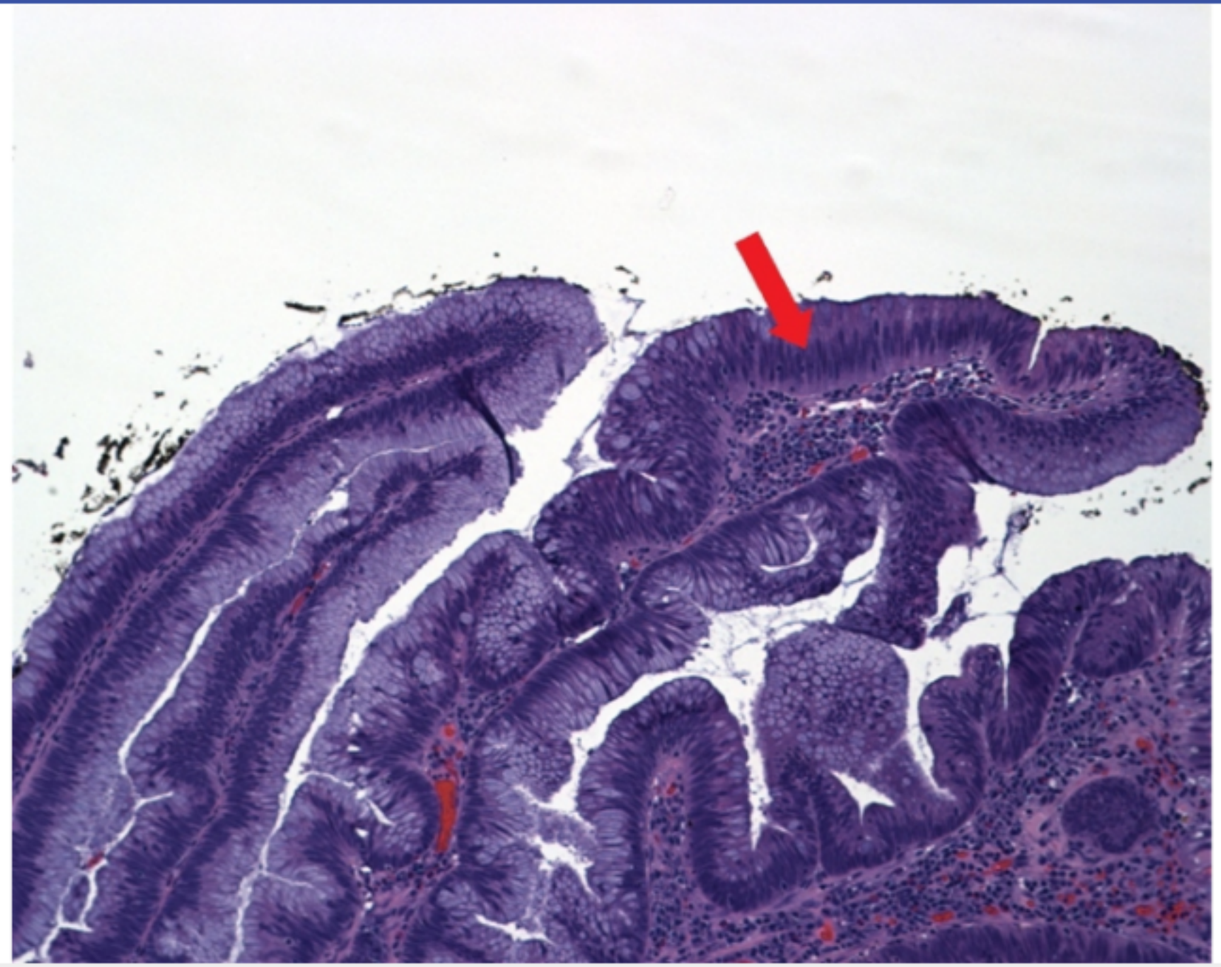

Zoom In | Zoom Out | Reset | Add To New Card | Existing Card

Block Time Remaining: 00:00:23
TUTOR

8 | Feedback | Suspend | End Block

Settings

1
2
3
4
5
6
7
8
9
10
11
12
13
14
15
16
17
18
19
20
21
22
23
24
25
26
27
28
29
30

Item 10 of 40
Question Id: 427

Mark | Previous | Next | Full Screen | Tutorial | Lab Values | Notes | Calculator | Reverse Color | Text Zoom | Settings

- Adenomatous (villous > tubular)
- Juvenile

Exhibit Display

Zoom In | Zoom Out | Reset | Add To New Card | Existing Card

Block Time Remaining: 00:00:23
TUTOR

8 | Feedback | Suspend | End Block

Settings

1 2 3 4 5 6 7 8 9 10 11 12 13 14 15 16 17 18 19 20 21 22 23 24 25 26 27 28 29 30

Item 10 of 40
Question Id: 427

Mark | Previous | Next | Full Screen | Tutorial | Lab Values | Notes | Calculator | Reverse Color | Text Zoom | Settings

- Adenomatous (villous > tubular)
- Juvenile

Exhibit Display

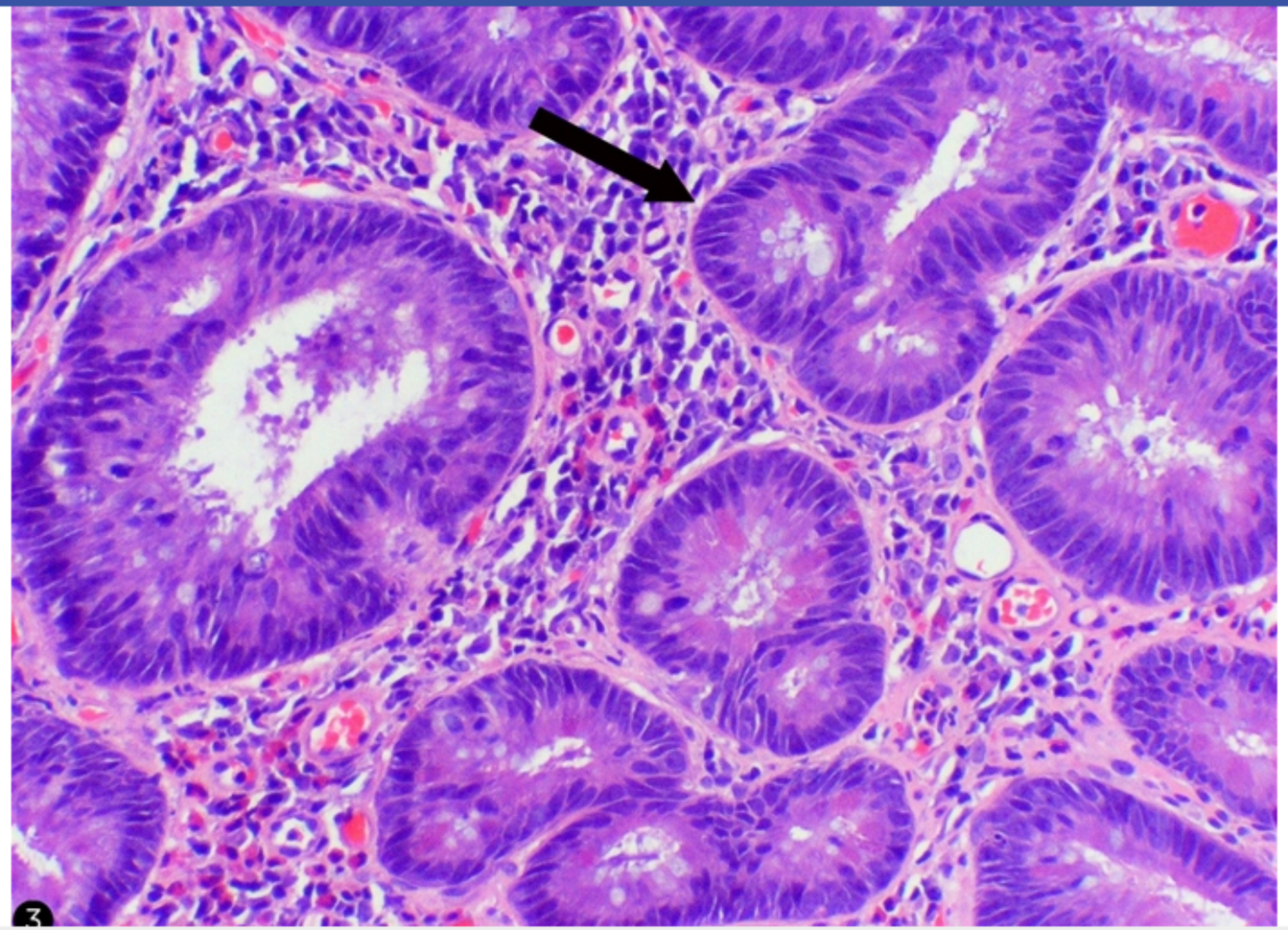

Zoom In | Zoom Out | Reset | Add To New Card | Existing Card

Block Time Remaining: 00:00:23
TUTOR

8 | Feedback | Suspend | End Block

Settings

1
2
3
4
5
6
7
8
9
10
11
12
13
14
15
16
17
18
19
20
21
22
23
24
25
26
27
28
29
30

Item 10 of 40
Question Id: 427

Mark | Previous | Next | Full Screen | Tutorial | Lab Values | Notes | Calculator | Reverse Color | Text Zoom | Settings

- Adenomatous (villous > tubular)
- Juvenile

Exhibit Display

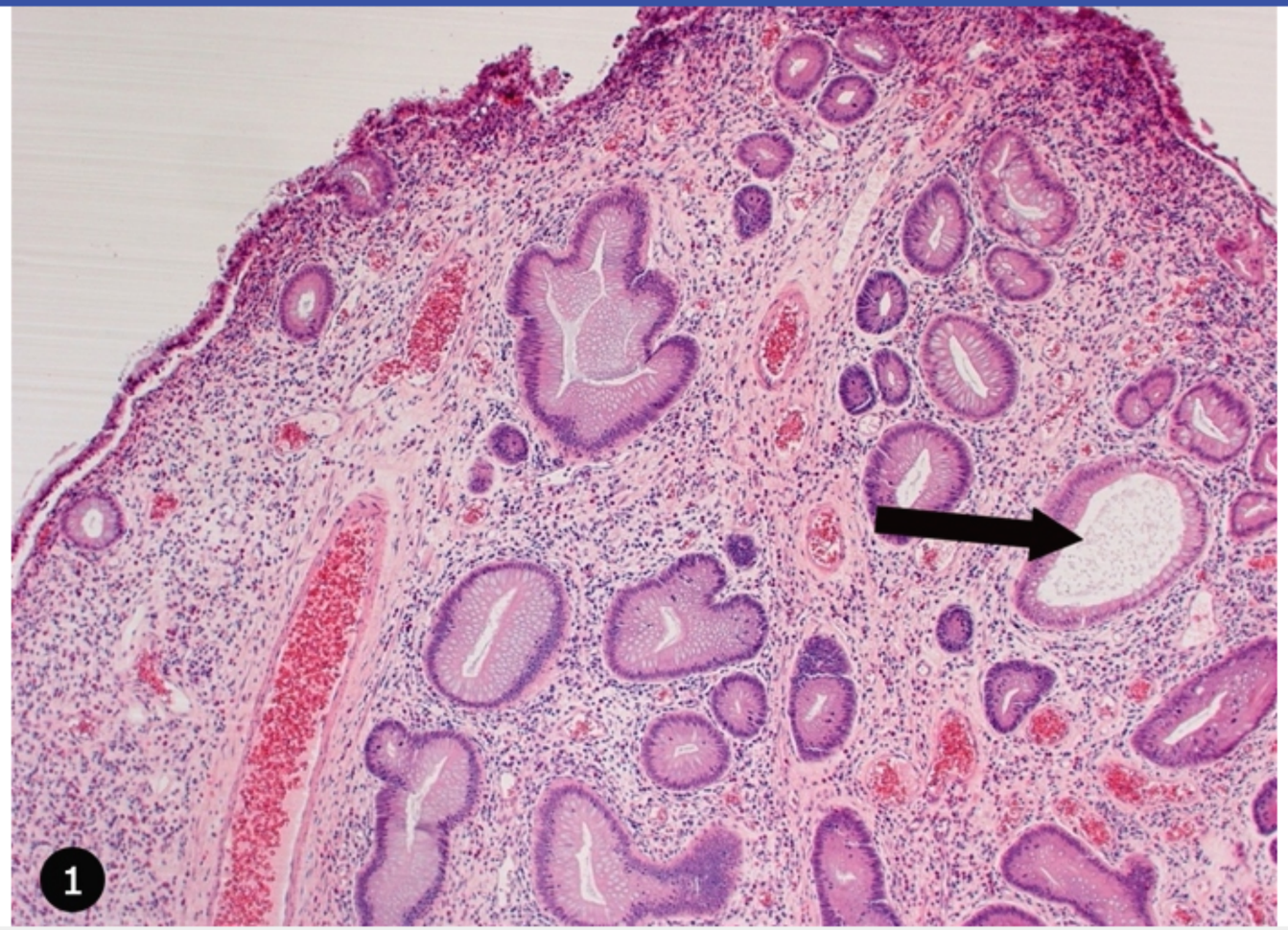

Zoom In | Zoom Out | Reset | Add To New Card | Existing Card

Block Time Remaining: 00:00:23
TUTOR

8 | Feedback | Suspend | End Block

A 53-year-old man comes to the physician with progressively worsening anorexia and abdominal discomfort. He has lost 14 kg (31 lb) since the onset of his symptoms about 4 months ago. Physical examination demonstrates nontender hepatomegaly. Laboratory studies show an elevated serum alkaline phosphatase level and a marginally elevated alanine aminotransferase level. A CT scan of the abdomen with oral and intravenous contrast is shown below.

Which of the following is the most likely diagnosis?

A. Hepatic adenoma

B. Hepatic angiosarcoma

Settings

1 2 3 4 5 6 7 8 9 10 11 12 13 14 15 16 17 18 19 20 21 22 23 24 25 26 27 28 29 30

Item 11 of 40
Question Id: 59

Mark | Previous | Next | Full Screen | Tutorial | Lab Values | Notes | Calculator | Reverse Color | Text Zoom | Settings

Which of the following is the most likely diagnosis?

- A. Hepatic adenoma
- B. Hepatic angiosarcoma
- C. Hepatoblastoma
- D. Hepatocellular carcinoma
- E. Intrahepatic cholangiocarcinoma
- F. Metastatic liver disease

Submit

Block Time Remaining: 00:00:26
TUTOR

3 | Feedback | Suspend | End Block

Which of the following is the most likely diagnosis?

- A. Hepatic adenoma (1%)
- B. Hepatic angiosarcoma (3%)
- C. Hepatoblastoma (0%)
- D. Hepatocellular carcinoma (9%)
- E. Intrahepatic cholangiocarcinoma (13%)
- ✓ F. Metastatic liver disease (71%)

Omitted
Correct answer

71%
Answered correctly

05 secs
Time Spent

04/09/2020
Last Updated

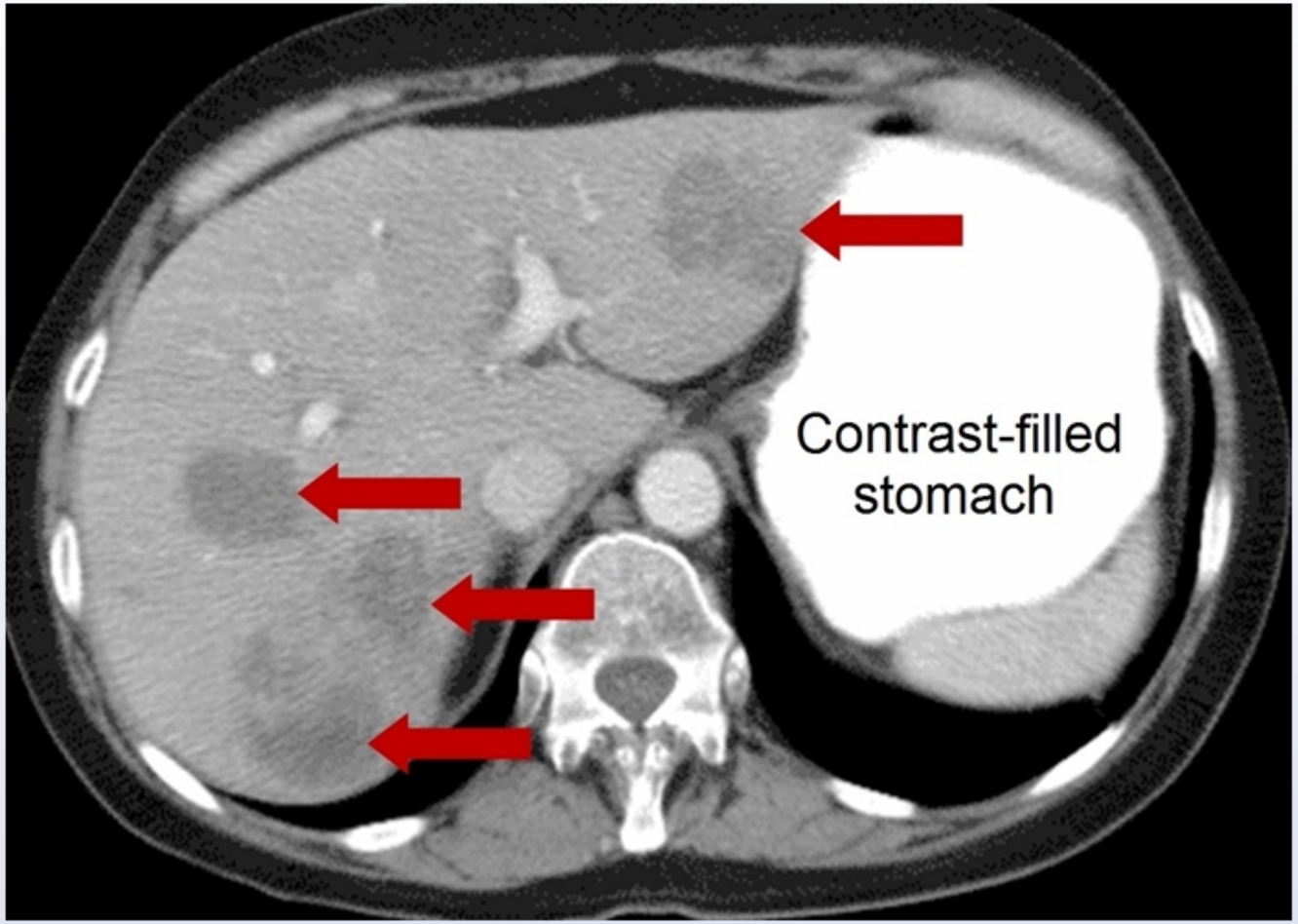

The patient's contrast-enhanced CT scan shows **multiple hypodense masses** in the liver (arrows) consistent with **metastatic liver disease**. Metastases are the most common malignant neoplasms of the adult liver and are 20 times more common than hepatocellular carcinoma. The liver is the second most common site of metastatic spread (after the lymph nodes) because of its large size, dual blood supply, high perfusion rate, and the filtration function of Kupffer cells.

The patient's contrast-enhanced CT scan shows **multiple hypodense masses** in the liver (arrows) consistent with **metastatic liver disease**. Metastases are the most common malignant neoplasms of the adult liver and are 20 times more common than hepatocellular carcinoma. The liver is the second most common site of metastatic spread (after the lymph nodes) because of its large size, dual blood supply, high perfusion rate, and the filtration function of Kupffer cells.

Patients with liver metastases typically have multiple nodules throughout the liver that may replace more than 80% of the hepatic parenchyma, often resulting in marked **hepatomegaly**. The nodules frequently outgrow their vascular supply and become centrally necrotic and umbilicated. Even with significant metastatic involvement, patients may have no clinical or laboratory signs suggestive of hepatic insufficiency. However, once the majority of the liver parenchyma is destroyed or the major bile ducts become obstructed with tumor, patients tend to present with jaundice or **abnormal hepatic enzymes** (eg, elevated aminotransferases, alkaline phosphatase).

(Choice A) Hepatic adenomas are uncommon, benign epithelial tumors of the liver that usually arise as a solitary mass in the right hepatic lobe. They are strongly associated with the use of oral contraceptives and anabolic steroids and are usually diagnosed in patients with upper abdominal pain or detected incidentally on imaging studies. They may rupture and cause intraabdominal hemorrhage.

(Choice B) Hepatic angiosarcomas are associated with recent or remote exposure to vinyl chloride, arsenic, or Thorotrast. This tumor is extremely aggressive and is associated with a poor prognosis, as most patients die within a year.

(Choice C) Hepatoblastoma is the most common liver neoplasm of children and is associated with familial adenomatous polyposis and Beckwith-Wiedemann syndromes. This neoplasm is usually fatal within a few years if not surgically resected.

(Choice D) Hepatocellular carcinoma can present unifocally, multifocally, or as a diffusely infiltrative cancer. It is more common in older patients with a history of cirrhosis or infection with hepatitis B or C.

(Choice E) Cholangiocarcinoma is a rare malignancy that arises from the intra- and extrahepatic bile ducts. Intrahepatic cholangiocarcinoma appears grossly as a treelike mass that grows along the biliary system, typically resulting in extensive intrahepatic metastasis. Risk factors include primary sclerosing cholangitis, fibropolycystic liver disease, and infection with liver flukes in endemic areas. The prognosis is very poor.

Educational objective:
Malignant hepatic lesions most often represent metastasis from another primary site (eg, breast, lung, colon); primary liver neoplasms (eg, hepatocellular carcinoma) are much less common.

often resulting in marked **hepatomegaly**. The nodules frequently outgrow their vascular supply and become centrally necrotic and umbilicated. Even with significant metastatic involvement, patients may have no clinical or laboratory signs suggestive of hepatic insufficiency. However, once the majority of the liver parenchyma is destroyed or the major bile ducts become obstructed with tumor, patients tend to present with jaundice or **abnormal hepatic enzymes** (eg, elevated aminotransferases, alkaline phosphatase).

(Choice A) Hepatic adenomas are uncommon, benign epithelial tumors of the liver that usually arise as a solitary mass in the right hepatic lobe. They are strongly associated with the use of oral contraceptives and anabolic steroids and are usually diagnosed in patients with upper abdominal pain or detected incidentally on imaging studies. They may rupture and cause intraabdominal hemorrhage.

(Choice B) Hepatic angiosarcomas are associated with recent or remote exposure to vinyl chloride, arsenic, or Thorotrast. This tumor is extremely aggressive and is associated with a poor prognosis, as most patients die within a year.

(Choice C) Hepatoblastoma is the most common liver neoplasm of children and is associated with familial adenomatous polyposis and Beckwith-Wiedemann syndromes. This neoplasm is usually fatal within a few years if not surgically resected.

(Choice D) Hepatocellular carcinoma can present unifocally, multifocally, or as a diffusely infiltrative cancer. It is more common in older patients with a history of cirrhosis or infection with hepatitis B or C.

(Choice E) Cholangiocarcinoma is a rare malignancy that arises from the intra- and extrahepatic bile ducts. Intrahepatic cholangiocarcinoma appears grossly as a treelike mass that grows along the biliary system, typically resulting in extensive intrahepatic metastasis. Risk factors include primary sclerosing cholangitis, fibropolycystic liver disease, and infection with liver flukes in endemic areas. The prognosis is very poor.

Educational objective:
Malignant hepatic lesions most often represent metastasis from another primary site (eg, breast, lung, colon); primary liver neoplasms (eg, hepatocellular carcinoma) are much less common.

Pathology	Gastrointestinal & Nutrition	Metastatic liver disease
Subject	System	Topic

Copyright © UWorld. All rights reserved.

A 65-year-old man is found to have iron deficiency anemia. He has had no cough, abdominal pain, melena, or change in bowel habits but reports anorexia and a 5-kg (11-lb) weight loss in the past 2 months. Cardiopulmonary and abdominal examinations are unremarkable. Rectal examination shows guaiac-positive brown stool. A 3-cm mass is found on colonoscopy. Biopsy shows pleomorphic cells with large, dark nuclei forming irregular, crowded glands, some of which contain mucus. Imaging studies reveal multiple mass lesions in the liver and lungs. This patient's neoplasm most likely originated from which of the following locations?

A. Adrenal gland

B. Ascending colon

C. Lungs

D. Prostate

E. Rectosigmoid colon

Submit

A 65-year-old man is found to have iron deficiency anemia. He has had no cough, abdominal pain, melena, or change in bowel habits but reports anorexia and a 5-kg (11-lb) weight loss in the past 2 months. Cardiopulmonary and abdominal examinations are unremarkable. Rectal examination shows guaiac-positive brown stool. A 3-cm mass is found on colonoscopy. Biopsy shows pleomorphic cells with large, dark nuclei forming irregular, crowded glands, some of which contain mucus. Imaging studies reveal multiple mass lesions in the liver and lungs. This patient's neoplasm most likely originated from which of the following locations?

- A. Adrenal gland (1%)
- ✓ B. Ascending colon (54%)
- C. Lungs (5%)
- D. Prostate (6%)
- E. Rectosigmoid colon (31%)

Omitted
Correct answer
B

54%
Answered correctly

02 secs
Time Spent

06/20/2020
Last Updated

Explanation

This elderly patient with weight loss, anorexia, and iron deficiency anemia (IDA) likely has **colon cancer**, the third most common cancer among men (after prostate and lung). It is the most common gastrointestinal malignancy and one of the most common causes of IDA in the elderly. **Right-sided colon cancers** (eg, **ascending colon**) tend to grow as large, bulky masses that protrude into the colonic lumen due to the relatively large caliber of the ascending colon. They are more likely to bleed and therefore more likely to cause IDA. The bleeding is usually occult and detected by positive fecal occult blood testing. By contrast, left-sided tumors (eg, rectosigmoid colon) tend to be smaller. They often infiltrate the

This elderly patient with weight loss, anorexia, and iron deficiency anemia (IDA) likely has **colon cancer**, the third most common cancer among men (after prostate and lung). It is the most common gastrointestinal malignancy and one of the most common causes of IDA in the elderly. **Right-sided colon cancers** (eg, **ascending colon**) tend to grow as large, bulky masses that protrude into the colonic lumen due to the relatively large caliber of the ascending colon. They are more likely to bleed and therefore more likely to cause IDA. The bleeding is usually occult and detected by positive fecal occult blood testing. By contrast, left-sided tumors (eg, rectosigmoid colon) tend to be smaller. They often infiltrate the wall of the colon, encircling it and narrowing the lumen. Therefore, they are more likely to cause obstruction, and patients generally have altered bowel habits, abdominal distension, and nausea and vomiting **(Choice E)**. Liver and lung are common sites of metastases.

(Choice A) Malignant adrenal tumors are rare and typically present with symptoms of excessive hormone secretion (eg, Cushing syndrome). They would not cause IDA.

(Choice C) Although this patient has lung lesions, most patients with lung cancer have referable symptoms at presentation (eg, cough, hemoptysis, dyspnea). Hepatic metastases can occur, but a colonic mass and IDA would be unusual.

(Choice D) Prostate cancer typically develops at the gland periphery, so most patients do not have referable symptoms and urinary symptoms tend to occur late in the disease. Colonic metastases and IDA would be unusual.

Educational objective:
Colon adenocarcinoma is the most common gastrointestinal malignancy. Right-sided lesions are more likely to bleed and cause iron deficiency anemia; left-sided lesions tend to present with obstructing symptoms (eg, altered bowel habits, constipation, abdominal distension, nausea and vomiting).

References

- Colorectal cancer statistics, 2014.
- Tumor location is a prognostic factor in poorly differentiated adenocarcinoma, mucinous adenocarcinoma, and signet-ring cell carcinoma of the colon.

Pathology	Gastrointestinal & Nutrition	Colorectal cancer
Subject	System	Topic

A 27-year-old woman undergoes laparotomy for right lower quadrant pain and is found to have an inflamed terminal ileum. The involved segment of the intestine is removed, and the lesion observed on light microscopy is seen in the image.

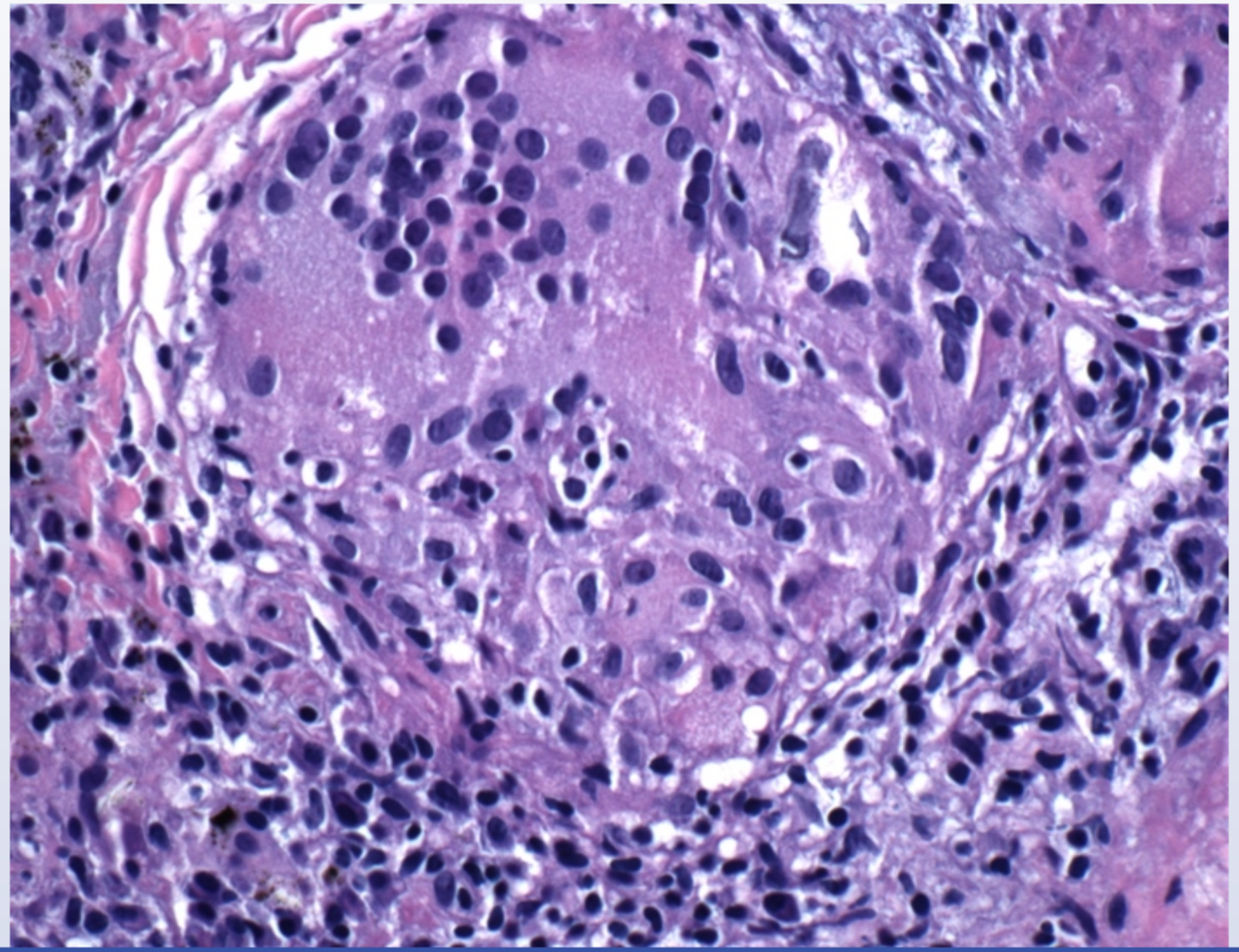

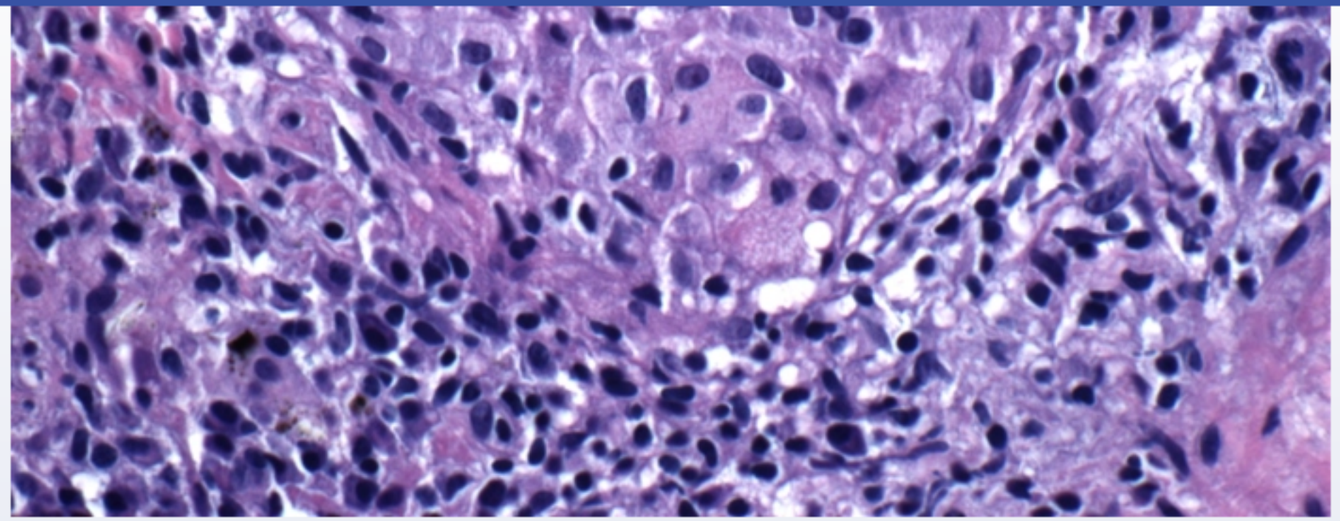

Which of the following cell types most likely mediated the formation of this patient's lesion?

- A. B-lymphocytes
- B. Eosinophils
- C. Neutrophils
- D. Natural killer cells
- E. Th1 cells
- F. Th2 cells

Submit

1 2 3 4 5 6 7 8 9 10 11 12 13 14 15 16 17 18 19 20 21 22 23 24 25 26 27 28 29 30

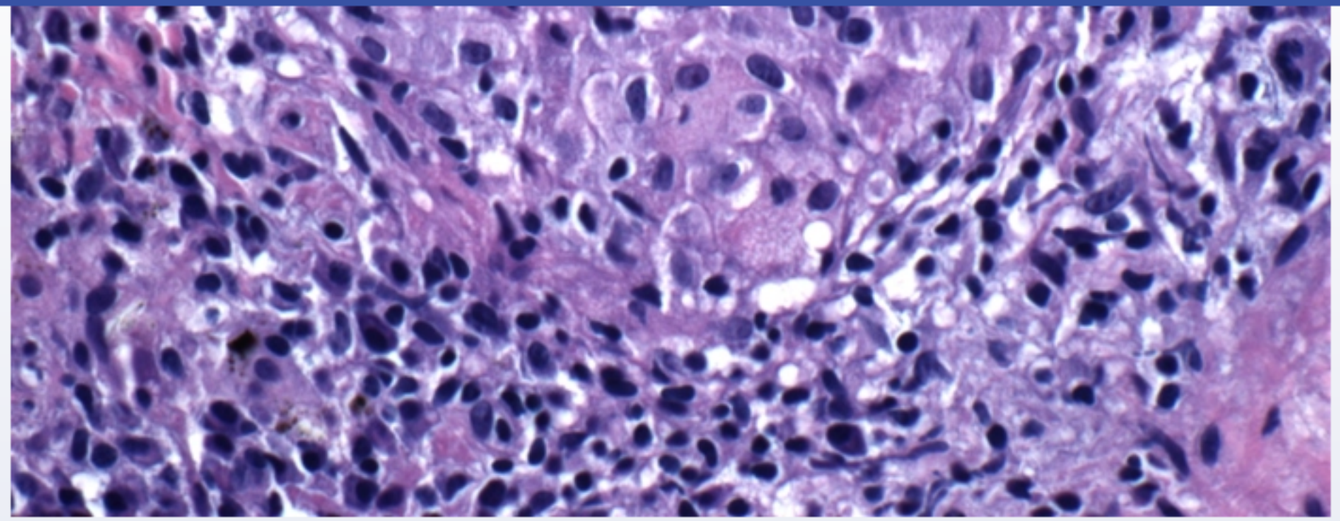

Which of the following cell types most likely mediated the formation of this patient's lesion?

- A. B-lymphocytes (8%)
- B. Eosinophils (1%)
- C. Neutrophils (8%)
- D. Natural killer cells (0%)
- ✓ E. Th1 cells (71%)
- F. Th2 cells (10%)

Omitted
Correct answer

71%
Answered correctly

05 secs
Time Spent

03/19/2020
Last Updated

1 2 3 4 5 6 7 8 9 10 11 12 13 14 15 16 17 18 19 20 21 22 23 24 25 26 27 28 29 30

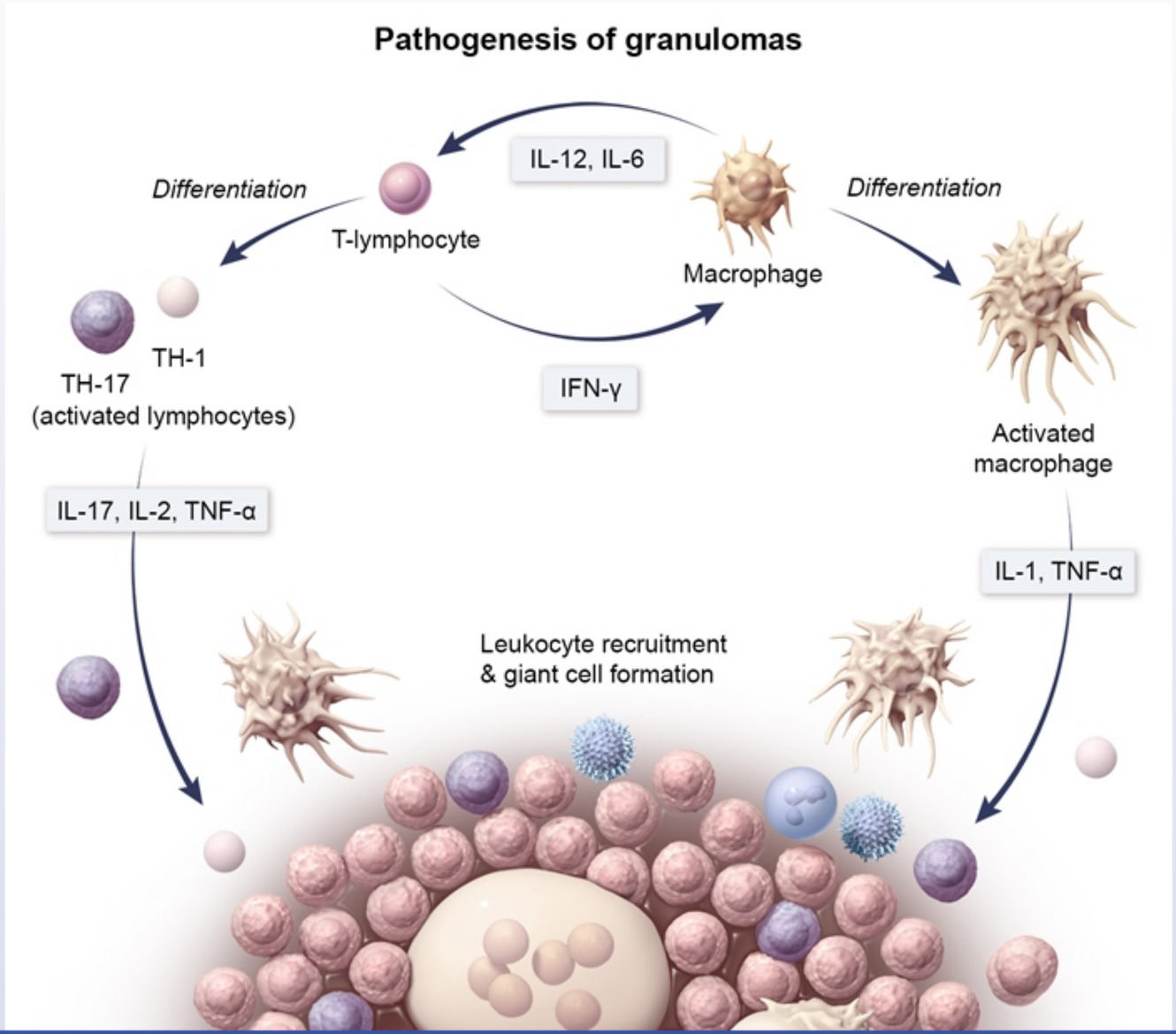

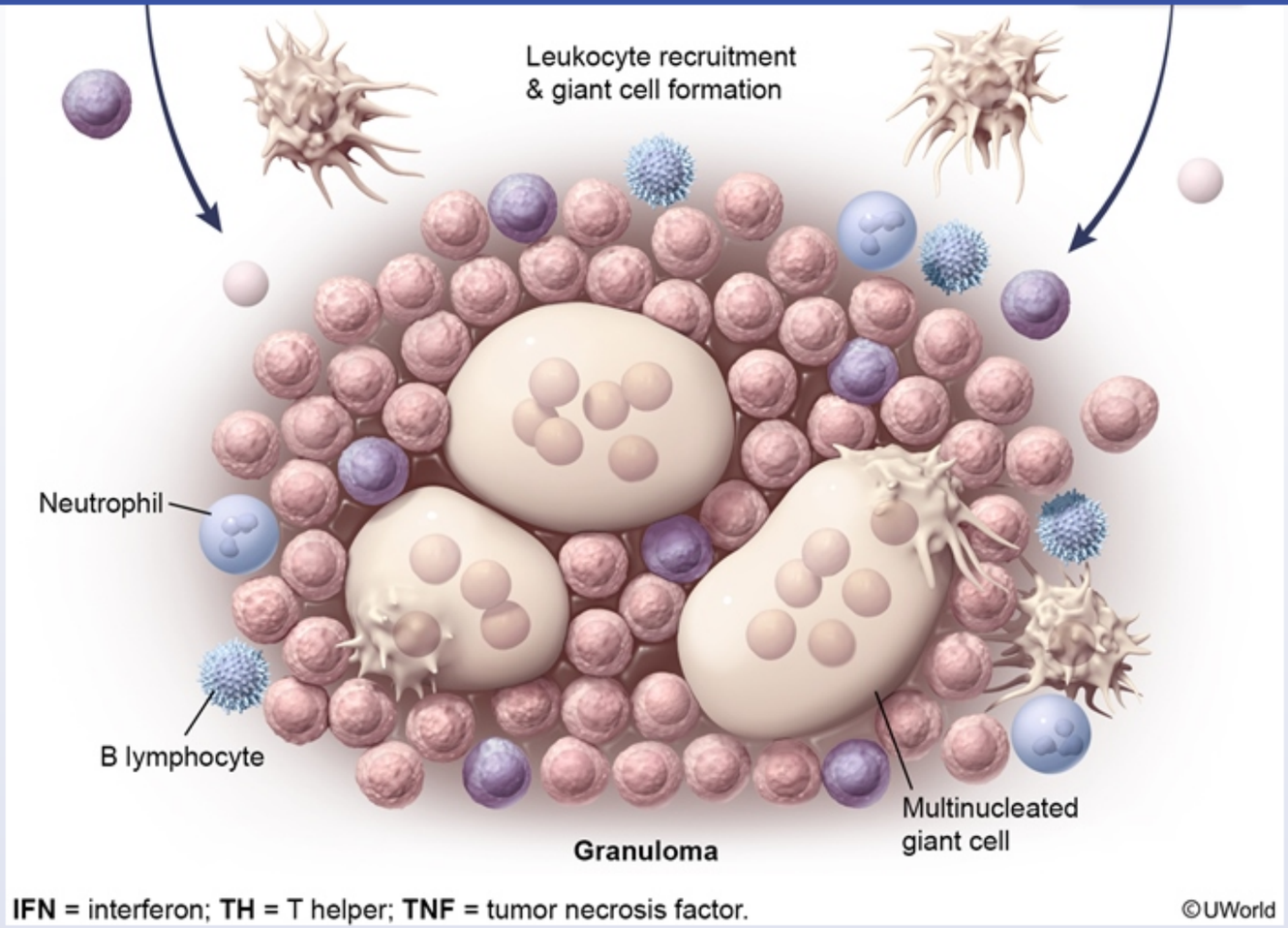

This patient has abdominal pain, ileal inflammation, and a noncaseating granuloma on biopsy, all of which are consistent with Crohn disease (CD). Noncaseating granulomas are seen only in a minority of patients with CD but, when present, are highly suggestive of the diagnosis. Microscopically, granulomas contain a large number of epithelioid macrophages that may fuse together to form multinucleated cells (Langhans giant cells), surrounded by a band of lymphocytes.

IFN = interferon; **TH** = T helper; **TNF** = tumor necrosis factor.

©UWorld

This patient has abdominal pain, ileal inflammation, and a noncaseating granuloma on biopsy, all of which are consistent with Crohn disease (CD). Noncaseating granulomas are seen only in a minority of patients with CD but, when present, are highly suggestive of the diagnosis. Microscopically, granulomas contain a large number of epithelioid macrophages that may fuse together to form multinucleated cells (Langhans giant cells), surrounded by a band of lymphocytes.

Granulomas are considered caseating or noncaseating:

- **Caseating**: Central necrosis is present and has a granular, cheesy appearance. Caseating granulomas are typically seen in infectious etiologies (eg, tuberculosis, leprosy, syphilis, cat scratch disease) due to cell death (both macrophage and bacterial) and the release of cellular contents.
- **Noncaseating**: No central necrosis is present. Noncaseating granulomas are typically seen in autoinflammatory conditions (eg, CD, sarcoidosis, common variable immune deficiency).

Granuloma formation is a product of chronic T-lymphocyte and macrophage activation in response to a difficult-to-eradicate antigen (eg, mycobacterium, self-antigens). Macrophages release tumor necrosis factor–alpha and other proinflammatory cytokines (eg, IL-6, IL-1, **IL-12**) that promote macrophage migration and **Th1 cell differentiation**. Th1 cells are thought to be important in granuloma organization; they produce IL-2 and **interferon-gamma**, which promote further T-cell response, **activation of macrophages**, and differentiation of macrophages into giant cells. Th17 cells are a proinflammatory subset of Th1 cells and contribute to the cell injury seen in CD.

(Choice A) B-lymphocytes differentiate into plasma cells and produce antibodies, thereby mediating the immune response to bacterial infection.

(Choice B) Eosinophils mediate defense reactions against certain parasites. They are also implicated in the pathogenesis of hypersensitivity reactions.

(Choice C) The main function of neutrophils is phagocytosis. They play an active role in nonspecific inflammatory processes.

(Choice D) Natural killer (NK) cells provide a nonspecific defense against virus-infected and tumor cells. They are not known to play a role in CD.

(Choice F) Th2 cells are involved in the pathogenesis of ulcerative colitis. They produce IL-5 and IL-13, which contribute to inflammation and damage of the intestinal mucosa.

- **Noncaseating**: No central necrosis is present. Noncaseating granulomas are typically seen in autoinflammatory conditions (eg, CD, sarcoidosis, common variable immune deficiency).

Granuloma formation is a product of chronic T-lymphocyte and macrophage activation in response to a difficult-to-eradicate antigen (eg, mycobacterium, self-antigens). Macrophages release tumor necrosis factor–alpha and other proinflammatory cytokines (eg, IL-6, IL-1, **IL-12**) that promote macrophage migration and **Th1 cell differentiation**. Th1 cells are thought to be important in granuloma organization; they produce IL-2 and **interferon-gamma**, which promote further T-cell response, **activation of macrophages**, and differentiation of macrophages into giant cells. Th17 cells are a proinflammatory subset of Th1 cells and contribute to the cell injury seen in CD.

(Choice A) B-lymphocytes differentiate into plasma cells and produce antibodies, thereby mediating the immune response to bacterial infection.

(Choice B) Eosinophils mediate defense reactions against certain parasites. They are also implicated in the pathogenesis of hypersensitivity reactions.

(Choice C) The main function of neutrophils is phagocytosis. They play an active role in nonspecific inflammatory processes.

(Choice D) Natural killer (NK) cells provide a nonspecific defense against virus-infected and tumor cells. They are not known to play a role in CD.

(Choice F) Th2 cells are involved in the pathogenesis of ulcerative colitis. They produce IL-5 and IL-13, which contribute to inflammation and damage of the intestinal mucosa.

Educational objective:
Granulomas are characterized by a large number of epithelioid macrophages that may fuse together to form multinucleated cells (Langhans giant cells) surrounded by a band of lymphocytes. Granuloma formation involves chronic Th1 and macrophage activation in response to a difficult-to-eradicate antigen.

Pathology	Gastrointestinal & Nutrition	Inflammatory bowel disease
Subject	System	Topic

Copyright © UWorld. All rights reserved.

A 50-year-old woman comes to the office for an annual examination. She is healthy and takes no medications other than vitamin D and calcium supplements. The patient does not smoke, drink alcohol, or use illicit drugs. Her blood pressure is 118/69 mm Hg. Physical examination is unremarkable. A recent mammogram was normal. A colonoscopy showed 2 polyps, which were excised. On histological examination, one polyp is small and has early adenoma features; the other is larger and has late adenoma features. A mutation in which of the following genes would most likely cause this patient's small early adenoma to grow and develop late adenoma features?

- A. *BRCA1*
- B. *CCND1*
- C. *KRAS*
- D. *NMYC*
- E. *TP53*
- F. *WT1*

Submit

A 50-year-old woman comes to the office for an annual examination. She is healthy and takes no medications other than vitamin D and calcium supplements. The patient does not smoke, drink alcohol, or use illicit drugs. Her blood pressure is 118/69 mm Hg. Physical examination is unremarkable. A recent mammogram was normal. A colonoscopy showed 2 polyps, which were excised. On histological examination, one polyp is small and has early adenoma features; the other is larger and has late adenoma features. A mutation in which of the following genes would most likely cause this patient's small early adenoma to grow and develop late adenoma features?

- A. *BRCA1* (1%)
- B. *CCND1* (2%)
- ✓ C. *KRAS* (75%)
- D. *NMYC* (2%)
- E. *TP53* (16%)
- F. *WT1* (0%)

Omitted
Correct answer
C

75%
Answered correctly

02 secs
Time Spent

01/13/2020
Last Updated

Explanation

Adenoma to carcinoma sequence

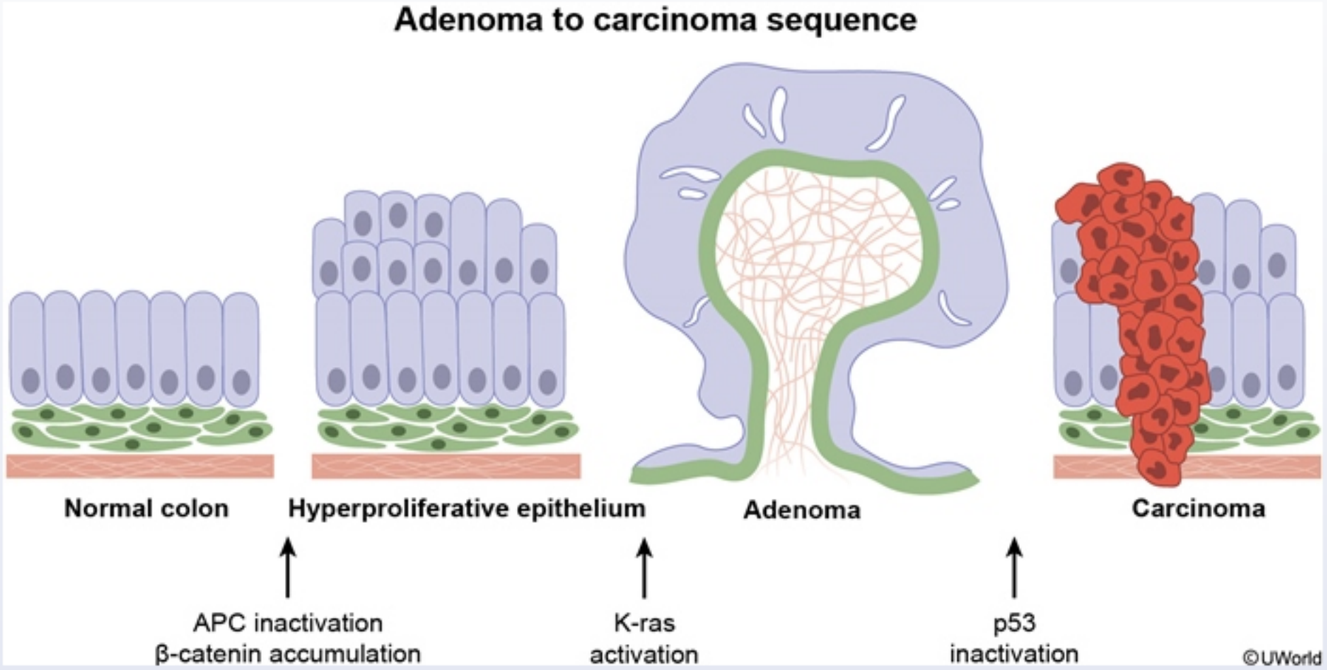

Most colon adenocarcinomas develop from preexisting adenomatous polyps (adenomas). **Colon adenomas** usually occur in patients in their 50s and 60s and are considered **premalignant**. On average, 10 years are required for malignant transformation of adenoma; therefore, early detection and excision of adenomatous polyps can help prevent colon adenocarcinoma. Features that impact the malignant potential of adenomatous polyps include **size** (<1 cm, unlikely to undergo malignant transformation; >4 cm, 40% risk of malignancy), histologic appearance (**villous** more prone to malignant transformation than tubular), and degree of dysplasia.

Transformation of normal mucosal cells into malignant ones is caused by a series of gene mutations called the **adenoma to carcinoma sequence**:

1. **Progression from normal mucosa to a small adenomatous polyp (adenoma)**. The initial appearance of small adenomatous polyps is attributed to mutation of the *APC* tumor suppressor gene.

adenomatous polyps include **size** (<1 cm, unlikely to undergo malignant transformation; >4 cm, 40% risk of malignancy), histologic appearance (**villous** more prone to malignant transformation than tubular), and degree of dysplasia.

Transformation of normal mucosal cells into malignant ones is caused by a series of gene mutations called the **adenoma to carcinoma sequence**:

1. **Progression from normal mucosa to a small adenomatous polyp (adenoma)**. The initial appearance of small adenomatous polyps is attributed to mutation of the *APC* tumor suppressor gene.
2. **Increase in the size of the adenoma**. Mutation of the *KRAS* protooncogene is thought to facilitate this step (going from a small early to a large late adenoma, as with this patient) by leading to **uncontrolled cell proliferation**. Normally, *KRAS* encodes for a G protein-like protein that regulates the cell cycle by stimulating and inhibiting it as necessary. Mutation of *KRAS* into its oncogene form leads to a constitutively activated GTP-bound protein.
3. **Malignant transformation** of adenoma into carcinoma. This step requires mutation of ***TP53***, a tumor suppressor gene that regulates the cell cycle and promotes repair of damaged DNA; mutations are found in most colon carcinomas but rarely in adenomas **(Choice E)**.

(Choice A) Mutations in the tumor suppressor gene *BRCA* are classically associated with breast and ovarian cancers.

(Choice B) Cyclin D is a protein (encoded by *CCND1*) that regulates cell cycle. Its overexpression is seen in breast, lung, and esophageal cancers and certain types of lymphomas.

(Choice D) An increased number of copies (amplification) of the *NMYC* oncogene are seen in neuroblastoma.

(Choice F) Mutation of *WT1*, a tumor suppressor gene, leads to the development of Wilms tumor.

Educational objective:
The size of adenomatous polyps determines their malignant potential. Adenomas <1 cm are unlikely to undergo malignant transformation, whereas those >4 cm are very likely to progress to adenocarcinoma. *KRAS* protooncogene mutation facilitates the growth of adenomas by causing uncontrolled cell proliferation.

Pathology	Gastrointestinal & Nutrition	Colorectal cancer
Subject	System	Topic

A 54-year-old man comes to the office due to increasing pain in the right upper quadrant, nausea, and unintentional weight loss. Vitals signs are within normal limits. BMI is 21 kg/m^2. The patient appears cachectic and there is scleral icterus. The liver is palpable 3 cm below the right costal margin. No ascites is present. Laboratory studies reveal elevated bilirubin and alkaline phosphatase. Contrast CT scan of the abdomen demonstrates moderately dilated right and left intrahepatic bile ducts, with a vague area of delayed enhancement at their convergence. Biopsy of the lesion reveals columnar cells with hyperchromatic oval nuclei with prominent nucleoli arranged in glandular structures; mucin production with surrounding desmoplastic reaction is present. Which of the following is the most likely diagnosis?

A. Cholangiocarcinoma

B. Focal nodular hyperplasia

C. Hepatic adenoma

D. Hepatocellular carcinoma

E. Metastatic colon cancer

Submit

A 54-year-old man comes to the office due to increasing pain in the right upper quadrant, nausea, and unintentional weight loss. Vitals signs are within normal limits. BMI is 21 kg/m^2. The patient appears cachectic and there is scleral icterus. The liver is palpable 3 cm below the right costal margin. No ascites is present. Laboratory studies reveal elevated bilirubin and alkaline phosphatase. Contrast CT scan of the abdomen demonstrates moderately dilated right and left intrahepatic bile ducts, with a vague area of delayed enhancement at their convergence. Biopsy of the lesion reveals columnar cells with hyperchromatic oval nuclei with prominent nucleoli arranged in glandular structures; mucin production with surrounding desmoplastic reaction is present. Which of the following is the most likely diagnosis?

- ✓ A. Cholangiocarcinoma (57%)
- B. Focal nodular hyperplasia (2%)
- C. Hepatic adenoma (8%)
- D. Hepatocellular carcinoma (8%)
- E. Metastatic colon cancer (23%)

Omitted
Correct answer
A

57%
Answered correctly

01 sec
Time Spent

04/06/2020
Last Updated

Explanation

Cholangiocarcinoma	
Epidemiology	• Associated with primary sclerosing cholangitis

Cholangiocarcinoma	
Epidemiology	• Associated with primary sclerosing cholangitis
Clinical presentation	• Often clinically silent until advanced • Nausea, weight loss, RUQ pain • Jaundice, hepatomegaly, ± palpable gallbladder (Courvoisier sign)
Laboratory abnormalities	• Cholestatic pattern of liver injury (↑↑ alkaline phosphatase, hyperbilirubinemia)
Imaging	• Bile duct dilation in the absence of obstructing gallstone
Histology	• Adenocarcinoma with cuboidal or columnar cells with prominent nucleoli arranged in glandular structures • + Mucin production, + desmoplasmic response

RUQ = right upper quadrant.

This patient with weight loss, pain in the right upper quadrant (RUQ), and jaundice has radiographic and histologic findings consistent with **cholangiocarcinoma**, a malignancy of the bile duct epithelium. It is associated with primary sclerosing cholangitis; however, it may occur sporadically.

Cholangiocarcinoma is often clinically silent until late in the disease course, when the tumor obstructs bile drainage, leading to a characteristic **cholestatic pattern** of liver injury (elevated alkaline phosphatase, hyperbilirubinemia). Progressive weight loss, **RUQ pain**, **jaundice**, and **hepatomegaly** are typical, and occasionally, the gallbladder is palpable (Courvoisier sign).

Intraductal malignancies are often difficult to visualize radiographically but usually demonstrates **dilated bile ducts** in the absence of an obstructing gallstone. The most frequently involved site is at the **confluence of the right and left hepatic bile ducts** (Klatskin tumors), which may be visible as nonunion of the bile ducts (as in this patient). Most cholangiocarcinomas are **adenocarcinomas** characterized histologically by columnar epithelial cells with prominent nucleoli arranged in **glandular structures** with **mucin** production and significant desmoplasia (reactive fibrous tissue surrounding a malignant mass).

Cholangiocarcinoma is often clinically silent until late in the disease course, when the tumor obstructs bile drainage, leading to a characteristic **cholestatic pattern** of liver injury (elevated alkaline phosphatase, hyperbilirubinemia). Progressive weight loss, **RUQ pain**, **jaundice**, and **hepatomegaly** are typical, and occasionally, the gallbladder is palpable (Courvoisier sign).

Intraductal malignancies are often difficult to visualize radiographically but usually demonstrates **dilated bile ducts** in the absence of an obstructing gallstone. The most frequently involved site is at the **confluence of the right and left hepatic bile ducts** (Klatskin tumors), which may be visible as nonunion of the bile ducts (as in this patient). Most cholangiocarcinomas are **adenocarcinomas** characterized histologically by columnar epithelial cells with prominent nucleoli arranged in **glandular structures** with **mucin** production and significant desmoplasia (reactive fibrous tissue surrounding a malignant mass).

(Choice B) Focal nodular hyperplasia is a *benign*, nonencapsulated liver tumor that typically occurs in women. It is characterized by fibrous septa encasing normal hepatocytes and a central stellate scar, which is visible both histologically and radiographically.

(Choice C) Hepatic adenomas are *benign* lesions that develop most commonly in women taking oral contraceptives. Jaundice and weight loss are unexpected, and an abdominal CT scan usually demonstrates a solitary lesion in the hepatic parenchyma, not the biliary tree. Histology reveals hepatocytes arranged in thin cell plates without atypia.

(Choice D) Hepatocellular carcinoma is a malignant liver mass that most often develops in patients with cirrhosis. Microscopy demonstrates polygonal cells with abundant eosinophilic cytoplasm and prominent nucleoli.

(Choice E) Metastatic colon cancer is characterized by adenocarcinoma with gland formation; however, it usually causes multiple hepatic masses, which are not seen on this patient's CT scan. In addition, the location of the mass at the bifurcation of the common hepatic duct is characteristic of cholangiocarcinoma.

Educational objective:
Cholangiocarcinoma is a malignancy of the bile duct epithelium that eventually obstructs biliary drainage, resulting in cholestasis (elevated alkaline phosphatase, hyperbilirubinemia) with jaundice, weight loss, pain in the right upper quadrant, and hepatomegaly. Imaging often demonstrates dilated bile ducts in the absence of an obstructive gallstone, and biopsy reveals an adenocarcinoma with columnar cells, mucin production, and a significant desmoplastic reaction.

References

Settings

1 2 3 4 5 6 7 8 9 10 11 12 13 14 15 16 17 18 19 20 21 22 23 24 25 26 27 28 29 30

Item 15 of 40
Question Id: 16107

Mark | Previous | Next | Full Screen | Tutorial | Lab Values | Notes | Calculator | Reverse Color | Text Zoom | Settings

Cholangiocarcinoma is often clinically silent until late in the disease course, when the tumor obstructs bile drainage, leading to a characteristic

Exhibit Display

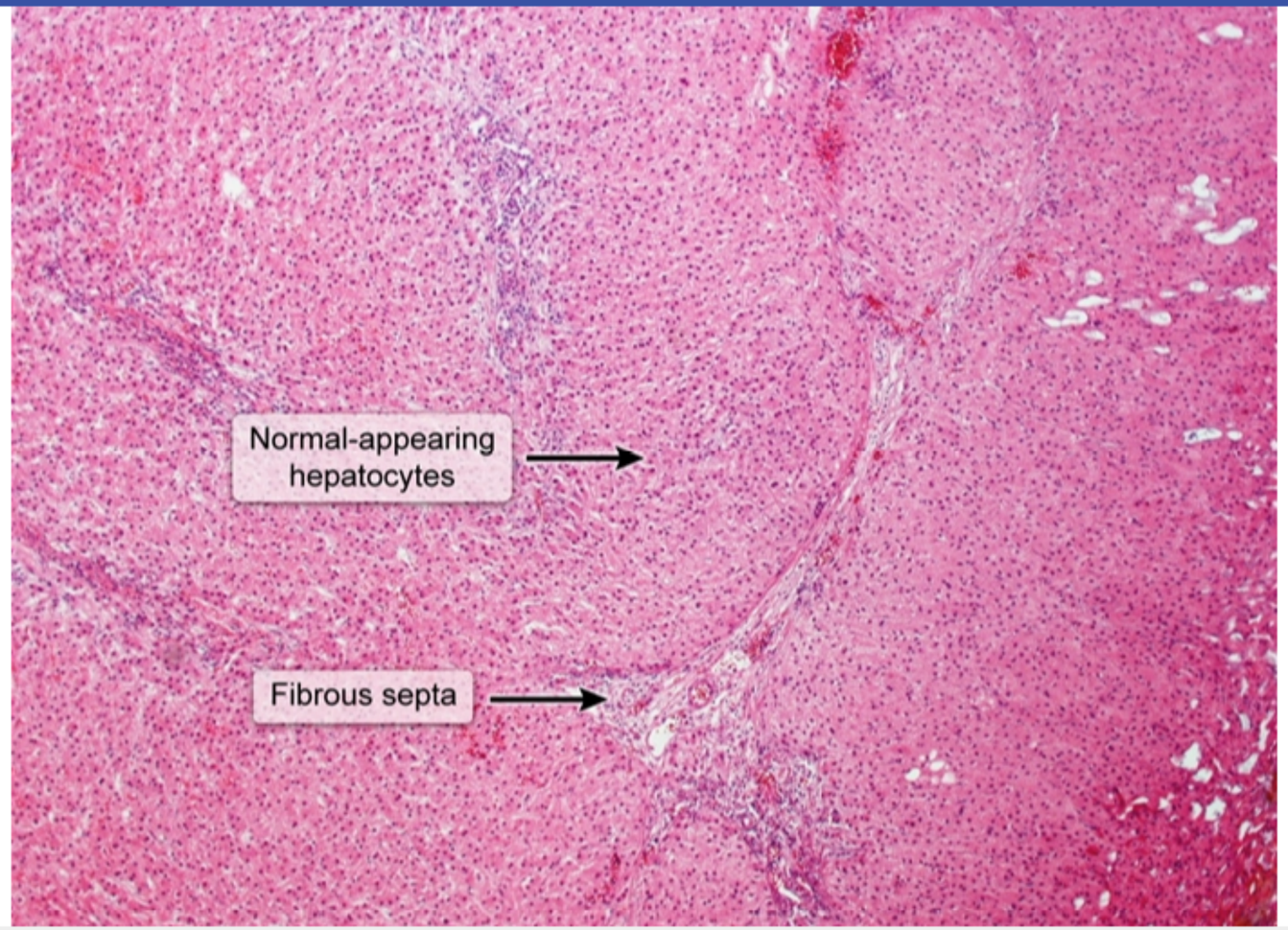

Zoom In | Zoom Out | Reset | Add To Flash Card

References

Block Time Remaining: 00:00:38
TUTOR

0 | Feedback | Suspend | End Block

Cholangiocarcinoma is often clinically silent until late in the disease course, when the tumor obstructs bile drainage, leading to a characteristic

Exhibit Display

Hepatocellular carcinoma

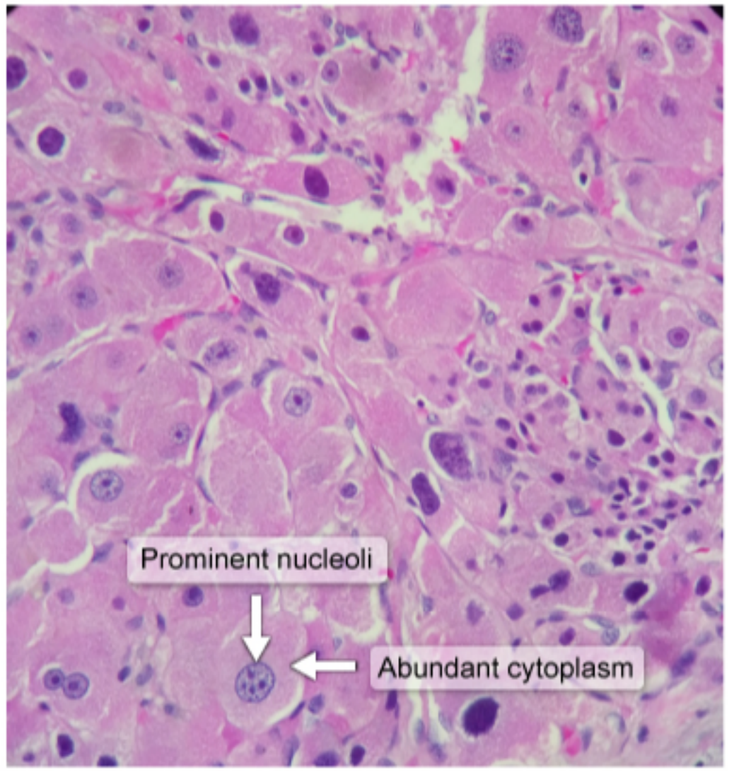

©UWorld

Zoom In | Zoom Out | Reset | Add To Flash Card

References

Settings

1 2 3 4 5 6 7 8 9 10 11 12 13 14 15 16 17 18 19 20 21 22 23 24 25 26 27 28 29 30

Item 15 of 40
Question Id: 16107

Mark | Previous | Next | Full Screen | Tutorial | Lab Values | Notes | Calculator | Reverse Color | Text Zoom | Settings

Cholangiocarcinoma is often clinically silent until late in the disease course, when the tumor obstructs bile drainage, leading to a characteristic

Exhibit Display

Metastatic colon cancer

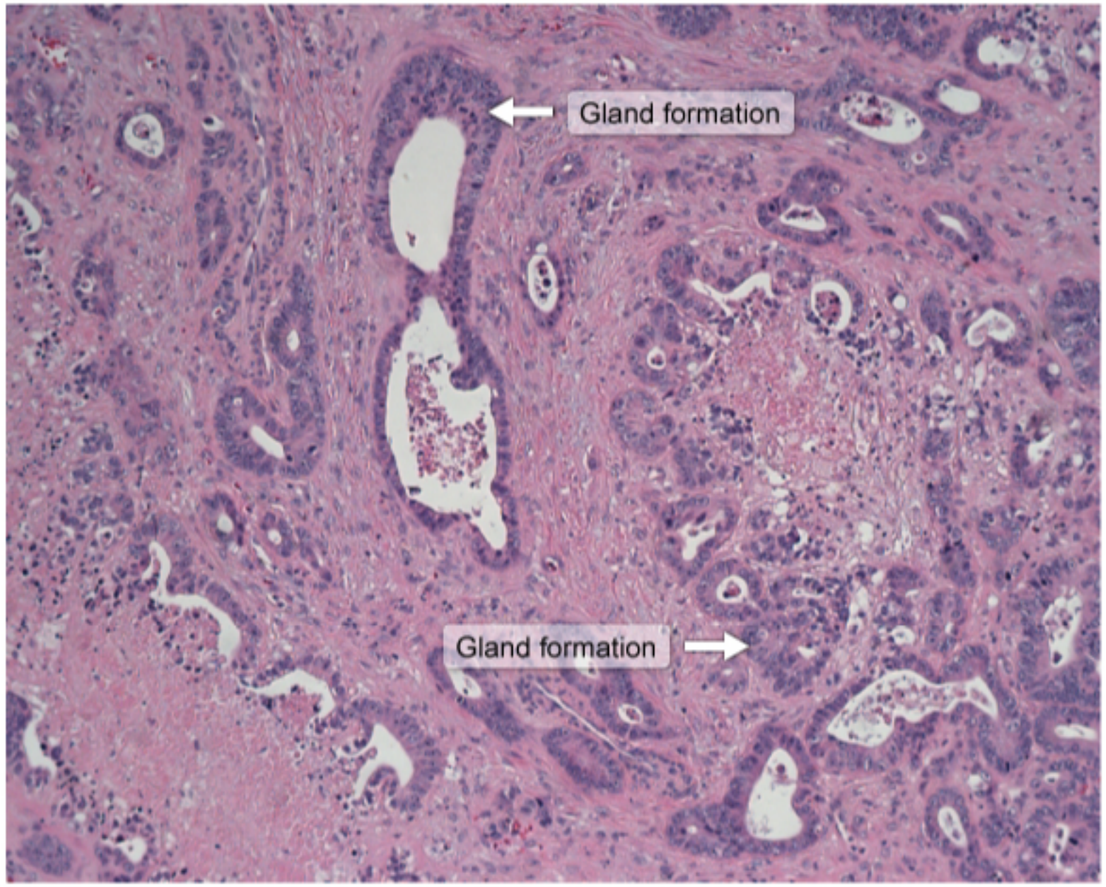

Zoom In | Zoom Out | Reset | Add To Flash Card

References

Block Time Remaining: 00:00:38
TUTOR

0 | Feedback | Suspend | End Block

columnar epithelial cells with prominent nucleoli arranged in **glandular structures** with **mucin** production and significant desmoplasia (reactive fibrous tissue surrounding a malignant mass).

(Choice B) Focal nodular hyperplasia is a *benign*, nonencapsulated liver tumor that typically occurs in women. It is characterized by fibrous septa encasing normal hepatocytes and a central stellate scar, which is visible both histologically and radiographically.

(Choice C) Hepatic adenomas are *benign* lesions that develop most commonly in women taking oral contraceptives. Jaundice and weight loss are unexpected, and an abdominal CT scan usually demonstrates a solitary lesion in the hepatic parenchyma, not the biliary tree. Histology reveals hepatocytes arranged in thin cell plates without atypia.

(Choice D) Hepatocellular carcinoma is a malignant liver mass that most often develops in patients with cirrhosis. Microscopy demonstrates polygonal cells with abundant eosinophilic cytoplasm and prominent nucleoli.

(Choice E) Metastatic colon cancer is characterized by adenocarcinoma with gland formation; however, it usually causes multiple hepatic masses, which are not seen on this patient's CT scan. In addition, the location of the mass at the bifurcation of the common hepatic duct is characteristic of cholangiocarcinoma.

Educational objective:
Cholangiocarcinoma is a malignancy of the bile duct epithelium that eventually obstructs biliary drainage, resulting in cholestasis (elevated alkaline phosphatase, hyperbilirubinemia) with jaundice, weight loss, pain in the right upper quadrant, and hepatomegaly. Imaging often demonstrates dilated bile ducts in the absence of an obstructive gallstone, and biopsy reveals an adenocarcinoma with columnar cells, mucin production, and a significant desmoplastic reaction.

References

- Intrahepatic cholangiocarcinomas have histologically and immunophenotypically distinct small and large duct patterns.

Pathology	Gastrointestinal & Nutrition	Cholangiocarcinoma
Subject	System	Topic

Copyright © UWorld. All rights reserved.

1 2 3 4 5 6 7 8 9 10 11 12 13 14 15 16 17 18 19 20 21 22 23 24 25 26 27 28 29 30

A 65-year-old man comes to the office due to progressive weight loss, jaundice, and anorexia over the last 3 months. His urine has been dark and his stools have been pale. The patient has no prior medical conditions and takes no medications. He has smoked a pack of cigarettes a day for 40 years. He drinks 2 cups of coffee every day and 1 or 2 glasses of wine on most nights. He used illicit drugs for 2 years when he was in his teens but has used none since. The patient has a sedentary lifestyle and frequently consumes red and processed meats. Vital signs are within normal limits. BMI is 28 kg/m^2. Physical examination shows scleral icterus. The chest is clear to auscultation and percussion. Abdominal examination shows an enlarged but nontender gallbladder. There is no ascites. Which of the following is the strongest factor predisposing to this patient's current condition?

- A. Alcohol use
- B. Cigarette smoking
- C. Coffee consumption
- D. Low-fiber diet
- E. Processed meat consumption
- F. Viral hepatitis

Submit

1 2 3 4 5 6 7 8 9 10 11 12 13 14 15 16 17 18 19 20 21 22 23 24 25 26 27 28 29 30

A 65-year-old man comes to the office due to progressive weight loss, jaundice, and anorexia over the last 3 months. His urine has been dark and his stools have been pale. The patient has no prior medical conditions and takes no medications. He has smoked a pack of cigarettes a day for 40 years. He drinks 2 cups of coffee every day and 1 or 2 glasses of wine on most nights. He used illicit drugs for 2 years when he was in his teens but has used none since. The patient has a sedentary lifestyle and frequently consumes red and processed meats. Vital signs are within normal limits. BMI is 28 kg/m^2. Physical examination shows scleral icterus. The chest is clear to auscultation and percussion. Abdominal examination shows an enlarged but nontender gallbladder. There is no ascites. Which of the following is the strongest factor predisposing to this patient's current condition?

- A. Alcohol use (18%)
- ✓ B. Cigarette smoking (44%)
- C. Coffee consumption (0%)
- D. Low-fiber diet (3%)
- E. Processed meat consumption (9%)
- F. Viral hepatitis (23%)

Omitted
Correct answer
B

44%
Answered correctly

02 secs
Time Spent

04/12/2020
Last Updated

Explanation

Explanation

Pancreatic adenocarcinoma	

Risk factors	• Age≥65
	• Smoking
	• Chronic pancreatitis
	• Genetic predisposition
	  ◦ Hereditary pancreatitis
	  ◦ Peutz-Jeghers syndrome
	  ◦ MEN syndromes
	  ◦ Hereditary nonpolyposis colon cancer

Clinical presentation	• Weight loss, anorexia • Abdominal/back pain or painless obstructive jaundice • Migratory thrombophlebitis • Hepatomegaly & ascites (with metastasis)

Pancreatic adenocarcinoma should be considered in any patient with painless **obstructive jaundice** (elevated bilirubin, dark urine, pale stools) and **weight loss**. Courvoisier sign (painless palpable gallbladder in a jaundiced patient) can also raise suspicion, although this can be seen in a number of conditions (eg, cholangiocarcinoma, hepatic duct obstruction). Symptoms of pancreatic malignancy vary with location; tumors at the pancreatic head typically produce obstructive symptoms due to compression of the common bile duct (CBD), whereas those in the body and tail do not obstruct the CBD and often produce midepigastric pain due to invasion of the splanchnic plexus.

Smoking is the most important environmental risk factor for pancreatic cancer and doubles the risk.

(Choice A) Alcohol consumption increases the risk of malignant tumors involving the head, neck, esophagus, and liver. Chronic alcohol consumption can cause chronic pancreatitis, but moderate alcohol use in the absence of chronic pancreatitis does not appear to confer any additional risk for pancreatic cancer.

	• Hepatomegaly & ascites (with metastasis)

Pancreatic adenocarcinoma should be considered in any patient with painless **obstructive jaundice** (elevated bilirubin, dark urine, pale stools) and **weight loss**. Courvoisier sign (painless palpable gallbladder in a jaundiced patient) can also raise suspicion, although this can be seen in a number of conditions (eg, cholangiocarcinoma, hepatic duct obstruction). Symptoms of pancreatic malignancy vary with location; tumors at the pancreatic head typically produce obstructive symptoms due to compression of the common bile duct (CBD), whereas those in the body and tail do not obstruct the CBD and often produce midepigastric pain due to invasion of the splanchnic plexus.

Smoking is the most important environmental risk factor for pancreatic cancer and doubles the risk.

(Choice A) Alcohol consumption increases the risk of malignant tumors involving the head, neck, esophagus, and liver. Chronic alcohol consumption can cause chronic pancreatitis, but moderate alcohol use in the absence of chronic pancreatitis does not appear to confer any additional risk for pancreatic cancer.

(Choice C) Chronic, heavy intake of hot beverages is associated with increased risk for esophageal cancer, but coffee intake does not increase the risk of pancreatic cancer.

(Choices D and E) A low-fiber diet and diets high in processed meats are associated with an increased risk of colon adenocarcinoma.

(Choice F) Chronic viral hepatitis B and C greatly increase the risk of hepatocellular carcinoma. They may increase the risk of pancreatic cancer, but only slightly.

Educational objective:
Smoking is the most important environmental risk factor for pancreatic cancer. Other risk factors include advanced age, chronic pancreatitis, and genetic predisposition (eg, Peutz-Jeghers syndrome).

References

- Alcohol intake and pancreatic cancer: A pooled analysis from the pancreatic cancer cohort consortium (PanScan).

Pathology	Gastrointestinal & Nutrition	Pancreatic cancer
Subject	System	Topic

A 65-year-old woman comes to the office after finding blood in her stool. She is physically active and exercises regularly. She does not use tobacco or alcohol. She has no history of peptic ulcer disease. Her physical examination is unremarkable. Colonoscopy reveals several large adenomatous polyps with severe dysplasia in the sigmoid colon. She undergoes resection of the sigmoid colon, and her carcinoembryonic antigen level is normal. The patient is interested in decreasing her chances of developing new polyps and colon cancer. The physician discusses exercise, healthy weight, and dietary factors associated with reduction of colon cancer risk, including increased fiber intake and reduced consumption of refined sugars and fat. Which of the following enzymes could be inhibited with medication to further reduce this patient's risk of developing recurrent adenoma?

- A. Angiotensin-converting enzyme
- B. Caspase
- C. Cyclooxygenase-2
- D. Glutamate dehydrogenase
- E. Phenylalanine hydroxylase
- F. Xanthine oxidase

Submit

1 2 3 4 5 6 7 8 9 10 11 12 13 14 15 16 17 18 19 20 21 22 23 24 25 26 27 28 29 30

A 65-year-old woman comes to the office after finding blood in her stool. She is physically active and exercises regularly. She does not use tobacco or alcohol. She has no history of peptic ulcer disease. Her physical examination is unremarkable. Colonoscopy reveals several large adenomatous polyps with severe dysplasia in the sigmoid colon. She undergoes resection of the sigmoid colon, and her carcinoembryonic antigen level is normal. The patient is interested in decreasing her chances of developing new polyps and colon cancer. The physician discusses exercise, healthy weight, and dietary factors associated with reduction of colon cancer risk, including increased fiber intake and reduced consumption of refined sugars and fat. Which of the following enzymes could be inhibited with medication to further reduce this patient's risk of developing recurrent adenoma?

- A. Angiotensin-converting enzyme (2%)
- B. Caspase (11%)
- ✓ C. Cyclooxygenase-2 (60%)
- D. Glutamate dehydrogenase (13%)
- E. Phenylalanine hydroxylase (4%)
- F. Xanthine oxidase (8%)

Omitted
Correct answer
C

60%
Answered correctly

01 sec
Time Spent

01/22/2020
Last Updated

Explanation

Adenoma to carcinoma sequence

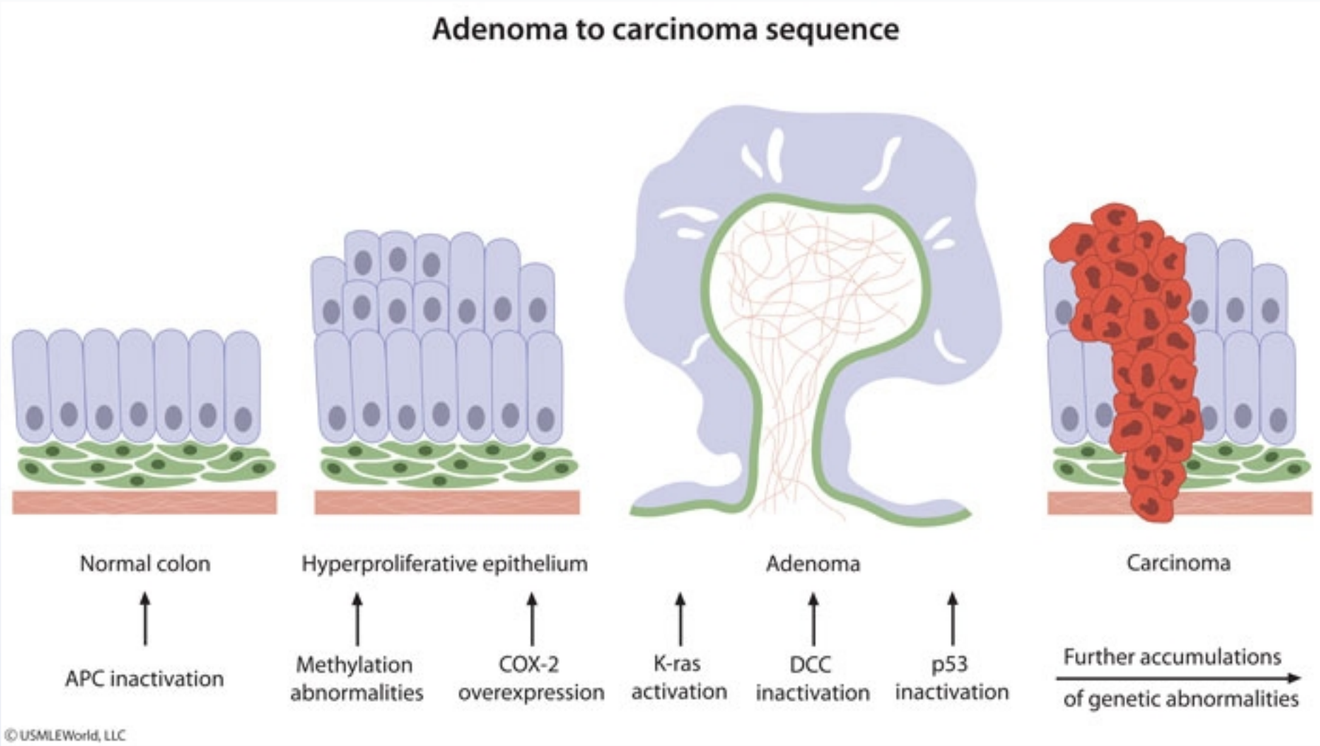

Adenomatous polyps contain dysplastic mucosa and are premalignant. They tend to develop in patients age >50 as a result of mutations in the *APC* tumor suppressor gene, which regulates cell growth and adhesion. Progression to adenocarcinoma proceeds as other mutations occur in genes such as *KRAS* and *TP53*. This accumulation of gene mutations is called the "**adenoma-to-carcinoma sequence**."

Increased activity of the enzyme **cyclooxygenase-2** (COX-2) has been found in many forms of colon adenocarcinoma and in inherited polyposes syndromes. This may be due to the need for COX-induced prostaglandin production, which leads to epithelial proliferation. Regular **aspirin** (a COX inhibitor) intake has been associated with lower rates of colonic adenoma and adenocarcinoma, although this must be balanced against bleeding risk.

(Choice A) Angiotensin-converting enzyme (ACE) converts angiotensin I to angiotensin II, which plays an important role in hypertension and

Adenomatous polyps contain dysplastic mucosa and are premalignant. They tend to develop in patients age >50 as a result of mutations in the *APC* tumor suppressor gene, which regulates cell growth and adhesion. Progression to adenocarcinoma proceeds as other mutations occur in genes such as *KRAS* and *TP53*. This accumulation of gene mutations is called the "**adenoma-to-carcinoma sequence**."

Increased activity of the enzyme **cyclooxygenase-2** (COX-2) has been found in many forms of colon adenocarcinoma and in inherited polyposes syndromes. This may be due to the need for COX-induced prostaglandin production, which leads to epithelial proliferation. Regular **aspirin** (a COX inhibitor) intake has been associated with lower rates of colonic adenoma and adenocarcinoma, although this must be balanced against bleeding risk.

(Choice A) Angiotensin-converting enzyme (ACE) converts angiotensin I to angiotensin II, which plays an important role in hypertension and congestive heart failure. ACE inhibitors are widely used to treat these conditions.

(Choice B) Caspases are cysteine proteases that are an essential component in cellular apoptosis. Inhibition of caspase activity would lead to cells that are resistant to apoptosis; this is one of the mechanisms involved in the progression of the adenoma-to-carcinoma sequence.

(Choices D and E) Glutamate dehydrogenase (produces ammonia for use in the urea cycle) and phenylalanine hydroxylase (converts phenylalanine to tyrosine) have not been implicated in the development of adenomatous polyps.

(Choice F) Xanthine oxidase is an enzyme that participates in uric acid synthesis. Allopurinol is a xanthine oxidase inhibitor used to lower serum levels of uric acid in gout and tumor lysis syndrome.

Educational objective:
Adenomatous polyps contain dysplastic mucosa and are premalignant. Regular screening with timely excision of polyps is effective for prevention of colon adenocarcinoma. Studies have linked increased activity of cyclooxygenase-2 to some forms of colon adenocarcinoma and suggest that regular aspirin use decreases adenomatous polyp formation.

References

- Cyclooxygenase-2 overexpression is common in serrated and non-serrated colorectal adenoma, but uncommon in hyperplastic polyp and sessile serrated polyp/adenoma
- Aspirin and the risk of colorectal cancer in relation to the expression of COX-2.

(Choice A) Angiotensin-converting enzyme (ACE) converts angiotensin I to angiotensin II, which plays an important role in hypertension and congestive heart failure. ACE inhibitors are widely used to treat these conditions.

(Choice B) Caspases are cysteine proteases that are an essential component in cellular apoptosis. Inhibition of caspase activity would lead to cells that are resistant to apoptosis; this is one of the mechanisms involved in the progression of the adenoma-to-carcinoma sequence.

(Choices D and E) Glutamate dehydrogenase (produces ammonia for use in the urea cycle) and phenylalanine hydroxylase (converts phenylalanine to tyrosine) have not been implicated in the development of adenomatous polyps.

(Choice F) Xanthine oxidase is an enzyme that participates in uric acid synthesis. Allopurinol is a xanthine oxidase inhibitor used to lower serum levels of uric acid in gout and tumor lysis syndrome.

Educational objective:
Adenomatous polyps contain dysplastic mucosa and are premalignant. Regular screening with timely excision of polyps is effective for prevention of colon adenocarcinoma. Studies have linked increased activity of cyclooxygenase-2 to some forms of colon adenocarcinoma and suggest that regular aspirin use decreases adenomatous polyp formation.

References

- Cyclooxygenase-2 overexpression is common in serrated and non-serrated colorectal adenoma, but uncommon in hyperplastic polyp and sessile serrated polyp/adenoma
- Aspirin and the risk of colorectal cancer in relation to the expression of COX-2.
- Aspirin for the chemoprevention of colorectal adenomas: meta-analysis of the randomized trials
- Aspirin for prophylactic use in the primary prevention of cardiovascular disease and cancer

Pathology	Gastrointestinal & Nutrition	Colorectal cancer
Subject	System	Topic

Copyright © UWorld. All rights reserved.

A 38-year-old woman comes to the hospital with 4 hours of abdominal pain, nausea, and vomiting. Her pain started in the periumbilical area and is now localized to the right lower quadrant. Temperature is 38.3 C (101 F). On examination, the patient has right lower quadrant tenderness with guarding. An appendectomy is performed, and light microscopy of the appendix shows infiltrating neutrophils in the muscularis propria, consistent with the diagnosis of acute appendicitis. Further evaluation reveals abnormal islands of small cells, as shown in the image below.

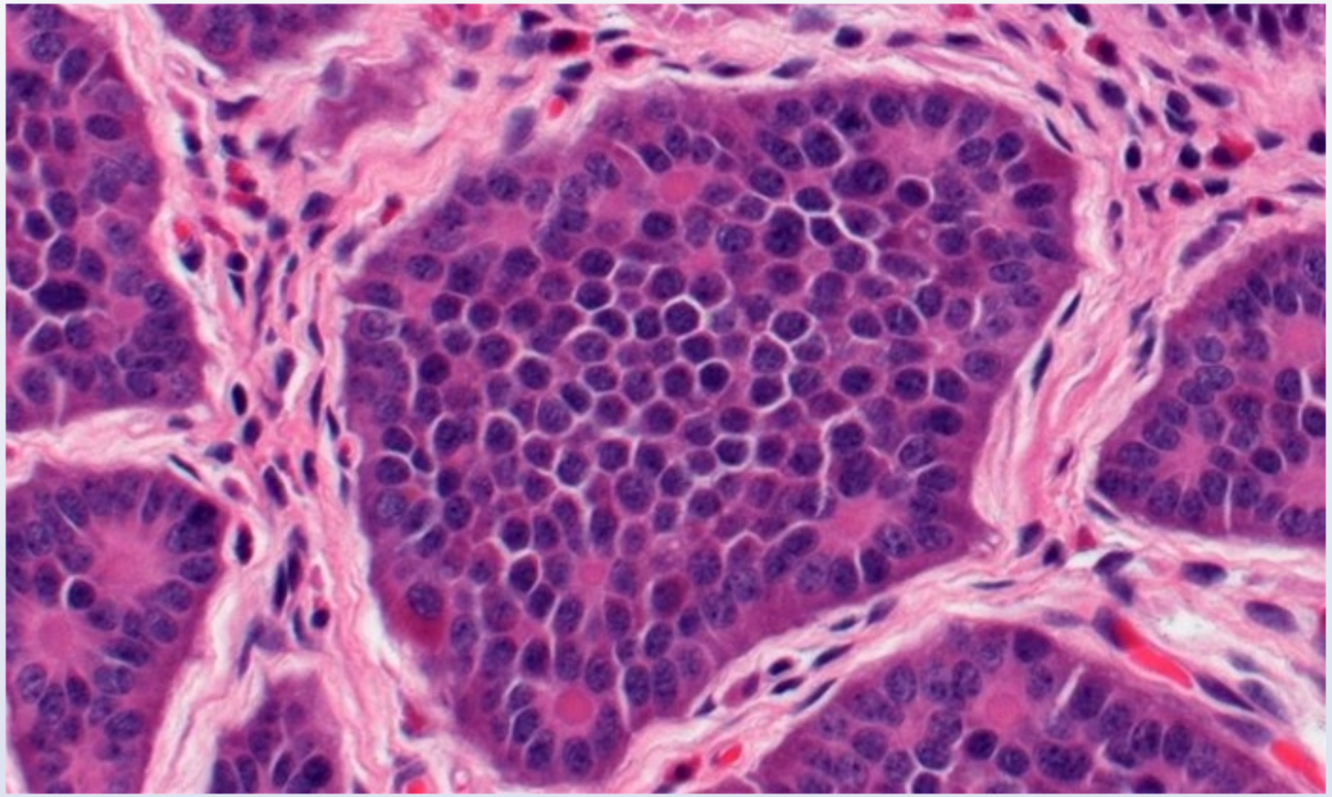

These cells are most likely derived from which of the following sources?

A. Connective tissue

1 2 3 4 5 6 7 8 9 10 11 12 13 14 15 16 17 18 19 20 21 22 23 24 25 26 27 28 29 30

guarding. An appendectomy is performed, and light microscopy of the appendix shows infiltrating neutrophils in the muscularis propria, consistent with the diagnosis of acute appendicitis. Further evaluation reveals abnormal islands of small cells, as shown in the image below.

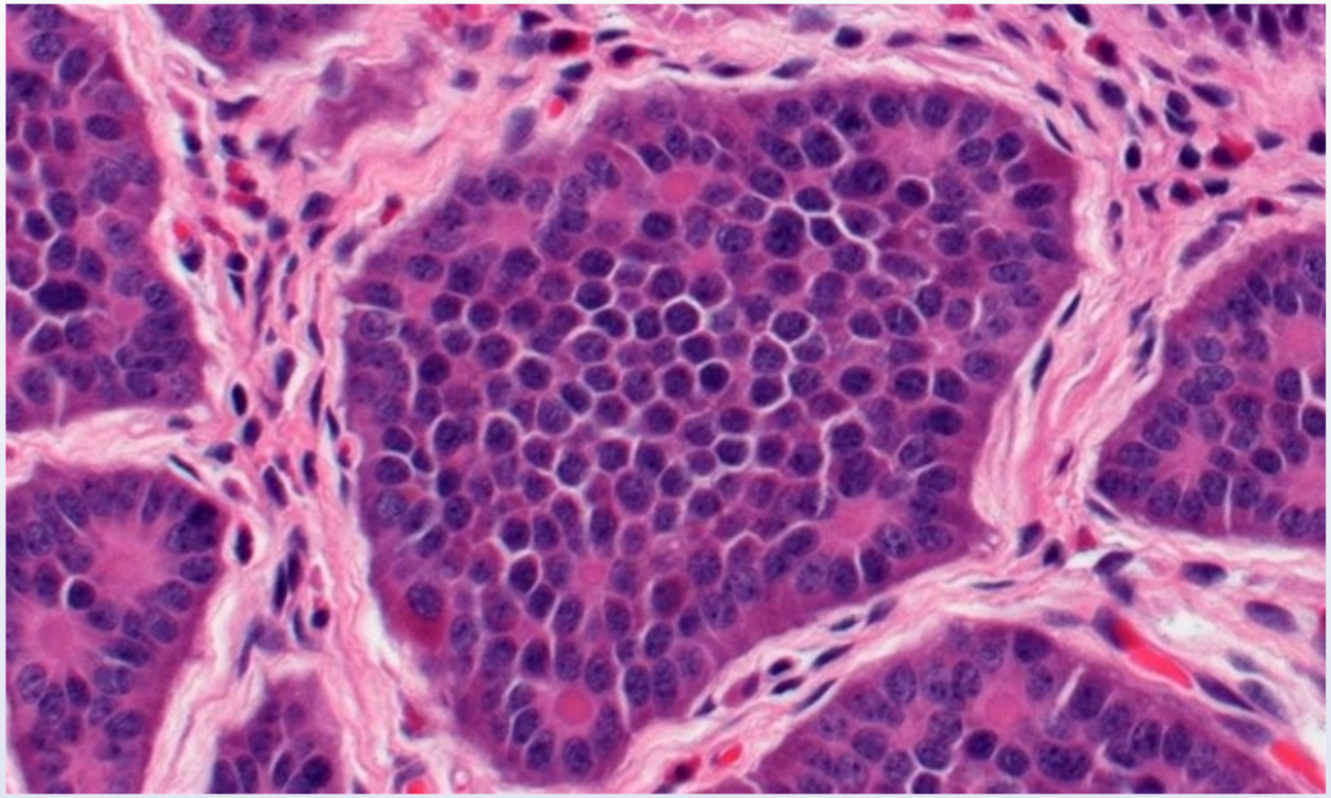

These cells are most likely derived from which of the following sources?

A. Connective tissue

B. Hematopoietic cells

C. Intestinal mucus-secreting cells

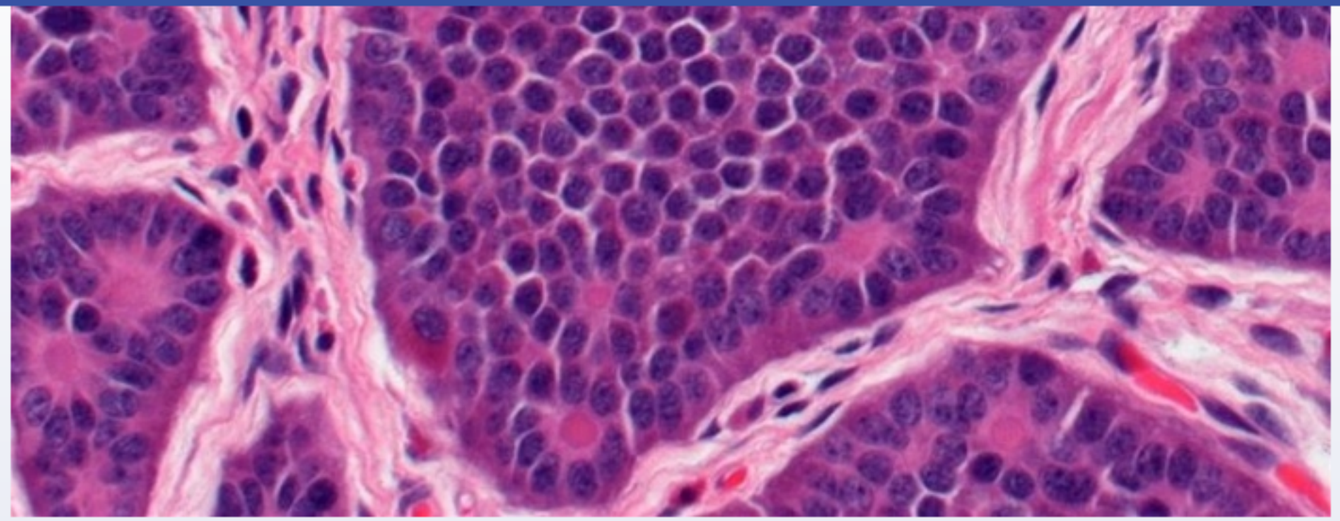

These cells are most likely derived from which of the following sources?

- A. Connective tissue
- B. Hematopoietic cells
- C. Intestinal mucus-secreting cells
- D. Neuroendocrine cells
- E. Smooth muscle cells
- F. Vascular endothelium

Submit

1 2 3 4 5 6 7 8 9 10 11 12 13 14 15 16 17 18 19 20 21 22 23 24 25 26 27 28 29 30

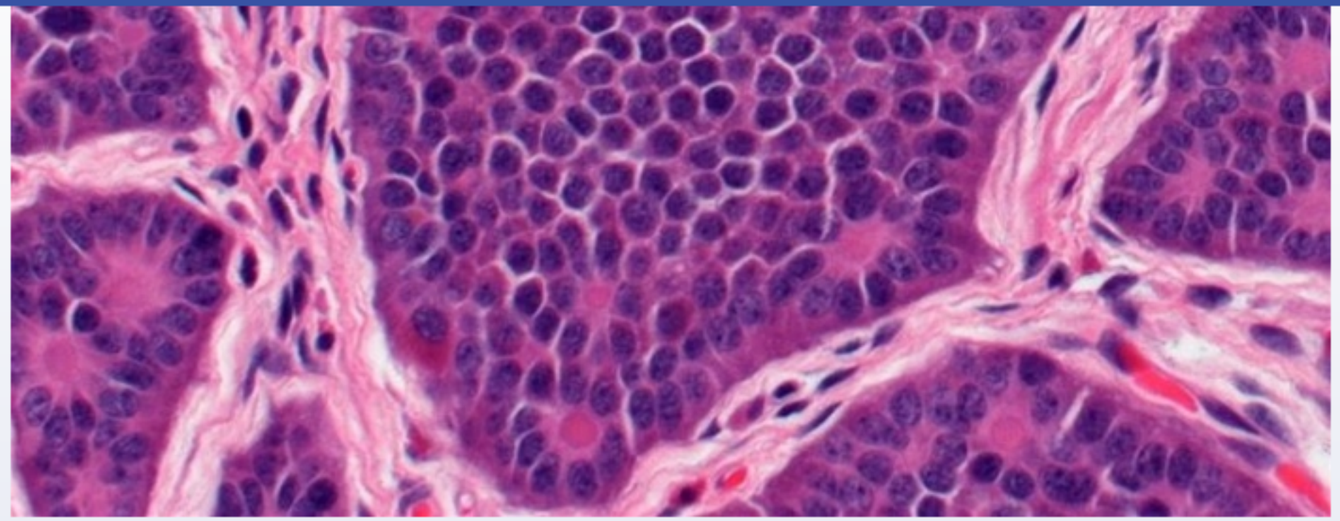

These cells are most likely derived from which of the following sources?

- A. Connective tissue (2%)
- B. Hematopoietic cells (12%)
- C. Intestinal mucus-secreting cells (13%)
- ✓ D. Neuroendocrine cells (66%)
- E. Smooth muscle cells (2%)
- F. Vascular endothelium (2%)

Omitted
Correct answer

66%
Answered correctly

07 secs
Time Spent

02/03/2020
Last Updated

The image shows the typical microscopic appearance of a **carcinoid tumor**. Note the **uniformity** in shape and size of the cells that comprise the **islands**. Trabeculae, glands, strands, or sheets of cells may also be formed. Tumor cells have an **eosinophilic** cytoplasm and **oval-to-round** stippled nuclei. On electron microscopy, multiple dense-core granules are seen in the cytoplasm; these contain secretory products such as vasoactive molecules (eg, serotonin, bradykinin, histamine) and hormones (eg, gastrin).

Carcinoid tumors are malignant transformations of **neuroendocrine cells**, most commonly located in the gastrointestinal tract (eg, small intestine, rectum, appendix), followed by the bronchopulmonary system. The majority of appendiceal carcinoids have a benign clinical course. They are usually found at the tip of the appendix in asymptomatic patients who have undergone appendectomy for unrelated reasons. Tumors at the base of the appendix may cause obstruction and **appendicitis**. In rare cases, large tumors will metastasize to the liver, causing carcinoid syndrome (flushing, diarrhea, bronchospasm).

(Choice A) Connective tissue can be a source of both benign (fibromas) and malignant (fibrosarcomas) tumors.

(Choice B) Abnormal proliferation of hematopoietic cells leads to a variety of myeloid and lymphoid neoplasms.

(Choice C) Intestinal epithelial cells (both absorptive and mucus-secreting) can give rise to intestinal adenocarcinomas.

(Choice E) Smooth muscle cells give rise to leiomyomas and leiomyosarcomas.

(Choice F) Vascular endothelial cells can be a source of benign (hemangioma), intermediate (hemangioendothelioma), and malignant (angiosarcoma) tumors.

Educational objective:
Carcinoid tumors are composed of islands or sheets of uniform cells with eosinophilic cytoplasm and oval-to-round stippled nuclei. These tumors are often derived from neuroendocrine cells in the gastrointestinal tract. Appendiceal carcinoids typically have a benign course but may cause appendicitis or, rarely, carcinoid syndrome (eg, with liver metastasis).

References

- Updated population-based review of carcinoid tumors.
- Carcinoid tumor of the appendix: A case report.
- Gastrointestinal neuroendocrine/neuroectodermal tumors

stippled nuclei. On electron microscopy, multiple dense-core granules are seen in the cytoplasm; these contain secretory products such as vasoactive molecules (eg, serotonin, bradykinin, histamine) and hormones (eg, gastrin).

Carcinoid tumors are malignant transformations of **neuroendocrine cells**, most commonly located in the gastrointestinal tract (eg, small intestine, rectum, appendix), followed by the bronchopulmonary system. The majority of appendiceal carcinoids have a benign clinical course. They are usually found at the tip of the appendix in asymptomatic patients who have undergone appendectomy for unrelated reasons. Tumors at the base of the appendix may cause obstruction and **appendicitis**. In rare cases, large tumors will metastasize to the liver, causing carcinoid syndrome (flushing, diarrhea, bronchospasm).

(Choice A) Connective tissue can be a source of both benign (fibromas) and malignant (fibrosarcomas) tumors.

(Choice B) Abnormal proliferation of hematopoietic cells leads to a variety of myeloid and lymphoid neoplasms.

(Choice C) Intestinal epithelial cells (both absorptive and mucus-secreting) can give rise to intestinal adenocarcinomas.

(Choice E) Smooth muscle cells give rise to leiomyomas and leiomyosarcomas.

(Choice F) Vascular endothelial cells can be a source of benign (hemangioma), intermediate (hemangioendothelioma), and malignant (angiosarcoma) tumors.

Educational objective:
Carcinoid tumors are composed of islands or sheets of uniform cells with eosinophilic cytoplasm and oval-to-round stippled nuclei. These tumors are often derived from neuroendocrine cells in the gastrointestinal tract. Appendiceal carcinoids typically have a benign course but may cause appendicitis or, rarely, carcinoid syndrome (eg, with liver metastasis).

References

- Updated population-based review of carcinoid tumors.
- Carcinoid tumor of the appendix: A case report.
- Gastrointestinal neuroendocrine/neuroectodermal tumors.

Settings

1
2
3
4
5
6
7
8
9
10
11
12
13
14
15
16
17
18
19
20
21
22
23
24
25
26
27
28
29
30

Item 18 of 40
Question Id: 424

Mark | Previous | Next | Full Screen | Tutorial | Lab Values | Notes | Calculator | Reverse Color | Text Zoom | Settings

stippled nuclei. On electron microscopy, multiple dense-core granules are seen in the cytoplasm; these contain secretory products such as

Exhibit Display

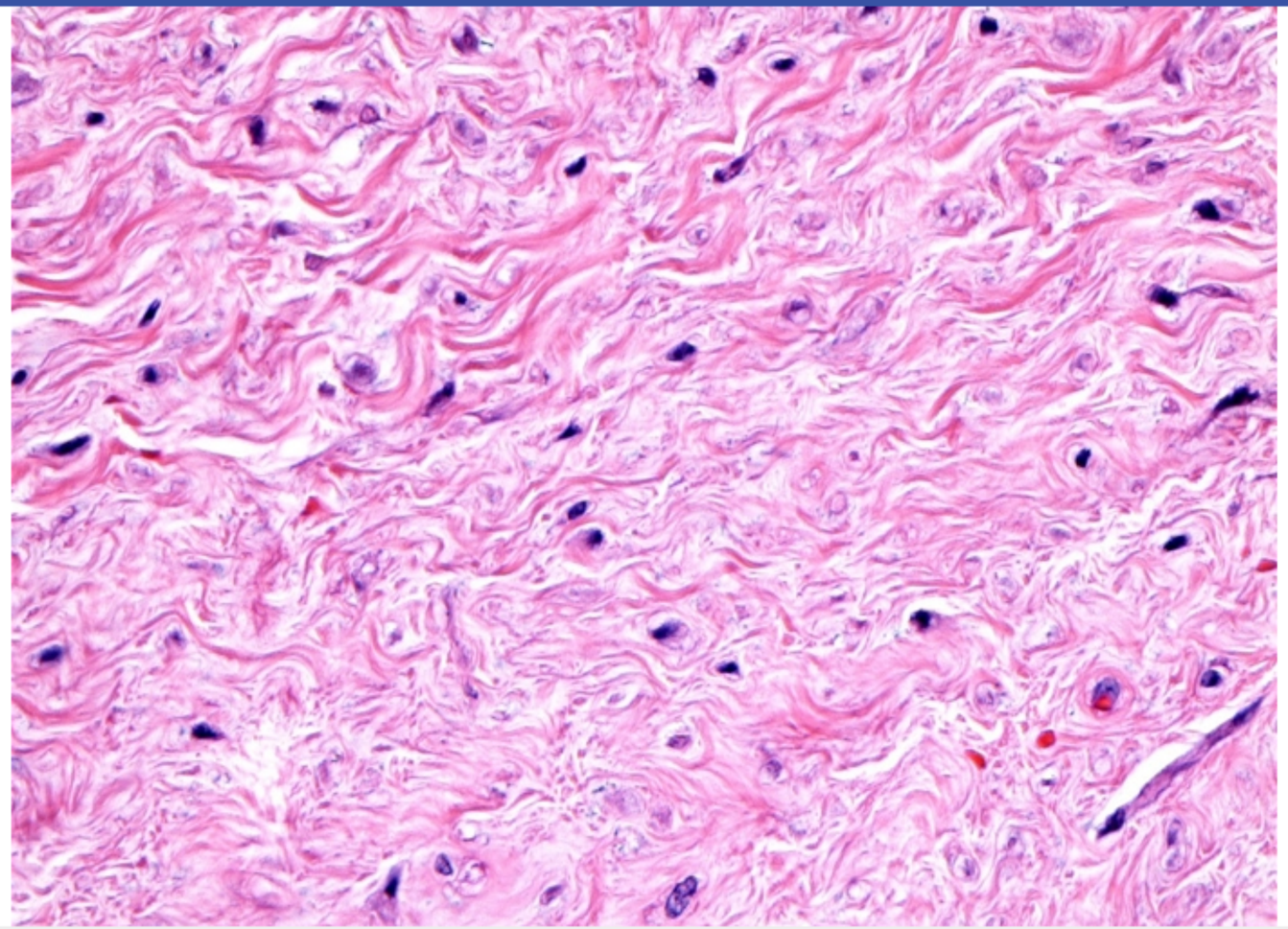

Zoom In | Zoom Out | Reset | Add To New Card | Existing Card

Block Time Remaining: 00:00:48
TUTOR

9 | Feedback | Suspend | End Block

Settings

1 2 3 4 5 6 7 8 9 10 11 12 13 14 15 16 17 18 19 20 21 22 23 24 25 26 27 28 29 30

Item 18 of 40
Question Id: 424

Mark | Previous | Next | Full Screen | Tutorial | Lab Values | Notes | Calculator | Reverse Color | Text Zoom | Settings

stippled nuclei. On electron microscopy, multiple dense-core granules are seen in the cytoplasm; these contain secretory products such as

Exhibit Display

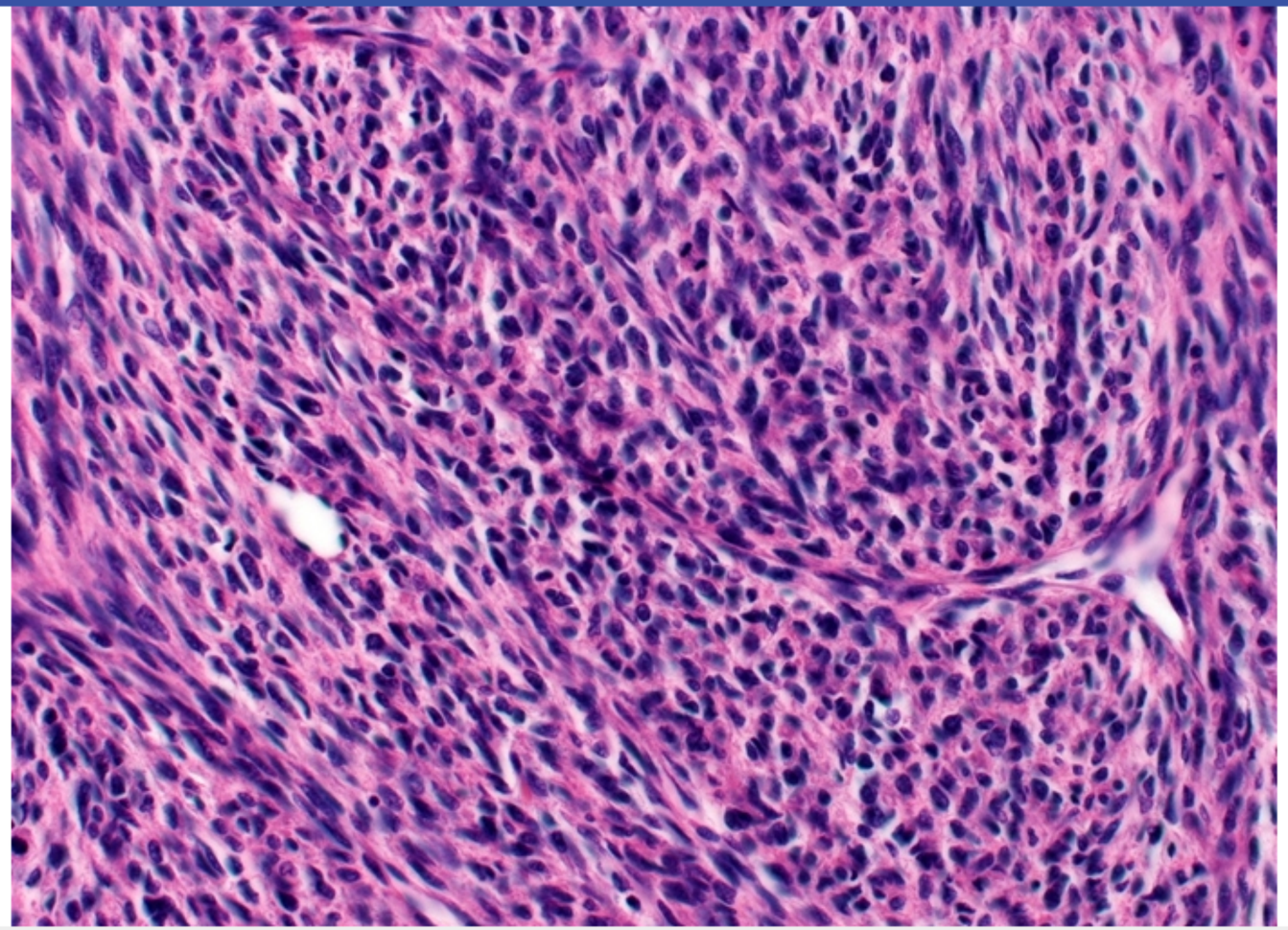

Zoom In | Zoom Out | Reset | Add To New Card | Existing Card

Block Time Remaining: 00:00:48
TUTOR

9 | Feedback | Suspend | End Block

Settings

1 2 3 4 5 6 7 8 9 10 11 12 13 14 15 16 17 18 19 20 21 22 23 24 25 26 27 28 29 30

Item 18 of 40
Question Id: 424

Mark | Previous | Next | Full Screen | Tutorial | Lab Values | Notes | Calculator | Reverse Color | Text Zoom | Settings

stippled nuclei. On electron microscopy, multiple dense-core granules are seen in the cytoplasm; these contain secretory products such as

Exhibit Display

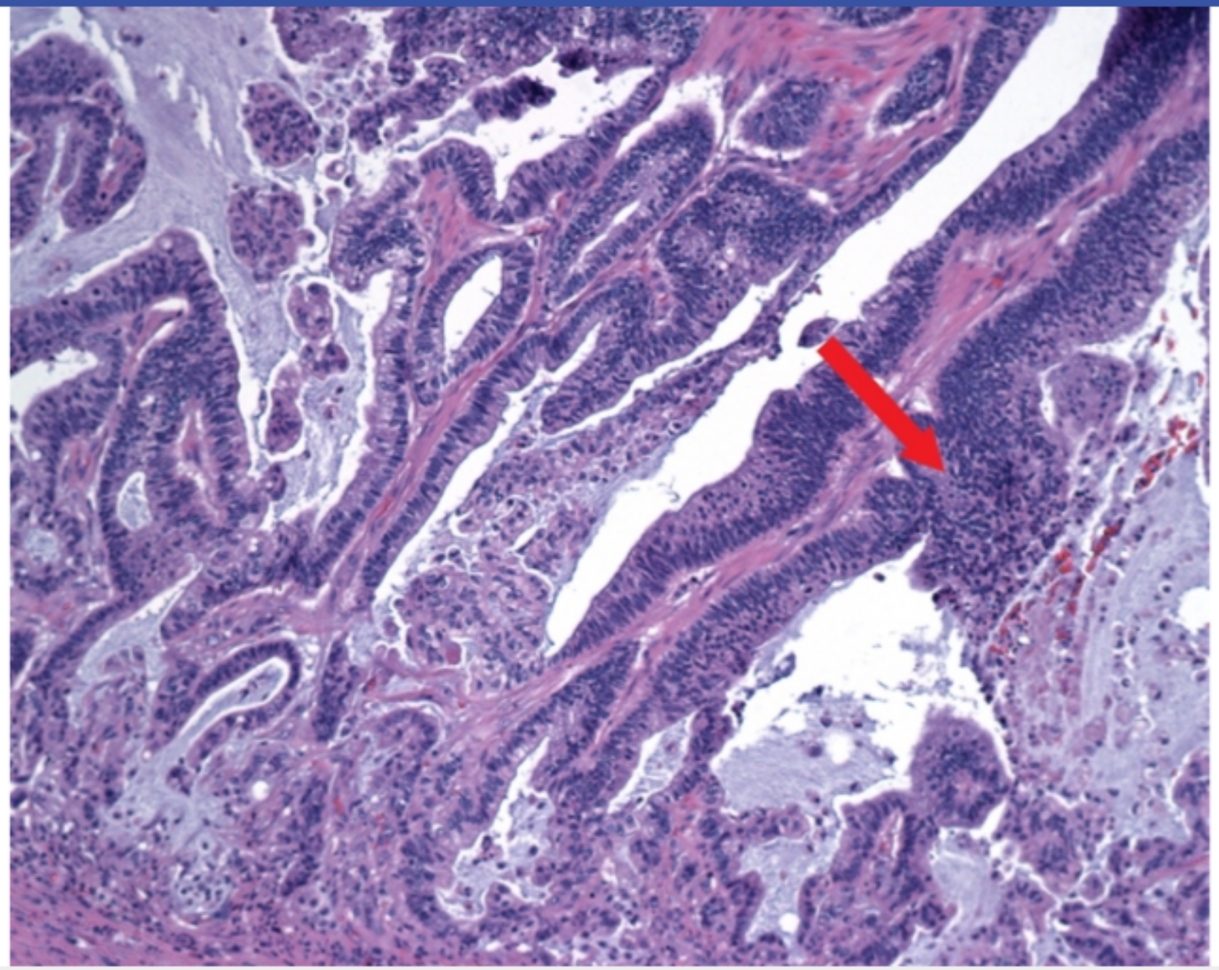

Zoom In | Zoom Out | Reset | Add To New Card | Existing Card

Block Time Remaining: 00:00:48
TUTOR

9 | Feedback | Suspend | End Block

Settings

1
2
3
4
5
6
7
8
9
10
11
12
13
14
15
16
17
18
19
20
21
22
23
24
25
26
27
28
29
30

Item 18 of 40
Question Id: 424

Mark | Previous | Next | Full Screen | Tutorial | Lab Values | Notes | Calculator | Reverse Color | Text Zoom | Settings

stippled nuclei. On electron microscopy, multiple dense-core granules are seen in the cytoplasm; these contain secretory products such as

Exhibit Display

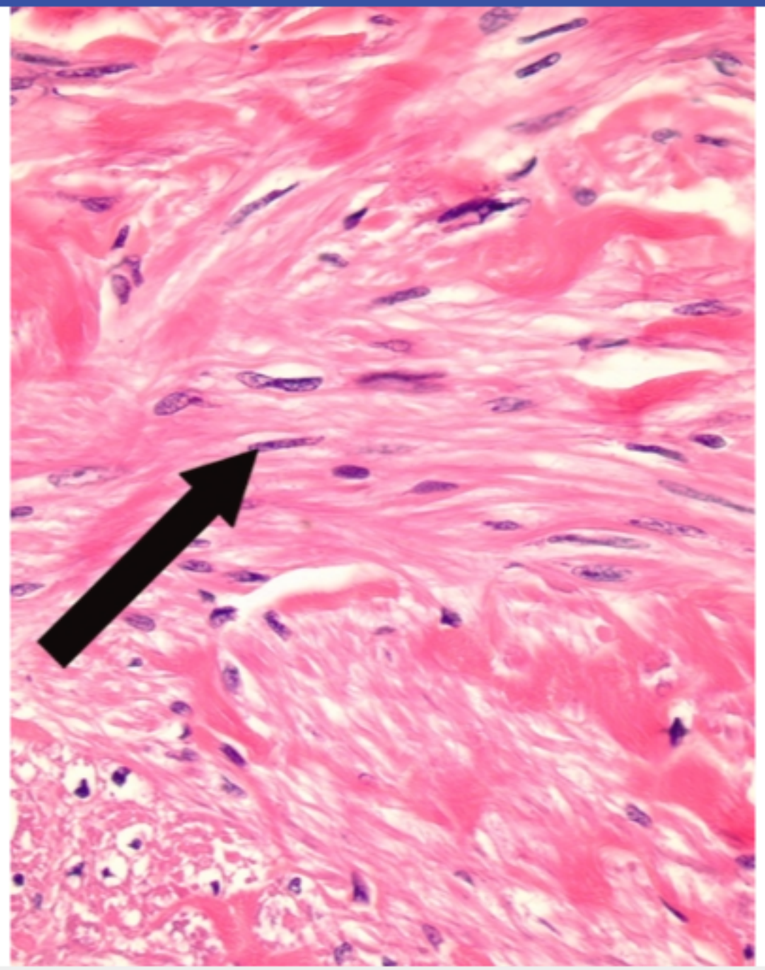

Zoom In | Zoom Out | Reset | Add To New Card | Existing Card

Block Time Remaining: 00:00:48
TUTOR

9 | Feedback | Suspend | End Block

Settings

1
2
3
4
5
6
7
8
9
10
11
12
13
14
15
16
17
18
19
20
21
22
23
24
25
26
27
28
29
30

Item 18 of 40
Question Id: 424

Mark | Previous | Next | Full Screen | Tutorial | Lab Values | Notes | Calculator | Reverse Color | Text Zoom | Settings

stippled nuclei. On electron microscopy, multiple dense-core granules are seen in the cytoplasm; these contain secretory products such as

Exhibit Display

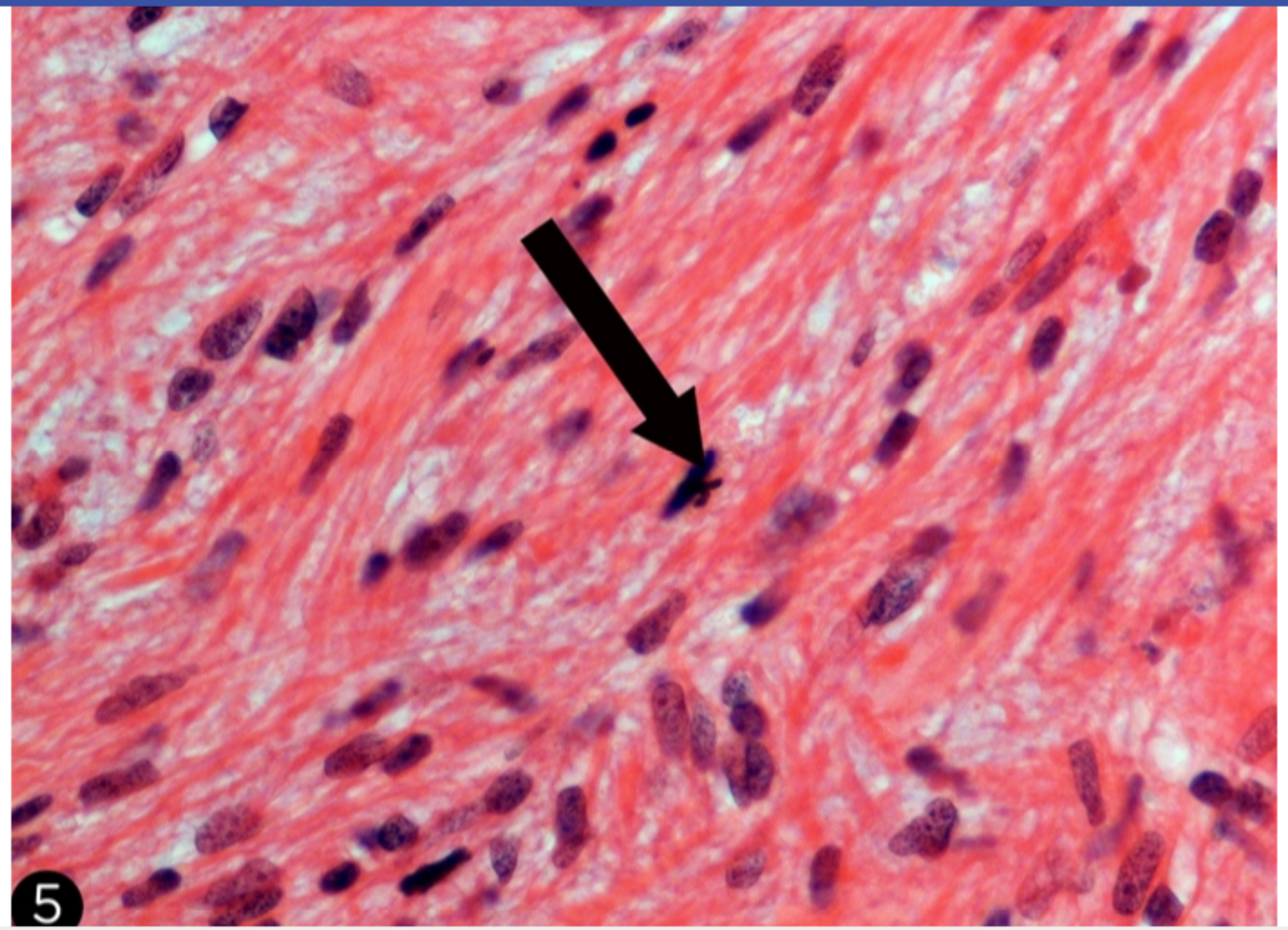

Zoom In | Zoom Out | Reset | Add To New Card | Existing Card

Block Time Remaining: 00:00:48
TUTOR

9 | Feedback | Suspend | End Block

Settings

1 2 3 4 5 6 7 8 9 10 11 12 13 14 15 16 17 18 19 20 21 22 23 24 25 26 27 28 29 30

Item 18 of 40
Question Id: 424

Mark | Previous | Next | Full Screen | Tutorial | Lab Values | Notes | Calculator | Reverse Color | Text Zoom | Settings

stippled nuclei. On electron microscopy, multiple dense-core granules are seen in the cytoplasm; these contain secretory products such as

Exhibit Display

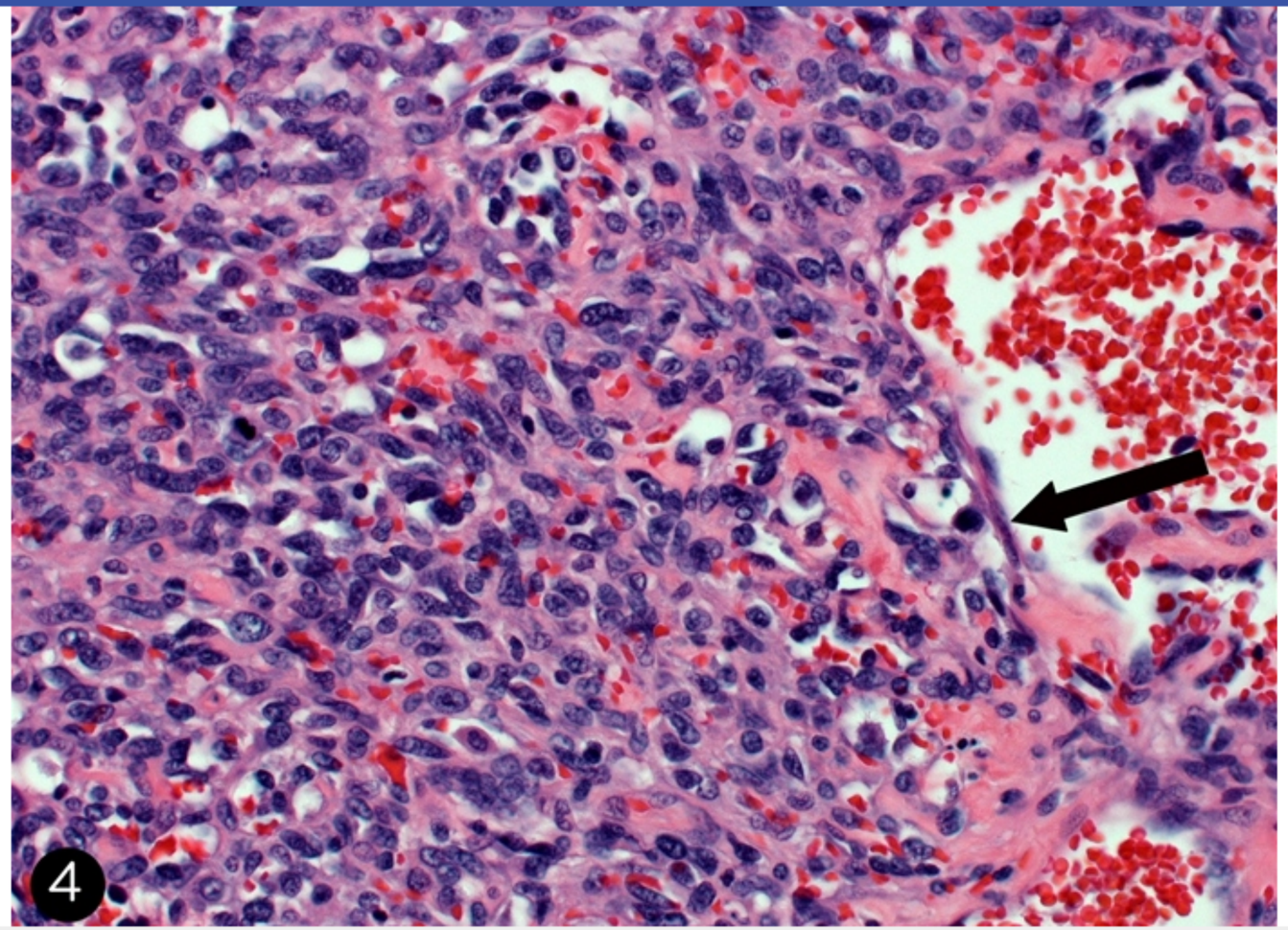

Zoom In | Zoom Out | Reset | Add To New Card | Existing Card

Block Time Remaining: 00:00:48
TUTOR

9 | Feedback | Suspend | End Block

A 32-year-old man with abdominal pain and periodic diarrhea is found to have heme-positive stools. Stool cultures show no growth of pathogenic organisms. Colonoscopy with biopsy of the colonic mucosa is performed. Light microscopy of the tissue sample is shown in the image below.

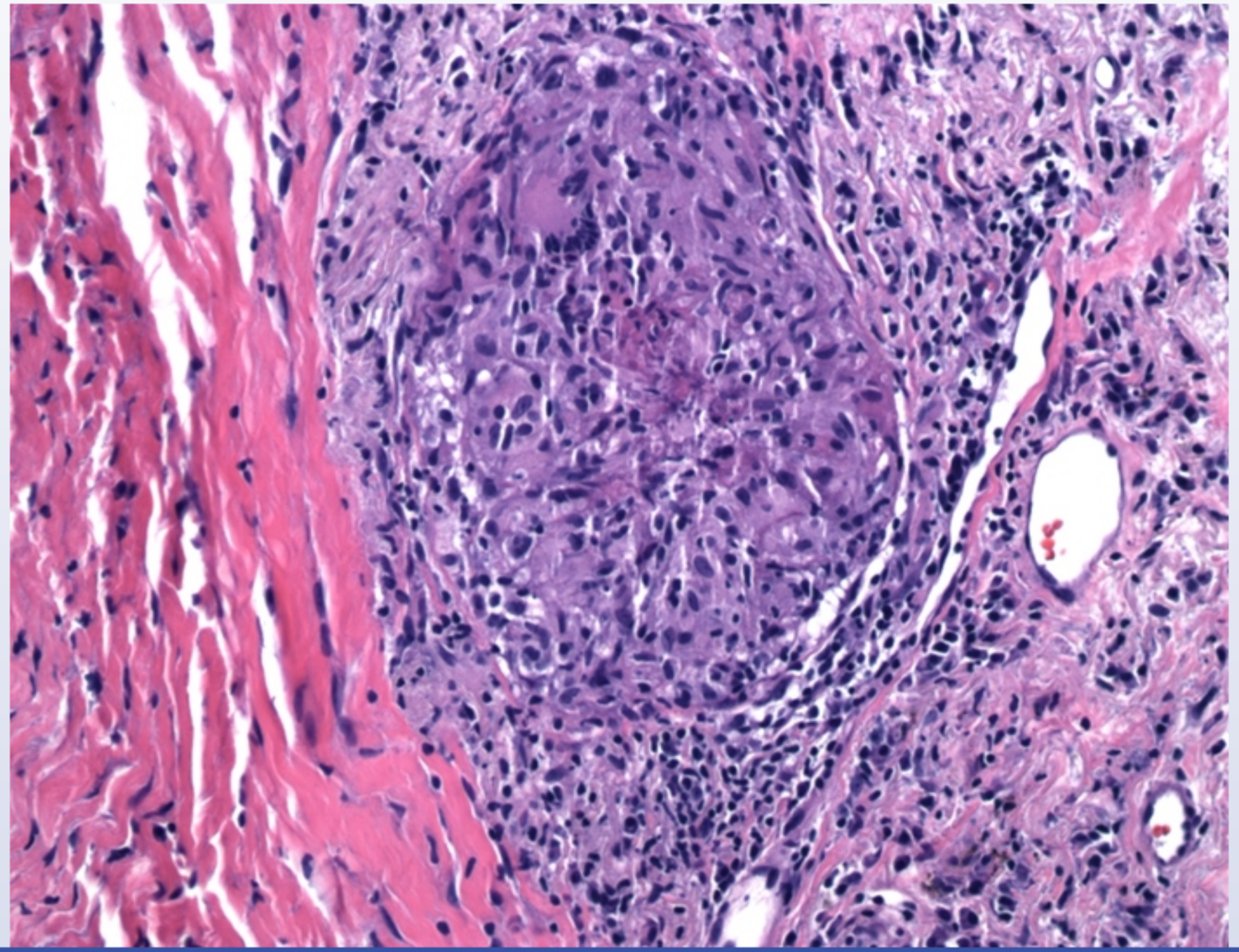

Settings

1 2 3 4 5 6 7 8 9 10 11 12 13 14 15 16 17 18 19 20 21 22 23 24 25 26 27 28 29 30

Item 19 of 40
Question Id: 405

Mark | Previous | Next | Full Screen | Tutorial | Lab Values | Notes | Calculator | Reverse Color | Text Zoom | Settings

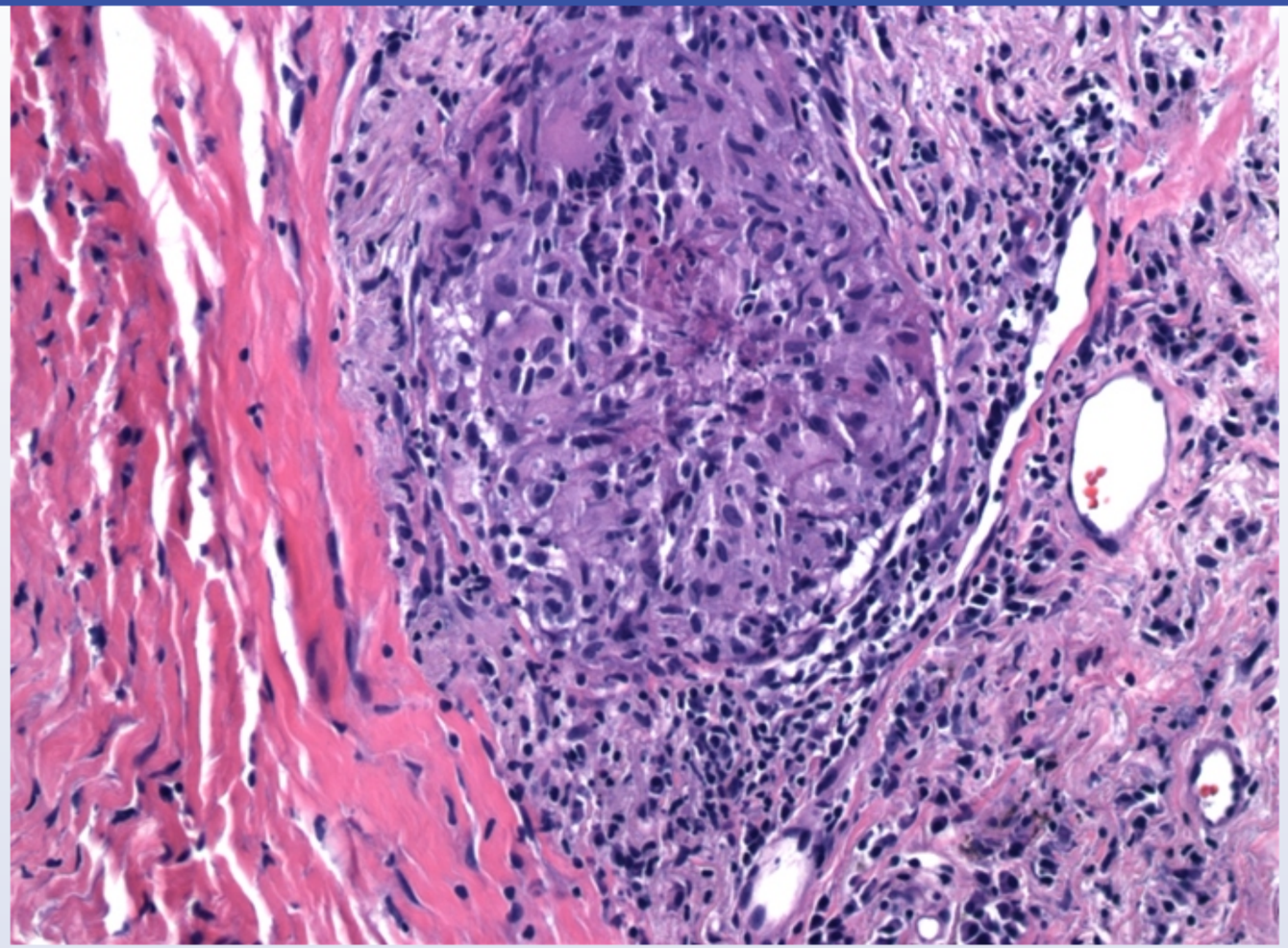

This patient most likely suffers from which of the following disorders?

A. Acute appendicitis

B. Collagenous colitis

Block Time Remaining: 00:00:51
TUTOR

9 | Feedback | Suspend | End Block

Settings

1
2
3
4
5
6
7
8
9
10
11
12
13
14
15
16
17
18
19
20
21
22
23
24
25
26
27
28
29
30

Item 19 of 40
Question Id: 405

Mark | Previous | Next | Full Screen | Tutorial | Lab Values | Notes | Calculator | Reverse Color | Text Zoom | Settings

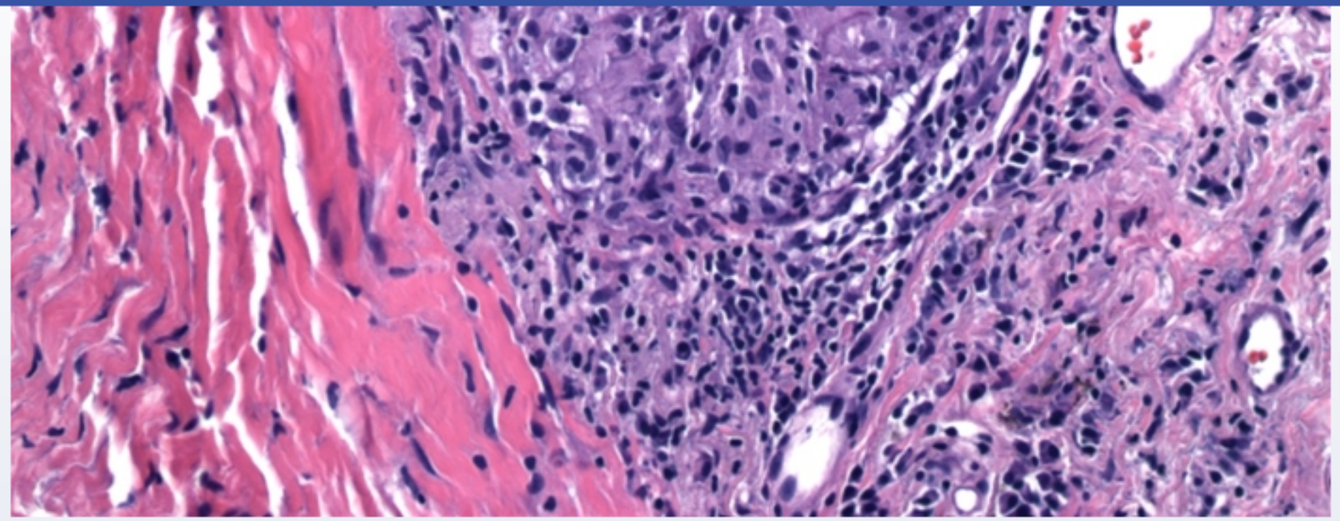

This patient most likely suffers from which of the following disorders?

- A. Acute appendicitis
- B. Collagenous colitis
- C. Crohn disease
- D. Ischemic colitis
- E. Pseudomembranous colitis
- F. Ulcerative colitis

Submit

Block Time Remaining: 00:00:53
TUTOR

9 | Feedback | Suspend | End Block

Settings

1 2 3 4 5 6 7 8 9 10 11 12 13 14 15 16 17 18 19 20 21 22 23 24 25 26 27 28 29 30

Item 19 of 40
Question Id: 405

Mark | Previous | Next | Full Screen | Tutorial | Lab Values | Notes | Calculator | Reverse Color | Text Zoom | Settings

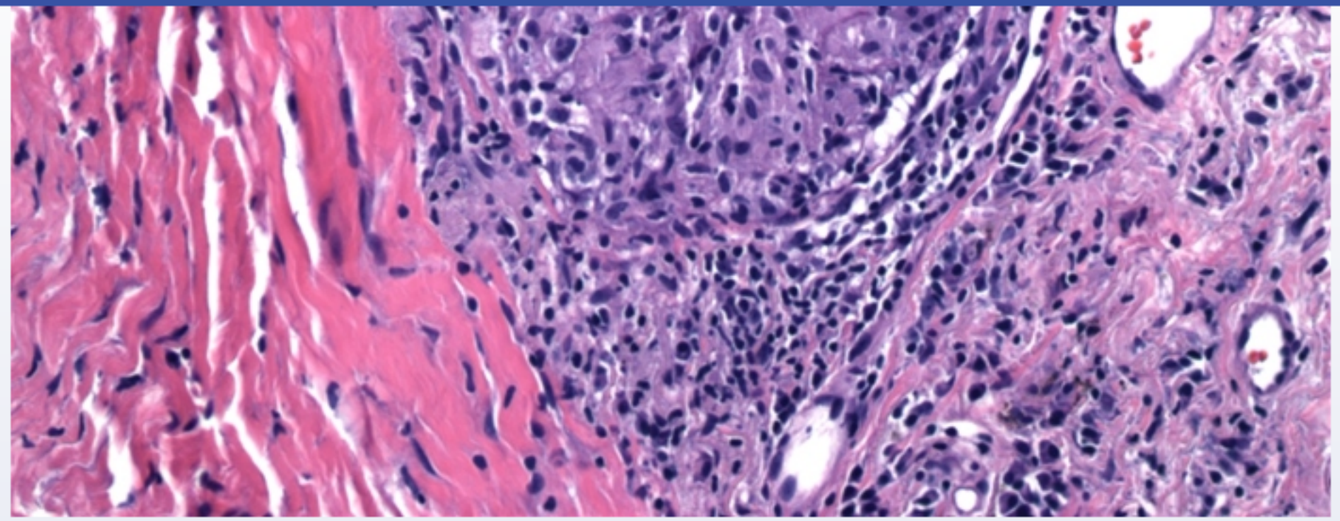

This patient most likely suffers from which of the following disorders?

- A. Acute appendicitis (0%)
- B. Collagenous colitis (2%)
- ✓ C. Crohn disease (75%)
- D. Ischemic colitis (1%)
- E. Pseudomembranous colitis (1%)
- F. Ulcerative colitis (18%)

Omitted
Correct answer

75%
Answered correctly

06 secs
Time Spent

04/03/2020
Last Updated

Block Time Remaining: 00:00:54
TUTOR

9 | Feedback | Suspend | End Block

Noncaseating granuloma

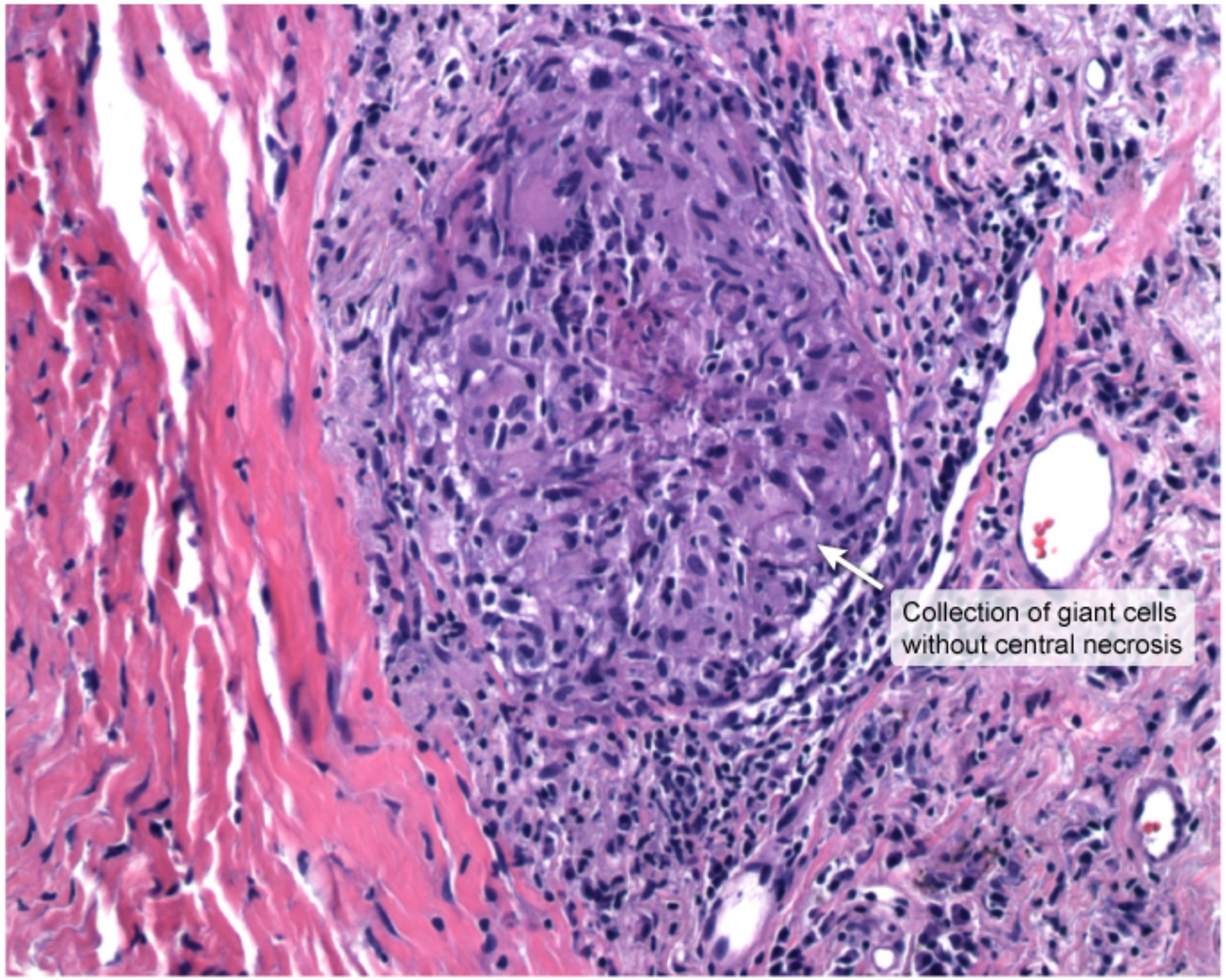

©UWorld

©UWorld

This younger patient with abdominal pain, heme-positive stool, and **noncaseating granulomas** (NCGs, pictured above) on microscopy has **Crohn disease** (CD). CD is an inflammatory bowel disease that can cause patchy inflammation throughout the gastrointestinal tract, interspersed with areas of normal bowel (skip lesions).

NCGs are often seen in CD and are considered a hallmark of the disease. NCGs are characterized by an accumulation of epithelioid macrophages that frequently form multinucleated giant cells without central necrosis (noncaseating), surrounded by a cuff of lymphocytes. Granulomas are formed in an attempt to wall off an offending agent; in the case of CD this is likely due to an unregulated immune response to gut flora or self-antigens. They can be found in any layer of the intestinal wall, and may also be present in other tissues such as the lymph nodes and skin. Other characteristic histopathologic findings in CD include inflammation involving the entire thickness of the intestinal wall (**transmural inflammation**), distortion of normal mucosal architecture, and Paneth cell metaplasia.

(Choice A) Acute appendicitis presents with periumbilical or right lower quadrant pain and fever. Microscopy shows a dense neutrophilic infiltrate and necrosis.

(Choice B) Collagenous (microscopic) colitis typically presents with frequent diarrhea in older women and histology demonstrates thickening of the subepithelial collagen band.

(Choice D) Ischemic colitis is most common in older patients and presents with abdominal pain and bleeding; microscopy shows necrosis, thrombus formation, and hemorrhage.

(Choice E) Pseudomembranous colitis is due to *Clostridium difficile* infection and presents with watery diarrhea, abdominal pain, and fever. Microscopy shows mucopurulent exudates composed of fibrin, bacteria, and neutrophils.

(Choice F) Ulcerative colitis is another cause of inflammatory bowel disease; histology demonstrates a continuous superficial inflammation affecting the mucosa and submucosa with crypt abscesses (neutrophil collections within glandular lumen) and crypt atrophy. Granulomas do not occur.

Educational objective:
Noncaseating granulomas are a hallmark of Crohn disease and can help distinguish it from ulcerative colitis, which does not form granulomas. Histopathology in Crohn disease also demonstrates transmural inflammation, distortion of the normal architecture, and Paneth cell metaplasia.

1 2 3 4 5 6 7 8 9 10 11 12 13 14 15 16 17 18 19 20 21 22 23 24 25 26 27 28 29 30

©UWorld

This younger patient with abdominal pain, heme-positive stool, and **noncaseating g**
Crohn disease (CD). CD is an inflammatory bowel disease that can cause patchy i
with areas of normal bowel (skip lesions).

NCGs are often seen in CD and are considered a hallmark of the disease. NCGs ar
macrophages that frequently form multinucleated giant cells without central necrosis
Granulomas are formed in an attempt to wall off an offending agent; in the case of C
flora or self-antigens. They can be found in any layer of the intestinal wall, and may
skin. Other characteristic histopathologic findings in CD include inflammation involv
inflammation), distortion of normal mucosal architecture, and Paneth cell metaplasi

(Choice A) Acute appendicitis presents with periumbilical or right lower quadrant pa
and necrosis.

(Choice B) Collagenous (microscopic) colitis typically presents with frequent diarrh
the subepithelial collagen band.

(Choice D) Ischemic colitis is most common in older patients and presents with abd
thrombus formation, and hemorrhage.

(Choice E) Pseudomembranous colitis is due to *Clostridium difficile* infection and p
Microscopy shows mucopurulent exudates composed of fibrin, bacteria, and neutrop

(Choice F) Ulcerative colitis is another cause of inflammatory bowel disease; histol
affecting the mucosa and submucosa with crypt abscesses (neutrophil collections w
occur.

Educational objective:
Noncaseating granulomas are a hallmark of Crohn disease and can help distinguish

Exhibit Display

***Myobacterium tuberculosis* lympha**

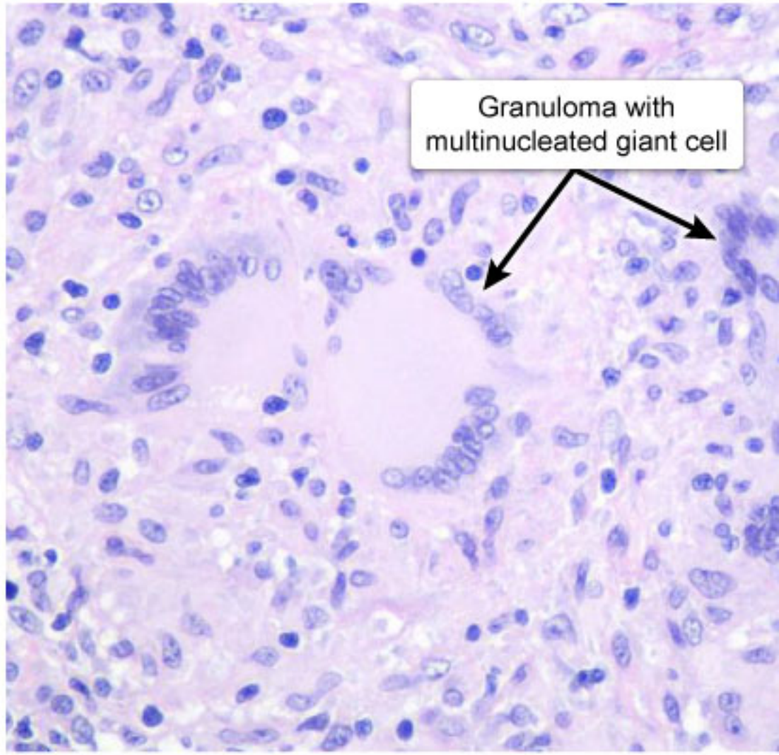

©UWorld

Zoom In | Zoom Out | Reset | Add To New

1 2 3 4 5 6 7 8 9 10 11 12 13 14 15 16 17 18 19 20 21 22 23 24 25 26 27 28 29 30

©UWorld

This younger patient with abdominal pain, heme positive stool, and noncaseating granulomas (NCGs, pictured above) on microscopy has
Crohn disea
with areas of

NCGs are of
macrophage
Granulomas
flora or self-a
skin. Other
inflammatio

(Choice A)
and necrosis

(Choice B)
the subepith

(Choice D)
thrombus for

(Choice E)
Microscopy s

(Choice F)
affecting the
occur.

Educational
Noncaseatin
Histopathola

Exhibit Display

Myobacterium tuberculosis lymphadenitis

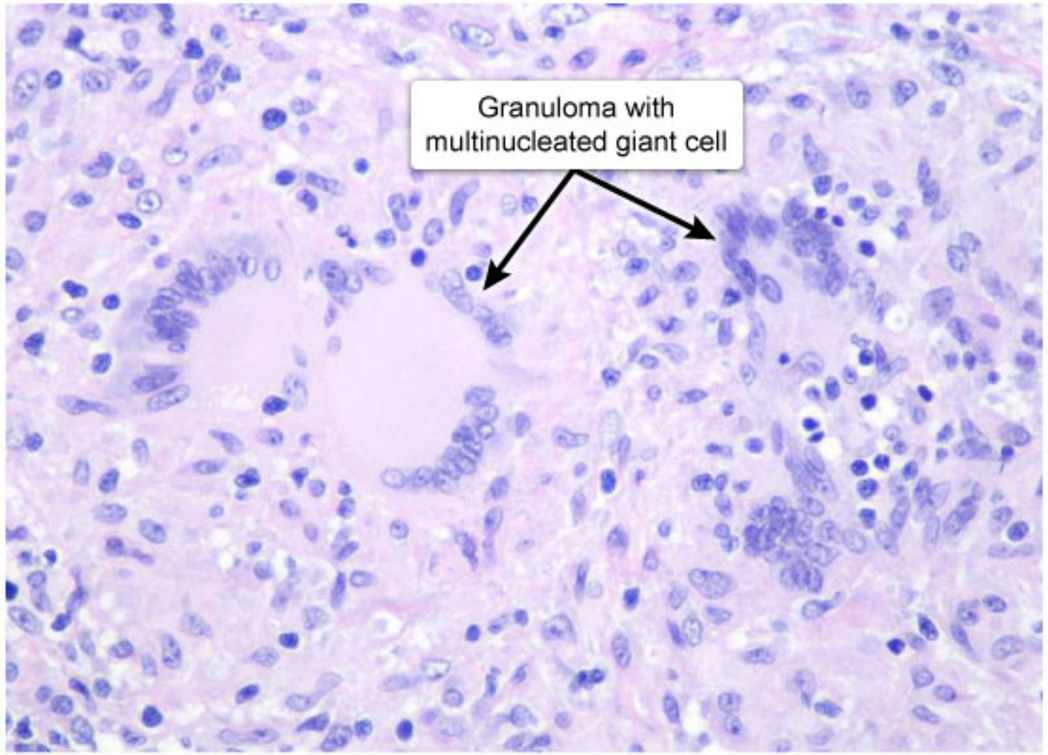

©UWorld

Zoom In | Zoom Out | Reset | Add To New Card | Existing Card

Settings

1 2 3 4 5 6 7 8 9 10 11 12 13 14 15 16 17 18 19 20 21 22 23 24 25 26 27 28 29 30

Item 19 of 40
Question Id: 405

Mark | Previous | Next | Full Screen | Tutorial | Lab Values | Notes | Calculator | Reverse Color | Text Zoom | Settings

©UWorld

Exhibit Display

Acute appendicitis Acute appendicitis

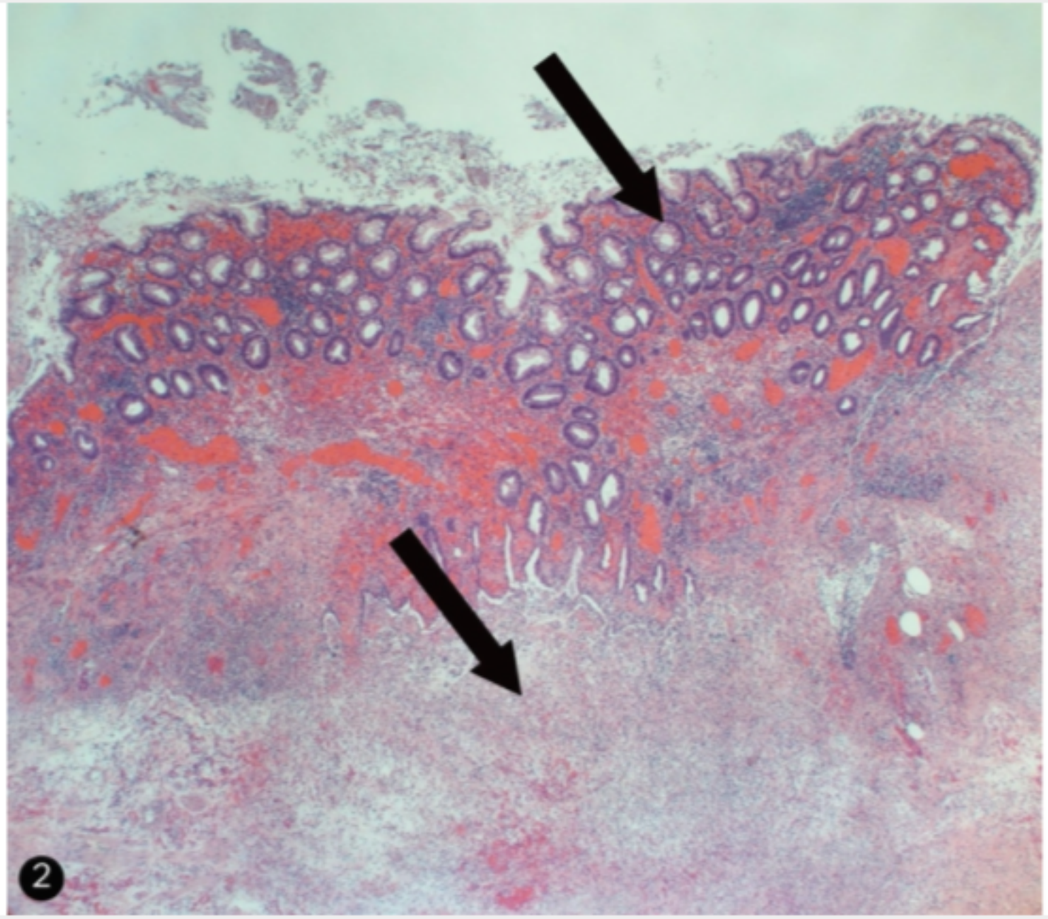

Zoom In | Zoom Out | Reset | Add To New Card | Existing Card

Histopathology in Crohn disease also demonstrates transmural inflammation, distortion of the normal architecture, and Paneth cell metaplasia.

Block Time Remaining: 00:00:54
TUTOR

9 | Feedback | Suspend | End Block

Settings

1 2 3 4 5 6 7 8 9 10 11 12 13 14 15 16 17 18 19 20 21 22 23 24 25 26 27 28 29 30

Item 19 of 40
Question Id: 405

Mark | Previous | Next | Full Screen | Tutorial | Lab Values | Notes | Calculator | Reverse Color | Text Zoom | Settings

©UWorld

Exhibit Display

Acute appendicitis Acute appendicitis

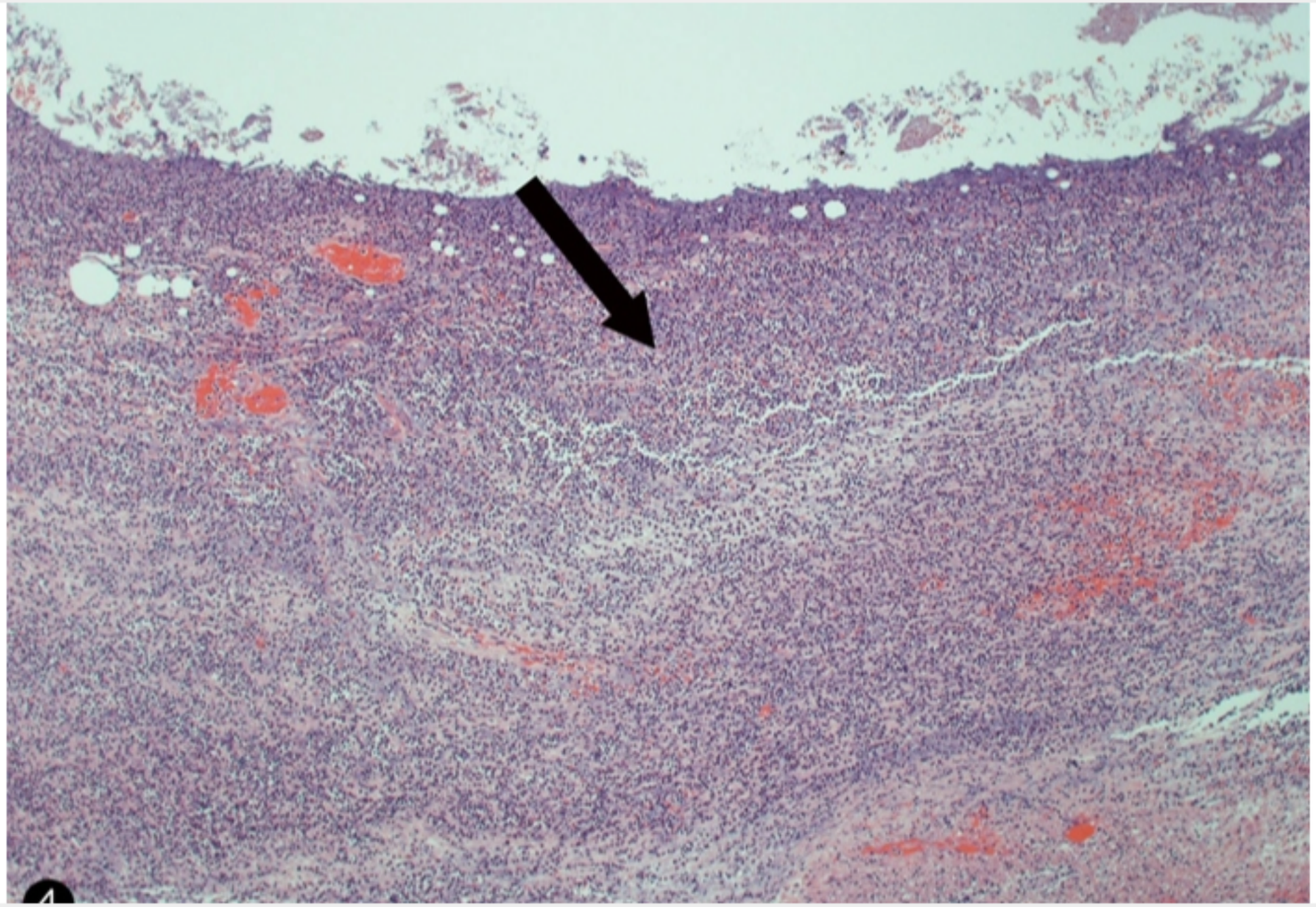

Zoom In | Zoom Out | Reset | Add To New Card | Existing Card

Histopathology in Crohn disease also demonstrates transmural inflammation, distortion of the normal architecture, and Paneth cell metaplasia.

Block Time Remaining: 00:00:54
TUTOR

9 | Feedback | Suspend | End Block

Settings

1 2 3 4 5 6 7 8 9 10 11 12 13 14 15 16 17 18 19 20 21 22 23 24 25 26 27 28 29 30

Item 19 of 40
Question Id: 405

Mark | Previous | Next | Full Screen | Tutorial | Lab Values | Notes | Calculator | Reverse Color | Text Zoom | Settings

©UWorld

Exhibit Display

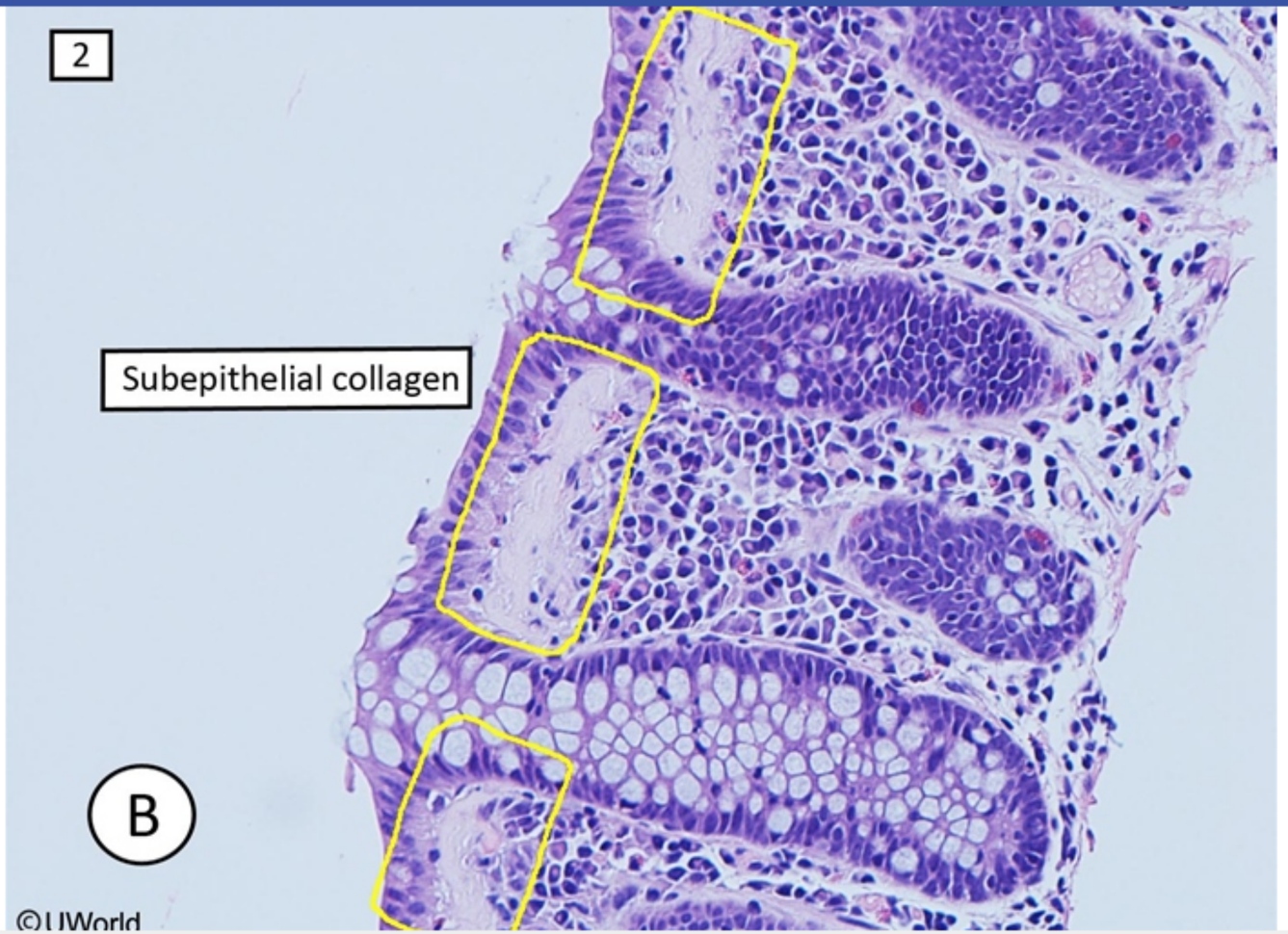

Zoom In | Zoom Out | Reset | Add To New Card | Existing Card

Histopathology in Crohn disease also demonstrates transmural inflammation, distortion of the normal architecture, and Paneth cell metaplasia.

Block Time Remaining: 00:00:54
TUTOR

9 | Feedback | Suspend | End Block

©UWorld

Exhibit Display

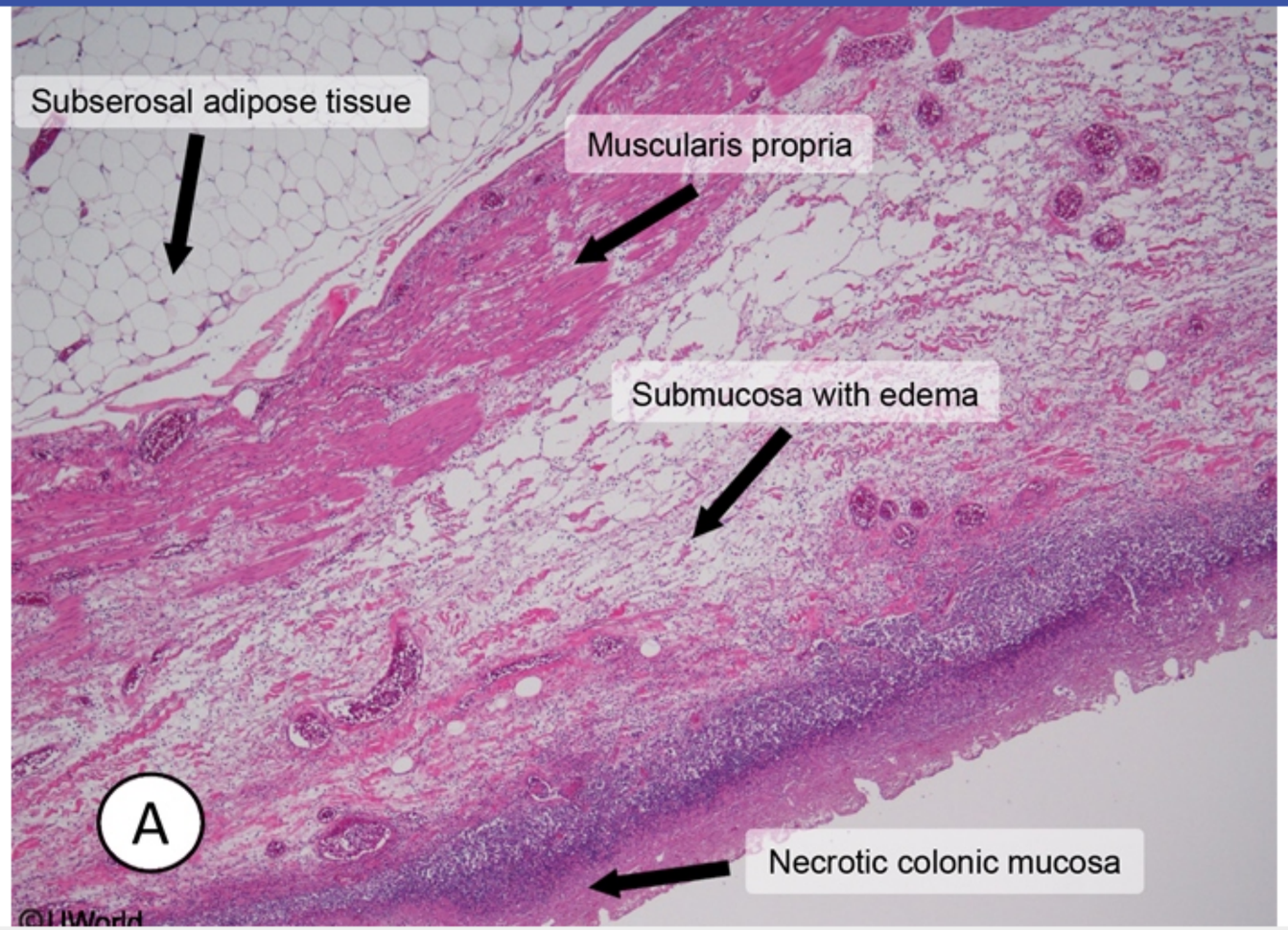

Zoom In | Zoom Out | Reset | Add To New Card | Existing Card

Histopathology in Crohn disease also demonstrates transmural inflammation, distortion of the normal architecture, and Paneth cell metaplasia.

©UWorld

Exhibit Display

Pseudomembranous colitis

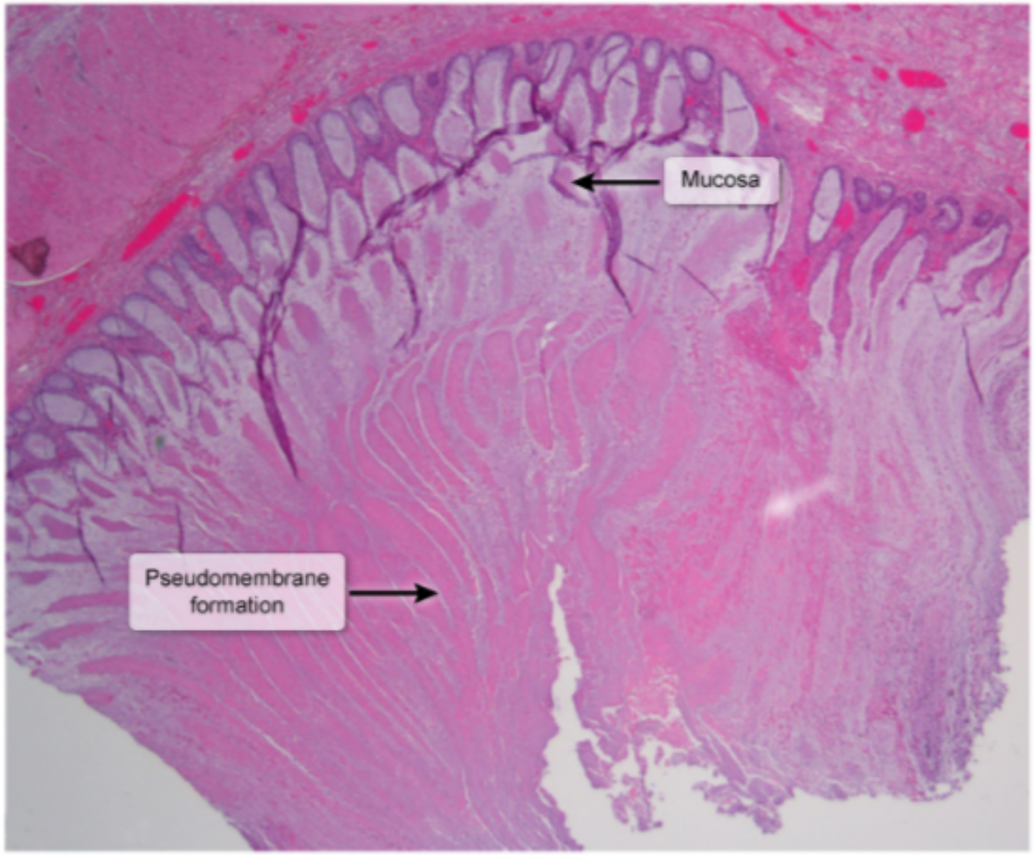

©UWorld

Zoom In | Zoom Out | Reset | Add To New Card | Existing Card

Histopathology in Crohn disease also demonstrates transmural inflammation, distortion of the normal architecture, and Paneth cell metaplasia.

©UWorld

Exhibit Display

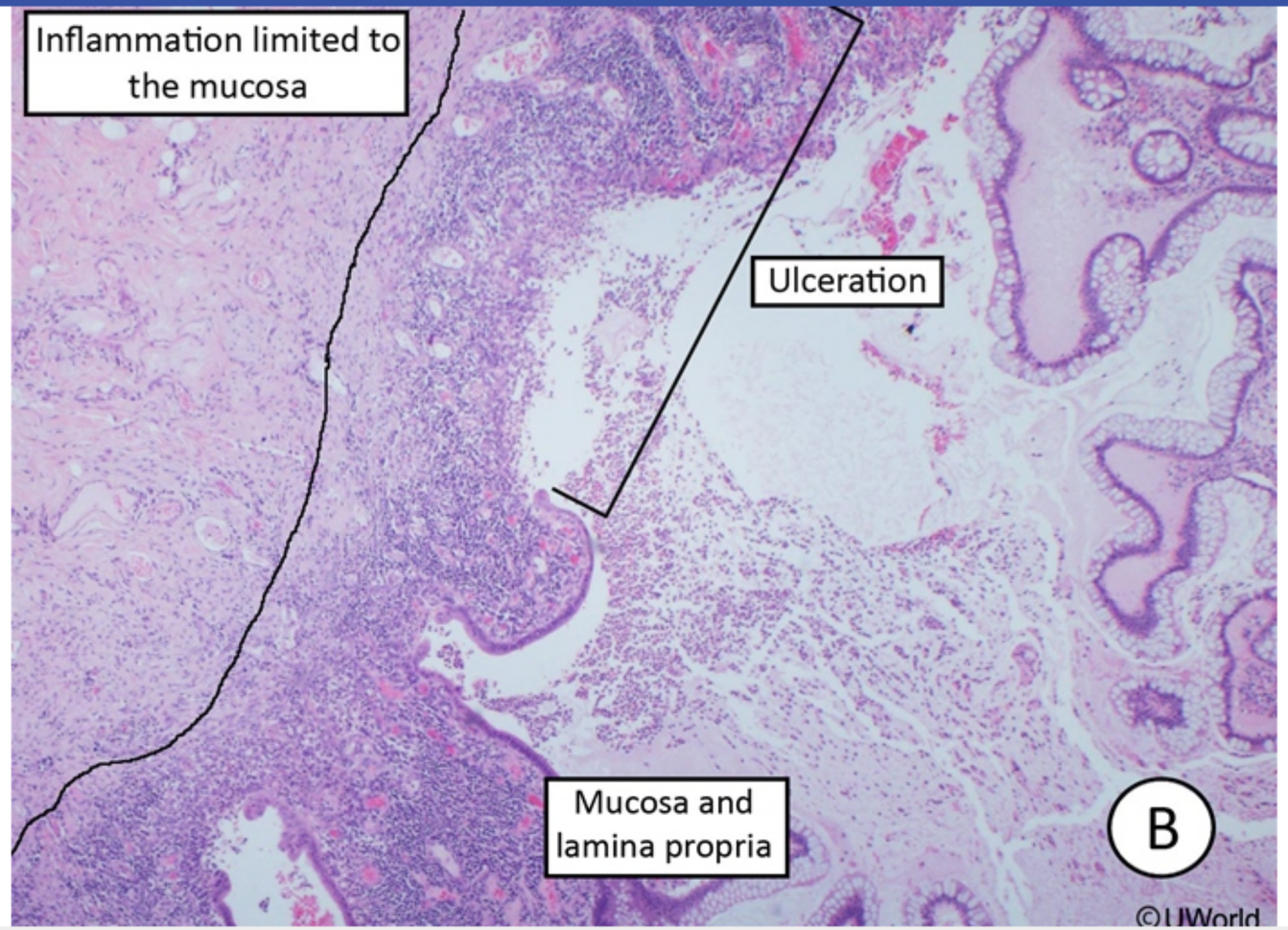

Zoom In | Zoom Out | Reset | Add To New Card | Existing Card

Histopathology in Crohn disease also demonstrates transmural inflammation, distortion of the normal architecture, and Paneth cell metaplasia.

macrophages that frequently form multinucleated giant cells without central necrosis (noncaseating), surrounded by a cuff of lymphocytes. Granulomas are formed in an attempt to wall off an offending agent; in the case of CD this is likely due to an unregulated immune response to gut flora or self-antigens. They can be found in any layer of the intestinal wall, and may also be present in other tissues such as the lymph nodes and skin. Other characteristic histopathologic findings in CD include inflammation involving the entire thickness of the intestinal wall (**transmural inflammation**), distortion of normal mucosal architecture, and Paneth cell metaplasia.

(Choice A) Acute appendicitis presents with periumbilical or right lower quadrant pain and fever. Microscopy shows a dense neutrophilic infiltrate and necrosis.

(Choice B) Collagenous (microscopic) colitis typically presents with frequent diarrhea in older women and histology demonstrates thickening of the subepithelial collagen band.

(Choice D) Ischemic colitis is most common in older patients and presents with abdominal pain and bleeding; microscopy shows necrosis, thrombus formation, and hemorrhage.

(Choice E) Pseudomembranous colitis is due to *Clostridium difficile* infection and presents with watery diarrhea, abdominal pain, and fever. Microscopy shows mucopurulent exudates composed of fibrin, bacteria, and neutrophils.

(Choice F) Ulcerative colitis is another cause of inflammatory bowel disease; histology demonstrates a continuous superficial inflammation affecting the mucosa and submucosa with crypt abscesses (neutrophil collections within glandular lumen) and crypt atrophy. Granulomas do not occur.

Educational objective:
Noncaseating granulomas are a hallmark of Crohn disease and can help distinguish it from ulcerative colitis, which does not form granulomas. Histopathology in Crohn disease also demonstrates transmural inflammation, distortion of the normal architecture, and Paneth cell metaplasia.

Pathology	Gastrointestinal & Nutrition	Inflammatory bowel disease
Subject	System	Topic

Copyright © UWorld. All rights reserved.

1 2 3 4 5 6 7 8 9 10 11 12 13 14 15 16 17 18 19 20 21 22 23 24 25 26 27 28 29 30

A 32-year-old man comes to the office due to intermittent dysphagia for solids and liquids. He has no significant past medical history and does not use tobacco, alcohol, or illicit drugs. His father has a history of esophageal squamous cell carcinoma. Physical examination is unremarkable. The patient undergoes an esophageal manometric study that demonstrates periodic, simultaneous, and non-peristaltic contractions of large amplitude and long duration. Which of the following is the most likely pathogenesis of this patient's esophageal condition?

A. Disruption of the gastroesophageal junction

B. Eosinophil infiltration

C. Impaired neural inhibition

D. Mucosal outpouching through a muscular wall defect

E. Obstruction from unregulated cell growth

F. Smooth muscle atrophy and gut wall fibrosis

Submit

A 32-year-old man comes to the office due to intermittent dysphagia for solids and liquids. He has no significant past medical history and does not use tobacco, alcohol, or illicit drugs. His father has a history of esophageal squamous cell carcinoma. Physical examination is unremarkable. The patient undergoes an esophageal manometric study that demonstrates periodic, simultaneous, and non-peristaltic contractions of large amplitude and long duration. Which of the following is the most likely pathogenesis of this patient's esophageal condition?

- A. Disruption of the gastroesophageal junction (6%)
- B. Eosinophil infiltration (2%)
- ✓ C. Impaired neural inhibition (77%)
- D. Mucosal outpouching through a muscular wall defect (3%)
- E. Obstruction from unregulated cell growth (3%)
- F. Smooth muscle atrophy and gut wall fibrosis (7%)

Omitted
Correct answer
C

77%
Answered correctly

02 secs
Time Spent

01/13/2020
Last Updated

Explanation

Diffuse esophageal spasm (DES) manometry

Normal (sequential contractions)	DES (simultaneous contractions)

Diffuse esophageal spasm (DES) manometry

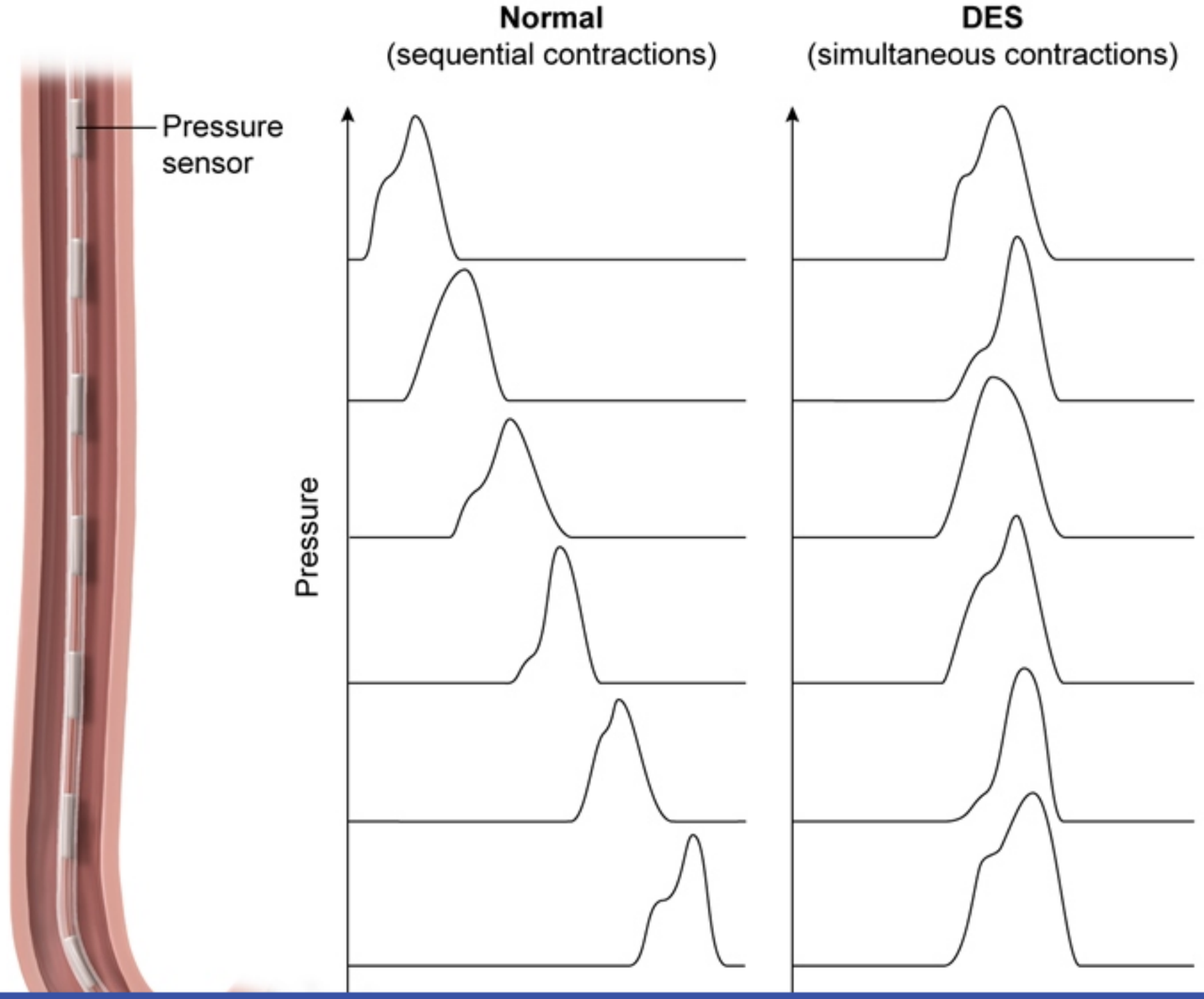

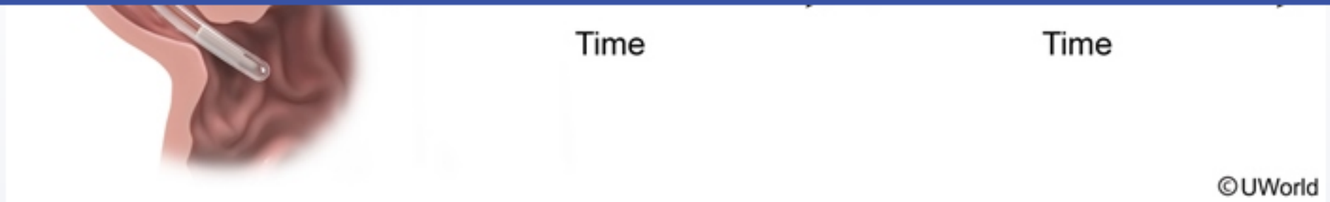

This patient's presentation is consistent with **diffuse esophageal spasm** (DES). Esophageal contractions are normally stimulated by esophageal distension from a food bolus. The contractions originate above the site of distension and propel the bolus downward in a coordinated fashion. In DES, several segments of the esophagus contract inappropriately at the same time, which appears as disorganized **non-peristaltic contractions** on esophageal manometry and "corkscrew" esophagus on barium esophagogram. Because the food bolus is inefficiently propelled toward the stomach, patients typically present with intermittent **solid/liquid dysphagia, chest pain**, heartburn, and food regurgitation. The pathogenesis of DES likely involves **impaired inhibitory neurotransmission** within the esophageal myenteric plexus.

(Choice A) Patients with sliding hiatal hernia often develop symptoms of gastroesophageal reflux (eg, heartburn, regurgitation, dysphagia) due to anatomic disruption of the gastroesophageal junction and impaired esophageal acid clearance. However, esophageal manometry is typically normal.

(Choice B) Eosinophilic esophagitis typically presents in atopic patients with solid food dysphagia and/or food impaction. Findings on esophageal manometry are nonspecific.

(Choice D) Zenker's diverticulum is a mucosal outpouching through an area of muscle weakness located in the wall of the hypopharynx (Killian triangle). The condition typically presents in elderly men with dysphagia, foul breath (halitosis), and food regurgitation.

(Choice E) Esophageal cancer typically presents with progressive solid food dysphagia and unintentional weight loss. Risk factors for squamous cell carcinoma include alcohol and tobacco use, whereas risk factors for adenocarcinoma include Barrett's esophagus, gastroesophageal reflux disease, smoking, and obesity.

(Choice F) Systemic sclerosis may involve the lower two-thirds of the esophagus, resulting in smooth muscle atrophy and gut wall fibrosis. Patients can develop dysphagia with acid reflux; however, manometry typically shows absent peristaltic waves with decreased lower esophageal sphincter tone.

anatomic disruption of the gastroesophageal junction and impaired esophageal acid clearance. However, esophageal manometry is typically normal.

(Choice B) Eosinophilic esophagitis typically presents in atopic patients with solid food dysphagia and/or food impaction. Findings on esophageal manometry are nonspecific.

(Choice D) Zenker's diverticulum is a mucosal outpouching through an area of muscle weakness located in the wall of the hypopharynx (Killian triangle). The condition typically presents in elderly men with dysphagia, foul breath (halitosis), and food regurgitation.

(Choice E) Esophageal cancer typically presents with progressive solid food dysphagia and unintentional weight loss. Risk factors for squamous cell carcinoma include alcohol and tobacco use, whereas risk factors for adenocarcinoma include Barrett's esophagus, gastroesophageal reflux disease, smoking, and obesity.

(Choice F) Systemic sclerosis may involve the lower two-thirds of the esophagus, resulting in smooth muscle atrophy and gut wall fibrosis. Patients can develop dysphagia with acid reflux; however, manometry typically shows absent peristaltic waves with decreased lower esophageal sphincter tone.

Educational objective:
Diffuse esophageal spasm is characterized by periodic, simultaneous, and non-peristaltic contractions of the esophagus due to impaired inhibitory innervation within the esophageal myenteric plexus. Patients typically present with liquid/solid dysphagia and chest pain due to inefficient propulsion of food into the stomach.

References

- Distal esophageal spasm: an update.
- Distal esophageal spasm.

Pathology	Gastrointestinal & Nutrition	Diffuse esophageal spasm
Subject	System	Topic

Copyright © UWorld. All rights reserved.

A 40-year-old woman comes to the office due to recurrent episodes of postprandial abdominal pain. The pain is in the right upper quadrant and is associated with nausea. The patient has no fever, jaundice, or loss of appetite. Other medical conditions include obstructive sleep apnea and obesity. The patient takes no medication. She has never had any surgeries. She does not use tobacco, alcohol, or illicit drugs. The patient is afebrile. Blood pressure is 140/90 mm Hg. BMI is 38 kg/m^2. Examination shows tenderness in the right upper quadrant. Abdominal ultrasound demonstrates multiple gallstones. A gross specimen obtained from laparoscopic cholecystectomy is shown in the image below:

Which of the following is the most likely mechanism responsible for gallstone formation in this patient?

- A. Altered enterohepatic cycling of bilirubin
- B. Decreased bile acid synthesis
- C. Delayed gallbladder emptying
- D. Increased cholesterol synthesis
- E. Increased efflux of bilirubin into bile

Submit

Which of the following is the most likely mechanism responsible for gallstone formation in this patient?

- A. Altered enterohepatic cycling of bilirubin (1%)
- B. Decreased bile acid synthesis (10%)
- C. Delayed gallbladder emptying (14%)
- ✓ D. Increased cholesterol synthesis (72%)
- E. Increased efflux of bilirubin into bile (1%)

Omitted
Correct answer

72%
Answered correctly

03 secs
Time Spent

04/17/2020
Last Updated

Explanation

Bile is stored and concentrated within the gallbladder and is involved in digestion and absorption of dietary fats and removal of waste products (eg, bilirubin, cholesterol) for excretion in feces. Gallstones usually occur when one such waste product supersaturates the bile, resulting in precipitation and eventual stone formation.

In the United States, most gallstones are due to the **supersaturation of cholesterol**, which usually precipitates out of bile with calcium salts and mucin, forming **white or yellow cholesterol stones**, as seen in this patient. Cholesterol stone formation occurs due to the following:

- **Increased cholesterol synthesis:** Hypercholesterolemia, caused by diet, genetics, diabetes mellitus, medications (eg, oral contraceptives), or **obesity** (increased HMG-CoA reductase activity), results in hypersecretion of cholesterol into the bile.
- **Gallbladder hypomotility:** Pregnancy, medications (eg, somatostatin), prolonged fasting, parenteral nutrition, and spinal cord injury lead to gallbladder stasis, which promotes excessive water resorption from bile and concentration of cholesterol.
- **Increased calcium or mucin concentration:** Rapid weight loss (eg, gastric bypass) promotes increased calcium and mucin concentrations in the bile, which trap cholesterol crystals and promote stone formation.
- **Decreased bile acid synthesis or recirculation:** Fibrates (eg, fenofibrate) inhibit bile acid synthesis, increasing cholesterol concentration within the bile. Decreased bile acid resorption at the ileum (eg, due to Crohn disease) also promotes cholesterol concentration.

This **obese** patient has no other risk factors, making **increased cholesterol synthesis** the most likely etiology of her gallstones.

(Choices A and E) Increased enterohepatic cycling of bilirubin occurs with ileal disease (eg, Crohn disease), as the loss of bile acids promotes reabsorption of unconjugated bilirubin. Increased efflux of bilirubin into bile occurs with hyperbilirubinemia from chronic hemolysis (eg, sickle cell disease). Because of high bilirubin concentrations, these mechanisms promote the formation of black pigment stones, not cholesterol stones.

(Choices B and C) Although both decreased bile acid synthesis (eg, due to fibrate medications) and gallbladder hypomotility (eg, due to pregnancy, prolonged fasting, or spinal cord injury) promote the formation of cholesterol gallstones, this patient does not have risk factors for either etiology.

Educational objective:

- **Increased calcium or mucin concentration:** Rapid weight loss (eg, gastric bypass) promotes increased calcium and mucin concentrations in the bile, which trap cholesterol crystals and promote stone formation.
- **Decreased bile acid synthesis or recirculation:** Fibrates (eg, fenofibrate) inhibit bile acid synthesis, increasing cholesterol concentration within the bile. Decreased bile acid resorption at the ileum (eg, due to Crohn disease) also promotes cholesterol concentration.

This **obese** patient has no other risk factors, making **increased cholesterol synthesis** the most likely etiology of her gallstones.

(Choices A and E) Increased enterohepatic cycling of bilirubin occurs with ileal disease (eg, Crohn disease), as the loss of bile acids promotes reabsorption of unconjugated bilirubin. Increased efflux of bilirubin into bile occurs with hyperbilirubinemia from chronic hemolysis (eg, sickle cell disease). Because of high bilirubin concentrations, these mechanisms promote the formation of black pigment stones, not cholesterol stones.

(Choices B and C) Although both decreased bile acid synthesis (eg, due to fibrate medications) and gallbladder hypomotility (eg, due to pregnancy, prolonged fasting, or spinal cord injury) promote the formation of cholesterol gallstones, this patient does not have risk factors for either etiology.

Educational objective:
Most gallstones occur due to the supersaturation of cholesterol, which precipitates out of bile with mucin and calcium salts to form white or yellow cholesterol stones. Factors that promote the formation of cholesterol stones include increased cholesterol synthesis, gallbladder hypomotility, increased calcium or mucin concentration, and decreased bile acid synthesis or recirculation.

References

- Mechanism of cholesterol gallstone formation.
- Gallstones.

Pathology	Gastrointestinal & Nutrition	Gallstone disease
Subject	System	Topic

Copyright © UWorld. All rights reserved.

A 65-year-old woman is being evaluated following an episode of syncope that occurred after prolonged standing. She used to exercise in the local gym but has become easily fatigued recently. The patient has had occasional dark stools. She has lost 5 kg (11 lb) in the past few weeks due to "poor appetite." She does not smoke, drink alcohol, or use illicit drugs. Family history is negative for cancers. Vital signs reveal mild orthostatic hypotension. Physical examination is unremarkable, but stool is positive for occult blood. Colonoscopy reveals 2 polyps. The pathology report shows advanced adenomatous changes in one polyp and adenocarcinoma in the other. A mutation in which of the following genes is most likely responsible for the transformation from advanced adenoma to adenocarcinoma in this patient?

- A. *BRCA1*
- B. *CCND1*
- C. *KRAS*
- D. *NMYC*
- E. *TP53*
- F. *WT1*

Submit

1 2 3 4 5 6 7 8 9 10 11 12 13 14 15 16 17 18 19 20 21 22 23 24 25 26 27 28 29 30

A 65-year-old woman is being evaluated following an episode of syncope that occurred after prolonged standing. She used to exercise in the local gym but has become easily fatigued recently. The patient has had occasional dark stools. She has lost 5 kg (11 lb) in the past few weeks due to "poor appetite." She does not smoke, drink alcohol, or use illicit drugs. Family history is negative for cancers. Vital signs reveal mild orthostatic hypotension. Physical examination is unremarkable, but stool is positive for occult blood. Colonoscopy reveals 2 polyps. The pathology report shows advanced adenomatous changes in one polyp and adenocarcinoma in the other. A mutation in which of the following genes is most likely responsible for the transformation from advanced adenoma to adenocarcinoma in this patient?

- A. *BRCA1* (1%)
- B. *CCND1* (2%)
- C. *KRAS* (31%)
- D. *NMYC* (1%)
- ✓ E. *TP53* (62%)
- F. *WT1* (0%)

Omitted
Correct answer
E

62%
Answered correctly

01 sec
Time Spent

01/13/2020
Last Updated

Explanation

Adenoma to carcinoma sequence

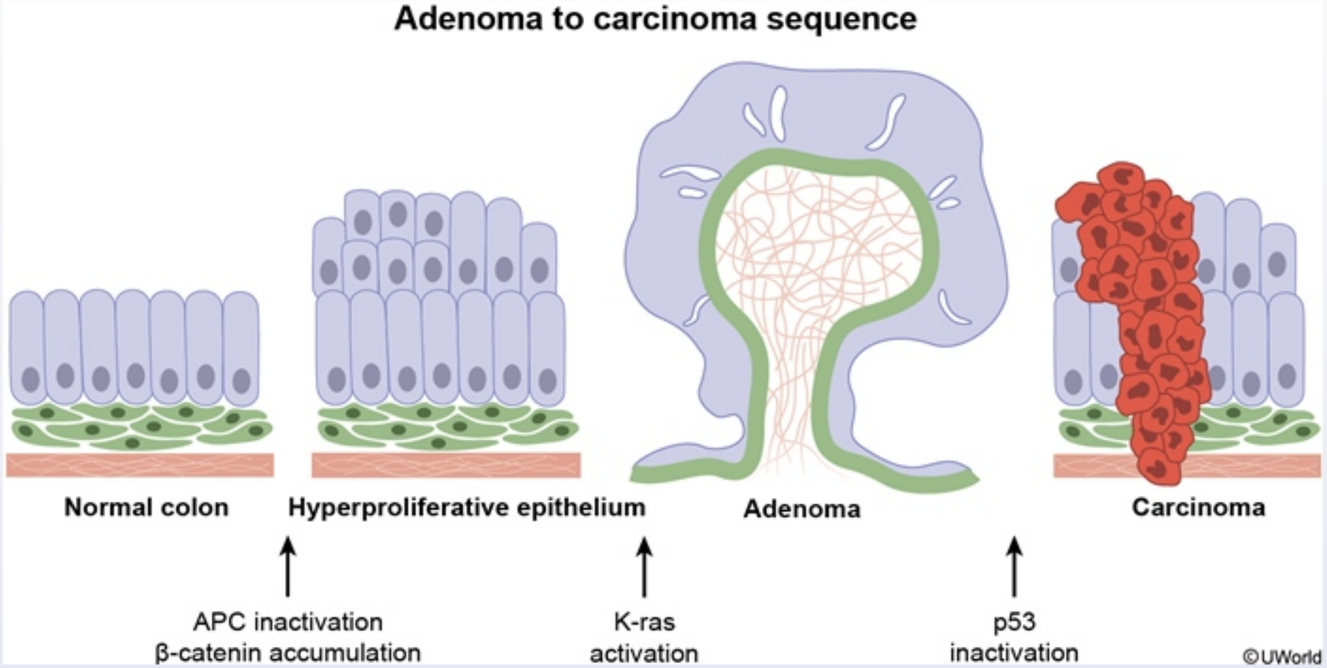

Colon cancer is one of the most common malignancies in the United States. Its incidence increases with age, and it affects men and women equally. A diet high in fat and carbohydrates and low in fiber increases the risk. Certain diseases (eg, inflammatory bowel disease) and genetic factors also play an important role.

Most cases of **sporadic** colon adenocarcinoma arise from preexisting adenomatous **polyps**. The transformation of normal mucosal cells into malignant ones is caused by a series of gene mutations, the **adenoma to carcinoma sequence**:

1. **Progression from normal mucosa to a small adenomatous polyp (adenoma)**. The initial appearance of small adenomatous polyps is attributed to mutation of the *APC* tumor suppressor gene. *APC* is located on chromosome 5, and its mutation leads to β-catenin accumulation and uncontrolled cell proliferation.
2. **Increase in the size of the adenoma**. Mutation of the *KRAS* protooncogene is thought to facilitate this step by leading to a protein that also stimulates unregulated cell growth.

β-catenin accumulation | activation | inactivation

©UWorld

Colon cancer is one of the most common malignancies in the United States. Its incidence increases with age, and it affects men and women equally. A diet high in fat and carbohydrates and low in fiber increases the risk. Certain diseases (eg, inflammatory bowel disease) and genetic factors also play an important role.

Most cases of **sporadic** colon adenocarcinoma arise from preexisting adenomatous **polyps**. The transformation of normal mucosal cells into malignant ones is caused by a series of gene mutations, the **adenoma to carcinoma sequence**:

1. **Progression from normal mucosa to a small adenomatous polyp (adenoma)**. The initial appearance of small adenomatous polyps is attributed to mutation of the *APC* tumor suppressor gene. *APC* is located on chromosome 5, and its mutation leads to β-catenin accumulation and uncontrolled cell proliferation.
2. **Increase in the size of the adenoma**. Mutation of the *KRAS* protooncogene is thought to facilitate this step by leading to a protein that also stimulates unregulated cell growth.
3. **Malignant transformation** of adenoma into carcinoma requires mutation of *TP53*.

Sometimes called a "molecular policeman," ***TP53*** is an antioncogene (**tumor suppressor gene**) that codes for protein p53, which triggers apoptosis of cells with damaged DNA. A *TP53* mutation allows cells with genomic errors to enter the cell cycle. Such a mutation is considered the last "**hit**" in the adenoma to carcinoma sequence (mutations are found in most colon carcinomas but rarely in adenomas).

(Choice A) Mutations in the tumor suppressor gene *BRCA* are classically associated with breast and ovarian cancers.

(Choice B) Cyclin D is a protein (encoded by *CCND1*) that regulates cell cycle. Its overexpression is seen in breast, lung, and esophageal cancers and certain types of lymphomas.

(Choice C) *KRAS* protooncogene mutation is responsible for the increase in size of adenomatous polyps and also leads to uncontrolled cell growth. Such mutations tend to occur prior to *TP53* mutations.

(Choice D) *NMYC* is an oncogene. An increased number of copies of this gene (amplification) are seen in neuroblastoma.

(Choice F) Mutation of *WT1*, a tumor suppressor gene, leads to the development of Wilms tumor.

Educational objective:

1. **Progression from normal mucosa to a small adenomatous polyp (adenoma).** The initial appearance of small adenomatous polyps is attributed to mutation of the *APC* tumor suppressor gene. *APC* is located on chromosome 5, and its mutation leads to β-catenin accumulation and uncontrolled cell proliferation.
2. **Increase in the size of the adenoma**. Mutation of the *KRAS* protooncogene is thought to facilitate this step by leading to a protein that also stimulates unregulated cell growth.
3. **Malignant transformation** of adenoma into carcinoma requires mutation of *TP53*.

Sometimes called a "molecular policeman," ***TP53*** is an antioncogene (**tumor suppressor gene**) that codes for protein p53, which triggers apoptosis of cells with damaged DNA. A *TP53* mutation allows cells with genomic errors to enter the cell cycle. Such a mutation is considered the last "**hit**" in the adenoma to carcinoma sequence (mutations are found in most colon carcinomas but rarely in adenomas).

(Choice A) Mutations in the tumor suppressor gene *BRCA* are classically associated with breast and ovarian cancers.

(Choice B) Cyclin D is a protein (encoded by *CCND1*) that regulates cell cycle. Its overexpression is seen in breast, lung, and esophageal cancers and certain types of lymphomas.

(Choice C) *KRAS* protooncogene mutation is responsible for the increase in size of adenomatous polyps and also leads to uncontrolled cell growth. Such mutations tend to occur prior to *TP53* mutations.

(Choice D) *NMYC* is an oncogene. An increased number of copies of this gene (amplification) are seen in neuroblastoma.

(Choice F) Mutation of *WT1*, a tumor suppressor gene, leads to the development of Wilms tumor.

Educational objective:
The adenoma to carcinoma sequence is a series of gene mutations that leads to the development of colon adenocarcinoma. *TP53* tumor suppressor gene mutation is part of the final step in the sequence and leads to malignant transformation of preexisting large adenomatous polyps.

Pathology	Gastrointestinal & Nutrition	Colorectal cancer
Subject	System	Topic

Copyright © UWorld. All rights reserved.

A 55-year-old man comes to the office due to intermittent abdominal pain. He has no difficulty or pain with swallowing. The patient occasionally uses over-the-counter pain medicine for osteoarthritis of the right knee. He does not use alcohol or tobacco and has no history of cancer in the family. He works as an air traffic controller at a busy airport. Upper gastrointestinal endoscopy shows an ulcer in the distal duodenum. Fasting serum gastrin concentration is at the upper limit of normal and rises in response to intravenous secretin. This patient's condition is most likely caused by which of the following processes?

- A. Autoimmune destruction
- B. *Helicobacter pylori* infection
- C. Mucosal immune dysregulation
- D. Neoplasm
- E. Nonsteroidal anti-inflammatory drug use
- F. Stress

Submit

A 55-year-old man comes to the office due to intermittent abdominal pain. He has no difficulty or pain with swallowing. The patient occasionally uses over-the-counter pain medicine for osteoarthritis of the right knee. He does not use alcohol or tobacco and has no history of cancer in the family. He works as an air traffic controller at a busy airport. Upper gastrointestinal endoscopy shows an ulcer in the distal duodenum. Fasting serum gastrin concentration is at the upper limit of normal and rises in response to intravenous secretin. This patient's condition is most likely caused by which of the following processes?

- A. Autoimmune destruction (2%)
- B. *Helicobacter pylori* infection (29%)
- C. Mucosal immune dysregulation (2%)
- ✓ D. Neoplasm (36%)
- E. Nonsteroidal anti-inflammatory drug use (22%)
- F. Stress (7%)

Omitted
Correct answer
D

36%
Answered correctly

02 secs
Time Spent

06/02/2020
Last Updated

Explanation

Zollinger-Ellison syndrome

Settings

1
2
3
4
5
6
7
8
9
10
11
12
13
14
15
16
17
18
19
20
21
22
23
24
25
26
27
28
29
30

Item 23 of 40
Question Id: 305

Mark | Previous | Next | Full Screen | Tutorial | Lab Values | Notes | Calculator | Reverse Color | Text Zoom | Settings

Zollinger-Ellison syndrome

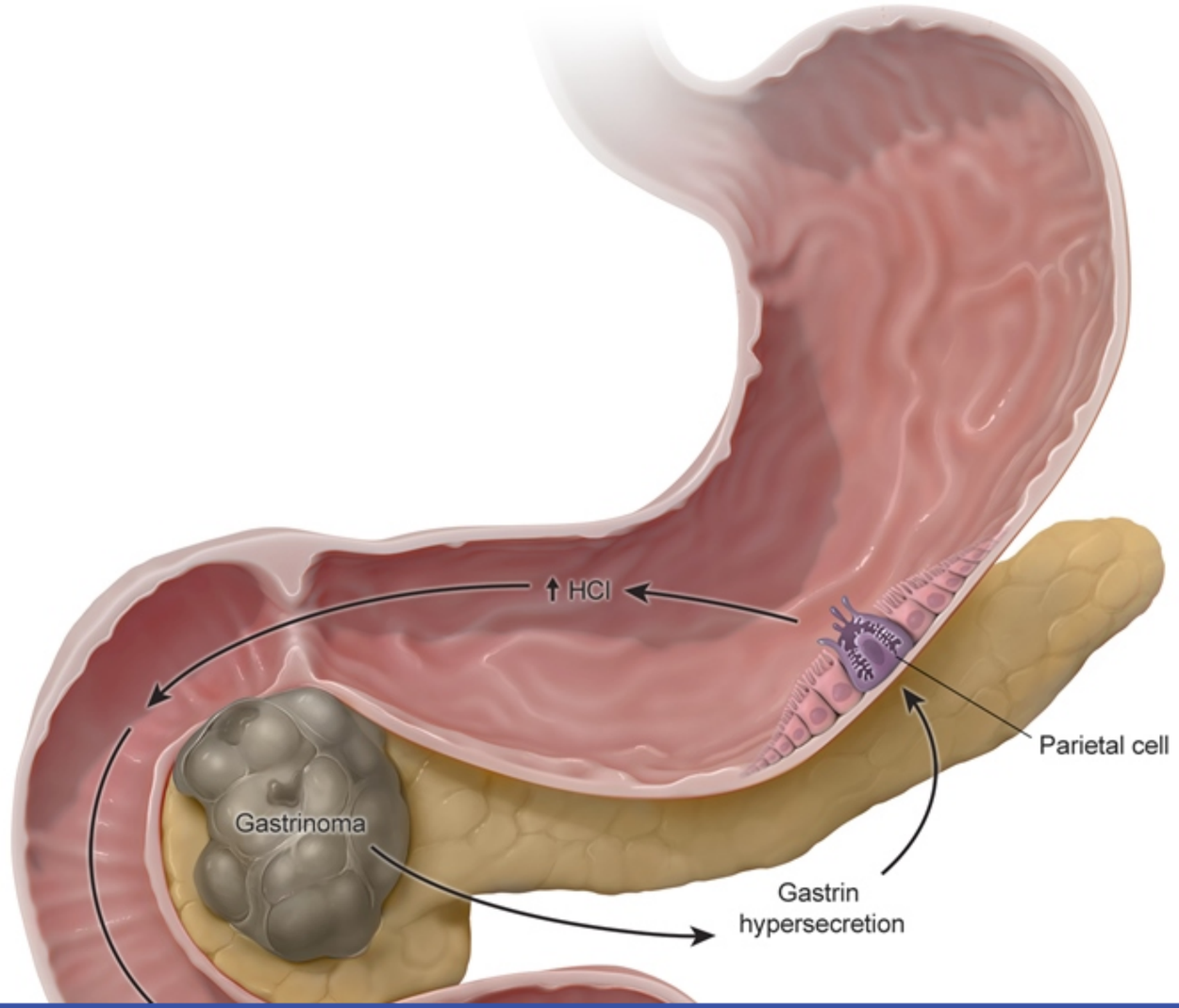

Block Time Remaining: 00:01:02
TUTOR

3 | Feedback | Suspend | End Block

1 2 3 4 5 6 7 8 9 10 11 12 13 14 15 16 17 18 19 20 21 22 23 24 25 26 27 28 29 30

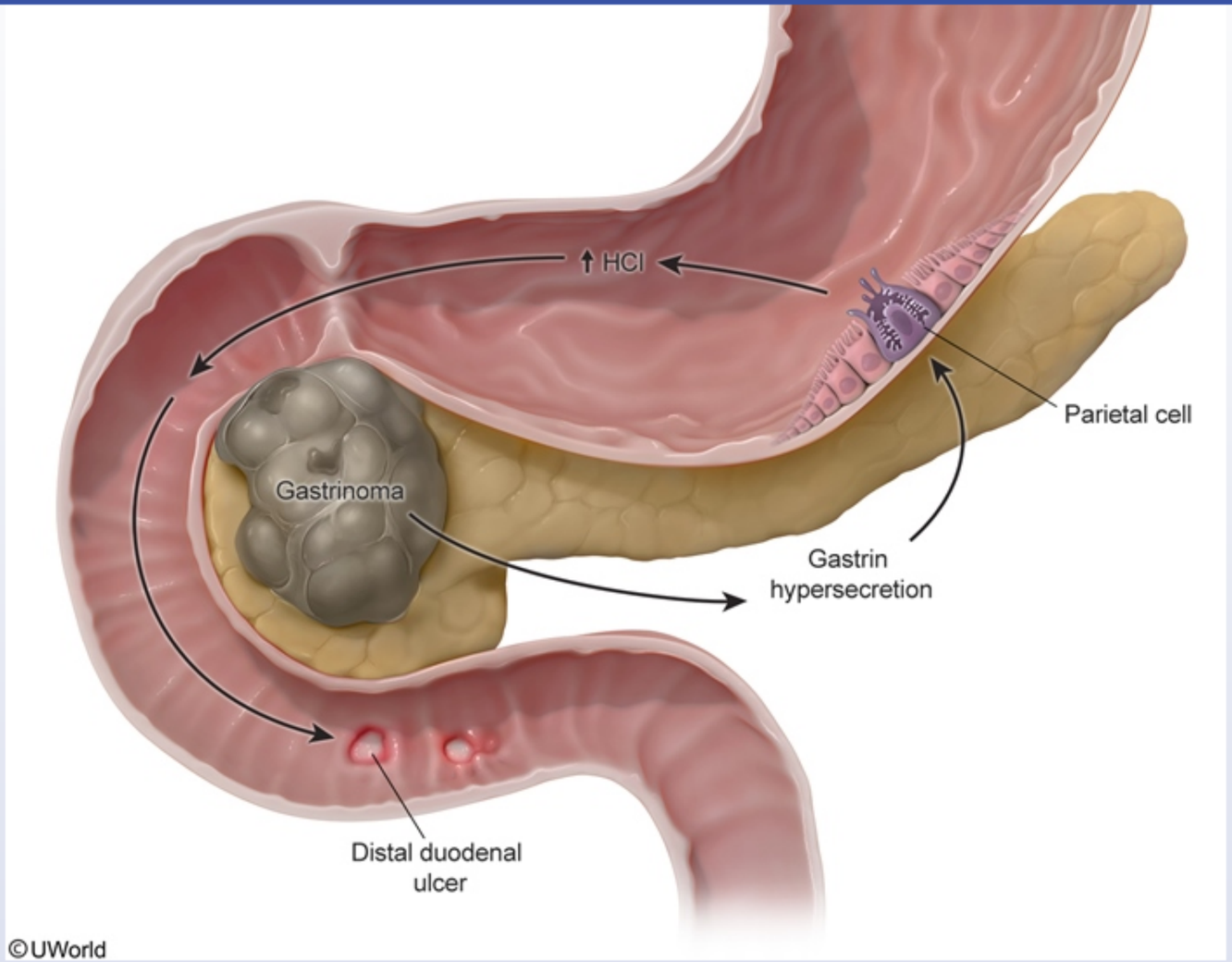

This patient's distal duodenal ulcer and high-normal gastrin levels that rise in response to secretin administration are suggestive of **Zollinger-Ellison syndrome** (ZES). This condition is caused by **gastrin-secreting tumors** (gastrinomas) that are often malignant and usually located in the small intestine or pancreas. Gastrin causes parietal cell hyperplasia and stimulates gastric acid secretion, resulting in the development of

©UWorld

This patient's distal duodenal ulcer and high-normal gastrin levels that rise in response to secretin administration are suggestive of **Zollinger-Ellison syndrome** (ZES). This condition is caused by **gastrin-secreting tumors** (gastrinomas) that are often malignant and usually located in the small intestine or pancreas. Gastrin causes parietal cell hyperplasia and stimulates gastric acid secretion, resulting in the development of **peptic ulcers**, heartburn, and **diarrhea** (excess gastric acid impairs intestinal epithelial cells and digestive enzymes). Although most proximal duodenal ulcers are caused by *Helicobacter pylori* infection or nonsteroidal anti-inflammatory drug (NSAID) use **(Choice E)**, ulcers found **beyond the duodenal bulb** suggest ZES.

Secretin is a hormone released from the duodenum in response to acid and fat in the small intestine. The hormone increases pancreatic bicarbonate secretion and inhibits the release of gastrin from normal gastric G cells. However, secretin paradoxically **stimulates gastrin release from gastrinomas** due to abnormal adenylate cyclase activation. As such, secretin administration can be used to differentiate ZES from other causes of hypergastrinemia (eg, atrophic gastritis).

(Choice A) Autoimmune gastritis (chronic atrophic gastritis) involves the body/fundus of the stomach with antral sparing. $CD4^+$ T cell-mediated parietal cell destruction causes impaired gastric acid and intrinsic factor secretion, resulting in achlorhydria and pernicious anemia, respectively. Low acid levels stimulate gastrin release from G cells (hypergastrinemia), but secretin administration causes a reduction in gastrin levels.

(Choice B) *H pylori* infection is associated with chronic antral-predominant gastritis, which may lead to a reduction in somatostatin-producing cells (delta cells). Lack of inhibition by somatostatin allows for excessive gastrin release, which promotes gastric acid hypersecretion and proximal duodenal ulcer formation. Secretin administration typically causes a reduction in gastrin levels in these patients.

(Choice C) Crohn disease is associated with dysregulation of the mucosal immune response, intestinal epithelial dysfunction, and altered composition of gut flora. Patients characteristically have linear ulcerations with adjacent normal-appearing mucosa (cobblestone appearance) in the small intestine.

(Choice F) Stress-related mucosal disease can occur with severe physiologic stress (eg, shock, head trauma, burns), but the association between psychological stress (eg, working as an air traffic controller) and peptic ulcer formation is controversial. Nonetheless, neither form of stress would cause distal duodenal ulcers and hypergastrinemia.

Educational objective:

causes of hypergastrinemia (eg, atrophic gastritis).

(Choice A) Autoimmune gastritis (chronic atrophic gastritis) involves the body/fundus of the stomach with antral sparing. $CD4^+$ T cell-mediated parietal cell destruction causes impaired gastric acid and intrinsic factor secretion, resulting in achlorhydria and pernicious anemia, respectively. Low acid levels stimulate gastrin release from G cells (hypergastrinemia), but secretin administration causes a reduction in gastrin levels.

(Choice B) *H pylori* infection is associated with chronic antral-predominant gastritis, which may lead to a reduction in somatostatin-producing cells (delta cells). Lack of inhibition by somatostatin allows for excessive gastrin release, which promotes gastric acid hypersecretion and proximal duodenal ulcer formation. Secretin administration typically causes a reduction in gastrin levels in these patients.

(Choice C) Crohn disease is associated with dysregulation of the mucosal immune response, intestinal epithelial dysfunction, and altered composition of gut flora. Patients characteristically have linear ulcerations with adjacent normal-appearing mucosa (cobblestone appearance) in the small intestine.

(Choice F) Stress-related mucosal disease can occur with severe physiologic stress (eg, shock, head trauma, burns), but the association between psychological stress (eg, working as an air traffic controller) and peptic ulcer formation is controversial. Nonetheless, neither form of stress would cause distal duodenal ulcers and hypergastrinemia.

Educational objective:
Zollinger-Ellison syndrome is caused by gastrinomas located in the small intestine/pancreas and presents with peptic ulcers (especially distal duodenal ulcers), heartburn, and diarrhea. Patients typically have elevated gastrin levels that rise in response to exogenous secretin administration. In contrast, secretin inhibits release of gastrin from normal gastric G cells.

References

- Hypergastrinemia.

Pathology	Gastrointestinal & Nutrition	Zollinger ellison syndrome
Subject	System	Topic

Copyright © UWorld. All rights reserved.

A 15-year-old boy comes to the office for a follow-up appointment. Since early childhood, he has suffered from recurrent respiratory infections and chronic diarrhea. The patient has been hospitalized several times for parenteral antibiotic treatment. Current prescribed medications include pancreatic enzyme therapy and a number of dietary supplements. Physical examination shows decreased proprioception and hyporeflexia in the lower extremities. Laboratory findings are suggestive of mild hemolytic anemia. Which of the following conditions is the most likely cause of these findings?

- A. Niacin deficiency
- B. Riboflavin deficiency
- C. Thiamine deficiency
- D. Vitamin A deficiency
- E. Vitamin C overuse
- F. Vitamin D deficiency
- G. Vitamin E deficiency
- H. Vitamin K deficiency

Submit

1 2 3 4 5 6 7 8 9 10 11 12 13 14 15 16 17 18 19 20 21 22 23 24 25 26 27 28 29 30

A 15-year-old boy comes to the office for a follow-up appointment. Since early childhood, he has suffered from recurrent respiratory infections and chronic diarrhea. The patient has been hospitalized several times for parenteral antibiotic treatment. Current prescribed medications include pancreatic enzyme therapy and a number of dietary supplements. Physical examination shows decreased proprioception and hyporeflexia in the lower extremities. Laboratory findings are suggestive of mild hemolytic anemia. Which of the following conditions is the most likely cause of these findings?

- A. Niacin deficiency (7%)
- B. Riboflavin deficiency (6%)
- C. Thiamine deficiency (17%)
- D. Vitamin A deficiency (4%)
- E. Vitamin C overuse (2%)
- F. Vitamin D deficiency (2%)
- ✓ G. Vitamin E deficiency (53%)
- H. Vitamin K deficiency (6%)

Omitted
Correct answer
G

53%
Answered correctly

01 sec
Time Spent

03/02/2020
Last Updated

Explanation

The combination of recurrent respiratory infections and diarrhea in a child or young adult is strongly suggestive of cystic fibrosis with secondary exocrine pancreatic insufficiency. Because pancreatic enzymes are necessary for the proper absorption of nutrients in the gut, fat malabsorption with deficiencies of the fat-soluble vitamins A, D, E, and K frequently occurs in patients with cystic fibrosis.

Vitamin E primarily serves to protect fatty acids from oxidation; **vitamin E deficiency** predisposes cell membranes to oxidative injury. The cells that are most susceptible include neurons with long axons (due to large membrane surface area) and erythrocytes (due to high oxygen exposure). The most common clinical manifestations of vitamin E deficiency are **neuromuscular disease** (eg, skeletal myopathy, spinocerebellar ataxia, polyneuropathy) and **hemolytic anemia**. Involvement of the dorsal column in the spinal cord is associated with the loss of proprioception and vibratory sense. Spinocerebellar tract involvement causes ataxia, and peripheral nerve dysfunction results in hyporeflexia.

(Choices A, B, and C) Thiamine (vitamin B_1), riboflavin (vitamin B_2), and niacin (vitamin B_3) are water-soluble vitamins and not affected by fat malabsorption.

(Choice D) Vitamin A deficiency manifests with night blindness, dry eyes (xerophthalmia), and corneal softening (keratomalacia).

(Choice E) Vitamin C overdose can cause nausea, abdominal pain, and diarrhea. Chronic intake of high doses of vitamin C may facilitate the development of calcium oxalate kidney stones.

(Choice F) Vitamin D is essential for bone formation and mineralization. Deficiency of this vitamin presents as rickets in children and as osteomalacia in adults.

(Choice H) Vitamin K is necessary for hepatic synthesis of clotting factors II, VII, IX, and X. Deficiency of this vitamin presents as an increased tendency to bleed.

Educational objective:
Vitamin E deficiency can occur in individuals with fat malabsorption. Deficiency of this fat-soluble vitamin is associated with increased susceptibility of the neuronal and erythrocyte membranes to oxidative stress. Clinical manifestations include ataxia, impaired proprioception and vibratory sensation, and hemolytic anemia.

References

- Vitamin E supplementation in people with cystic fibrosis

that are most susceptible include neurons with long axons (due to large membrane surface area) and erythrocytes (due to high oxygen exposure).

The most common clinical manifestations of vitamin E deficiency are **neuromuscular disease** (eg, skeletal myopathy, spinocerebellar ataxia, polyneuropathy) and **hemolytic anemia**. Involvement of the dorsal column in the spinal cord is associated with the loss of proprioception and vibratory sense. Spinocerebellar tract involvement causes ataxia, and peripheral nerve dysfunction results in hyporeflexia.

(Choices A, B, and C) Thiamine (vitamin B_1), riboflavin (vitamin B_2), and niacin (vitamin B_3) are water-soluble vitamins and not affected by fat malabsorption.

(Choice D) Vitamin A deficiency manifests with night blindness, dry eyes (xerophthalmia), and corneal softening (keratomalacia).

(Choice E) Vitamin C overdose can cause nausea, abdominal pain, and diarrhea. Chronic intake of high doses of vitamin C may facilitate the development of calcium oxalate kidney stones.

(Choice F) Vitamin D is essential for bone formation and mineralization. Deficiency of this vitamin presents as rickets in children and as osteomalacia in adults.

(Choice H) Vitamin K is necessary for hepatic synthesis of clotting factors II, VII, IX, and X. Deficiency of this vitamin presents as an increased tendency to bleed.

Educational objective:
Vitamin E deficiency can occur in individuals with fat malabsorption. Deficiency of this fat-soluble vitamin is associated with increased susceptibility of the neuronal and erythrocyte membranes to oxidative stress. Clinical manifestations include ataxia, impaired proprioception and vibratory sensation, and hemolytic anemia.

References

- Vitamin E supplementation in people with cystic fibrosis.

Pathology	Gastrointestinal & Nutrition	Vitamin e
Subject	System	Topic

Copyright © UWorld. All rights reserved.

A 34-year-old man comes to the office due to upper abdominal pain. The patient has vague discomfort that happens mostly in the afternoon and at night and is partially relieved by food. He sometimes feels nauseated. He has had no vomiting, black or bloody stools, or weight loss. The patient takes no prescription or over-the-counter medications. Family history is negative for cancer. Upper gastrointestinal endoscopy reveals a small ulcer with a clean base in the duodenal bulb. Biopsy of which of the following sites is most likely to demonstrate the infectious agent responsible for this patient's current condition?

A. Gastric antrum

B. Gastric body

C. Gastric fundus

D. Lower duodenum

E. Upper duodenum

Submit

A 34-year-old man comes to the office due to upper abdominal pain. The patient has vague discomfort that happens mostly in the afternoon and at night and is partially relieved by food. He sometimes feels nauseated. He has had no vomiting, black or bloody stools, or weight loss. The patient takes no prescription or over-the-counter medications. Family history is negative for cancer. Upper gastrointestinal endoscopy reveals a small ulcer with a clean base in the duodenal bulb. Biopsy of which of the following sites is most likely to demonstrate the infectious agent responsible for this patient's current condition?

- ✓ A. Gastric antrum (73%)
- B. Gastric body (4%)
- C. Gastric fundus (5%)
- D. Lower duodenum (1%)
- E. Upper duodenum (14%)

Omitted
Correct answer
A

73%
Answered correctly

02 secs
Time Spent

03/06/2020
Last Updated

Explanation

***Helicobacter pylori* and duodenal ulcers**

Helicobacter pylori and duodenal ulcers

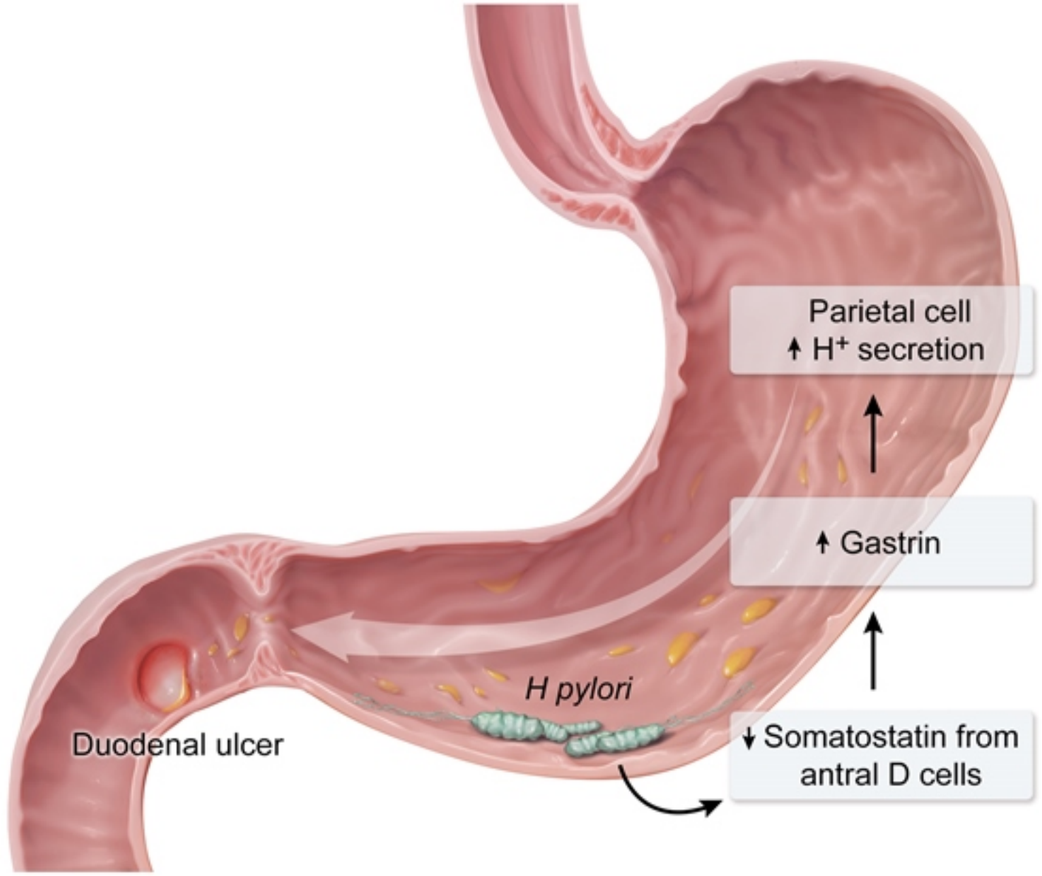

©UWorld

Peptic (eg, duodenal, gastric, gastroesophageal) ulcers are most commonly due to ***Helicobacter pylori*** infection or use of nonsteroidal anti-inflammatory drugs. Because this patient takes no medications, his ulcer is likely due to *H pylori* infection. The site of ulcer formation is dependent on relative bacterial colonization density within the stomach. *H pylori* preferentially colonizes the gastric antrum, particularly early in the

©UWorld

Peptic (eg, duodenal, gastric, gastroesophageal) ulcers are most commonly due to ***Helicobacter pylori*** infection or use of nonsteroidal anti-inflammatory drugs. Because this patient takes no medications, his ulcer is likely due to *H pylori* infection. The site of ulcer formation is dependent on relative bacterial colonization density within the stomach. *H pylori* preferentially colonizes the gastric antrum, particularly early in the disease, although it may occur in other areas of the stomach or spread with time.

Colonization of *H pylori* in the **gastric antrum** is associated with **decreased somatostatin** formation and increased gastrin secretion, which stimulate the parietal cells to produce **excess acid**. This results in an increased acid load emptying into the proximal duodenum, leading to **duodenal ulcer** (DU) formation. Biopsy of the antrum can confirm *H pylori* infection in patients with a DU, which characteristically presents with upper abdominal pain that improves with eating.

In contrast, **gastric ulcers** (GUs) are associated with colonization in the **gastric corpus** (body). The etiology of GUs is not acid related, as these patients typically have normal or reduced acid levels, but is thought to be due to **direct mucosal damage** and chronic inflammation. Unlike DU pain, GU pain often worsens with eating.

(Choices B and C) Patients with DUs who are infected with *H pylori* may test positive for the organism at multiple locations within the stomach. However, colonization density is highest within the antrum, not the gastric body or the gastric fundus; therefore, the antrum is the optimal site for biopsy.

(Choices D and E) Although the ulcer occurs in the duodenum, high concentrations of *H pylori* are not typically found in the duodenal regions, as *H pylori* can colonize only gastric tissue or areas of gastric metaplasia.

Educational objective:
Helicobacter pylori is a common cause of peptic ulcers. Duodenal ulcers are associated with heavy colonization in the gastric antrum, whereas colonization in the gastric corpus is associated with gastric ulcers.

Pathology	Gastrointestinal & Nutrition	Peptic ulcer disease
Subject	System	Topic

Copyright © UWorld. All rights reserved.

Peptic (eg, duodenal, gastric, gastroesophageal) ulcers are most commonly due to ***Helicobacter pylori*** infection or use of nonsteroidal anti-

Exhibit Display

Regions of the stomach

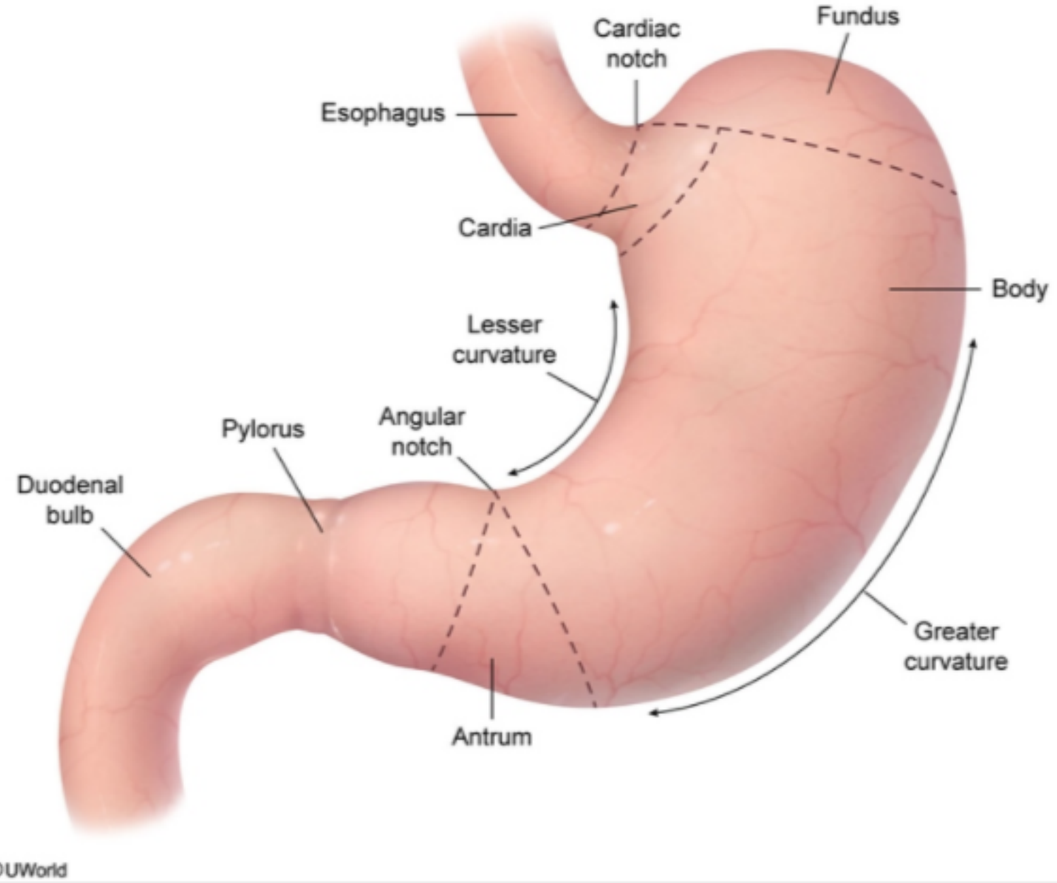

©UWorld

Zoom In | Zoom Out | Reset | Add To New Card | Existing Card

A 40-year-old man comes to the office with pain on defecation. The pain is sharp and severe but subsides within minutes of passing the bowel movement. He often sees spots of bright red blood on the toilet paper. The patient has chronic constipation and has not taken laxatives or increased his fluid intake to compensate. He has no fever, night sweats, diarrhea, or unexpected weight loss. Past medical history is notable for chronic low back pain following a motor vehicle accident, for which he takes a scheduled dose of pain relievers. The patient has smoked a pack of cigarettes daily for the last 20 years but does not use alcohol or illicit drugs. He is married and has no outside sexual contacts. Vital signs are normal. The abdomen is soft and nontender with no hepatosplenomegaly. Rectal examination is likely to show a tear at which of the following locations?

- A. Anterior midline distal to the dentate line
- B. Anterior midline proximal to the dentate line
- C. Bilateral distal to the dentate line
- D. Lateral distal to the dentate line
- E. Lateral proximal to the dentate line
- F. Posterior midline distal to the dentate line

Submit

1 2 3 4 5 6 7 8 9 10 11 12 13 14 15 16 17 18 19 20 21 22 23 24 25 26 27 28 29 30

A 40-year-old man comes to the office with pain on defecation. The pain is sharp and severe but subsides within minutes of passing the bowel movement. He often sees spots of bright red blood on the toilet paper. The patient has chronic constipation and has not taken laxatives or increased his fluid intake to compensate. He has no fever, night sweats, diarrhea, or unexpected weight loss. Past medical history is notable for chronic low back pain following a motor vehicle accident, for which he takes a scheduled dose of pain relievers. The patient has smoked a pack of cigarettes daily for the last 20 years but does not use alcohol or illicit drugs. He is married and has no outside sexual contacts. Vital signs are normal. The abdomen is soft and nontender with no hepatosplenomegaly. Rectal examination is likely to show a tear at which of the following locations?

- A. Anterior midline distal to the dentate line (12%)
- B. Anterior midline proximal to the dentate line (6%)
- C. Bilateral distal to the dentate line (5%)
- D. Lateral distal to the dentate line (11%)
- E. Lateral proximal to the dentate line (3%)
- ✓ F. Posterior midline distal to the dentate line (59%)

Omitted
Correct answer
F

59%
Answered correctly

02 secs
Time Spent

05/01/2020
Last Updated

Explanation

Anorectal arterial supply

1 2 3 4 5 6 7 8 9 10 11 12 13 14 15 16 17 18 19 20 21 22 23 24 25 26 27 28 29 30

Anorectal arterial supply

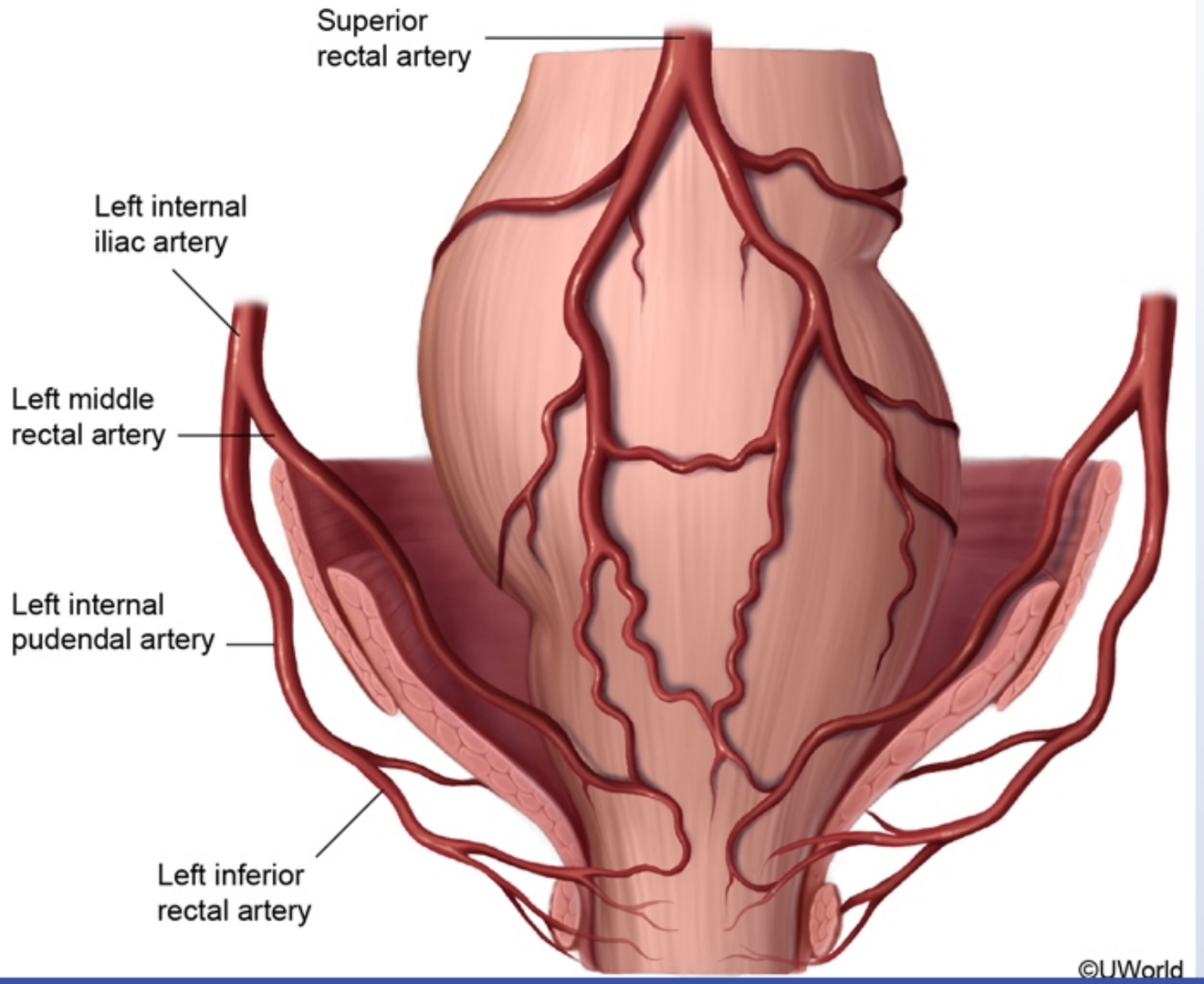

©UWorld

This patient has sharp pain and bright red rectal bleeding on defecation, suggesting an **anal fissure**. Anal fissures are due to stretching of the mucosa and are characterized by longitudinal tears in the anal canal distal to the dentate line **(Choice B)**. Spasm of the sphincter can contribute to the pain and create tension across the wound, leading to a chronic fissure. Most fissures are related to chronic constipation with high anal pressures and passage of hard stools. They can also be seen with frequent diarrhea or anal sexual intercourse. In some cases, the pain may be so severe that patients withhold bowel movements, thereby exacerbating the constipation.

The majority of fissures, especially those causing prolonged symptoms, occur at the **posterior midline** of the anal verge. This is likely due to the relatively poor perfusion of the posterior anal canal, which makes its mucosa sensitive to trauma and slows healing times. Anterior midline fissures are less common, but may occur due to mechanical stresses related to the alignment of muscular fibers in the external sphincter **(Choice A)**.

(Choice C) Bilateral anal fissures are uncommon.

(Choices D and E) Fissures not at the midline are more likely due to unusual causes (eg, inflammatory bowel disease, malignancy, infection) and may warrant more detailed investigation.

Educational objective:
Anal fissures are longitudinal tears in the mucosa. They are usually due to passage of hard stool in patients with chronic constipation. Most fissures occur at the posterior midline, likely due to decreased blood flow in this area. Fissures in other areas may be due to less common causes.

References

- Anorectal conditions: anal fissure and anorectal fistula.

Pathology	Gastrointestinal & Nutrition	Anal fissure
Subject	System	Topic

Copyright © UWorld. All rights reserved.

A 45-year-old woman is brought to the emergency department with severe abdominal pain, fever, and confusion. The patient's husband reports that, yesterday, she began to have worsening right-sided abdominal pain associated with nausea and several episodes of vomiting. This morning, she has been slow to respond and is confused about where she is. The patient has a history of depression and takes sertraline. Temperature is 39.5 C (103.1 F), blood pressure is 88/50 mm Hg, pulse is 104/min, and respirations are 26/min. She appears ill and confused, and the sclera are icteric. Abdominal examination demonstrates significant tenderness with guarding in the right upper quadrant. Which of the following is the most likely underlying cause of this patient's current condition?

- A. Acinar cell dysfunction and necrosis
- B. Calculous obstruction of the common bile duct
- C. Extensive hepatic formation of noncaseating granulomas
- D. Immune-mediated destruction of hepatocytes
- E. Medication overdose with hepatic failure
- F. Neoplastic mass in the pancreatic tail

Submit

A 45-year-old woman is brought to the emergency department with severe abdominal pain, fever, and confusion. The patient's husband reports that, yesterday, she began to have worsening right-sided abdominal pain associated with nausea and several episodes of vomiting. This morning, she has been slow to respond and is confused about where she is. The patient has a history of depression and takes sertraline. Temperature is 39.5 C (103.1 F), blood pressure is 88/50 mm Hg, pulse is 104/min, and respirations are 26/min. She appears ill and confused, and the sclera are icteric. Abdominal examination demonstrates significant tenderness with guarding in the right upper quadrant. Which of the following is the most likely underlying cause of this patient's current condition?

- A. Acinar cell dysfunction and necrosis (4%)
- ✓ B. Calculous obstruction of the common bile duct (57%)
- C. Extensive hepatic formation of noncaseating granulomas (1%)
- D. Immune-mediated destruction of hepatocytes (6%)
- E. Medication overdose with hepatic failure (29%)
- F. Neoplastic mass in the pancreatic tail (0%)

Omitted
Correct answer
B

57%
Answered correctly

02 secs
Time Spent

04/22/2020
Last Updated

Explanation

Acute cholangitis

Acute cholangitis	
Etiology	• Ascending infection due to biliary obstruction ◦ Obstructive gallstone ◦ Malignancy (eg, cholangiocarcinoma, pancreatic head cancer) ◦ Stricture (eg, primary sclerosing cholangitis) ◦ Biliary stent blockage
Clinical presentation	• Fever, jaundice, RUQ pain (Charcot triad) • ± Hypotension, altered mental status (Reynolds pentad)
Laboratory results	• Cholestatic liver function test ◦ ↑ Alkaline phosphatase, bilirubin ◦ ± Mildly elevated transaminases • Leukocytosis
Imaging	• Biliary dilation on abdominal imaging

RUQ = right upper quadrant.

This patient with fever, right upper quadrant (RUQ) pain, jaundice, confusion, and hypotension has **acute cholangitis (AC)**. AC is a life-threatening infection that typically develops in the setting of **biliary obstruction**, which enables bacteria to proliferate within the biliary tree. Obstruction can occur in a variety of settings (eg, malignant biliary obstruction, biliary stricture) but is most commonly caused by a **calculous obstruction of the common bile duct** (ie, choledocholithiasis).

AC is characterized by **fever**, **RUQ pain**, and **jaundice** (Charcot triad); **hypotension** and **altered mental status** (Reynold pentad) occur in severe cases. Laboratory findings include leukocytosis, direct hyperbilirubinemia, and elevated alkaline phosphatase. Abdominal imaging (eg, ultrasound) demonstrates common bile duct dilation, possibly with evidence of an obstructing stone. Management includes antibiotics, intravenous fluid resuscitation, and endoscopic or percutaneous techniques to relieve the biliary obstruction.

This patient with fever, right upper quadrant (RUQ) pain, jaundice, confusion, and hypotension has **acute cholangitis (AC)**. AC is a life-threatening infection that typically develops in the setting of **biliary obstruction**, which enables bacteria to proliferate within the biliary tree. Obstruction can occur in a variety of settings (eg, malignant biliary obstruction, biliary stricture) but is most commonly caused by a **calculous obstruction of the common bile duct** (ie, choledocholithiasis).

AC is characterized by **fever**, **RUQ pain**, and **jaundice** (Charcot triad); **hypotension** and **altered mental status** (Reynold pentad) occur in severe cases. Laboratory findings include leukocytosis, direct hyperbilirubinemia, and elevated alkaline phosphatase. Abdominal imaging (eg, ultrasound) demonstrates common bile duct dilation, possibly with evidence of an obstructing stone. Management includes antibiotics, intravenous fluid resuscitation, and endoscopic or percutaneous techniques to relieve the biliary obstruction.

(Choice A) Acute pancreatitis is characterized by acinar cell dysfunction and necrosis. Although patients can develop fever and hypotension, typical manifestations include epigastric pain radiating into the back, nausea/vomiting, and elevated lipase. Jaundice is unexpected unless a gallstone obstructs both the common bile and the pancreatic ducts, resulting in simultaneous AC.

(Choice C) Hepatic sarcoidosis, which causes extensive noncaseating granuloma formation in the liver, can present with cholestasis (eg, elevated alkaline phosphatase, jaundice, pruritus) and hepatomegaly. However, sepsis, hypotension, and confusion are unexpected, and most patients have evidence of systemic sarcoidosis (eg, hilar adenopathy, cough).

(Choice D) Autoimmune hepatitis causes immune-mediated hepatocyte destruction and usually presents with asymptomatic transaminitis or the insidious onset of fatigue and anorexia. Fever, tachycardia, and hypotension are unexpected and more consistent with infection due to AC.

(Choice E) Acetaminophen overdose can cause RUQ pain, jaundice, vomiting, and confusion, typically around 72 hours after ingestion. However, fever is atypical and more consistent with AC.

(Choice F) Although a mass in the pancreatic head can cause biliary obstruction, pancreatic tail masses are not located near the biliary tree and therefore are not usually associated with AC. They more commonly present with epigastric abdominal pain and weight loss.

Educational objective:
Acute cholangitis is a life-threatening infection characterized by fever, right upper quadrant pain, and jaundice (Charcot triad); hypotension and altered mental status (Reynold pentad) occur in severe cases. Acute cholangitis typically develops in the setting of biliary obstruction; common

cases. Laboratory findings include leukocytosis, direct hyperbilirubinemia, and elevated alkaline phosphatase. Abdominal imaging (eg, ultrasound) demonstrates common bile duct dilation, possibly with evidence of an obstructing stone. Management includes antibiotics, intravenous fluid resuscitation, and endoscopic or percutaneous techniques to relieve the biliary obstruction.

(Choice A) Acute pancreatitis is characterized by acinar cell dysfunction and necrosis. Although patients can develop fever and hypotension, typical manifestations include epigastric pain radiating into the back, nausea/vomiting, and elevated lipase. Jaundice is unexpected unless a gallstone obstructs both the common bile and the pancreatic ducts, resulting in simultaneous AC.

(Choice C) Hepatic sarcoidosis, which causes extensive noncaseating granuloma formation in the liver, can present with cholestasis (eg, elevated alkaline phosphatase, jaundice, pruritus) and hepatomegaly. However, sepsis, hypotension, and confusion are unexpected, and most patients have evidence of systemic sarcoidosis (eg, hilar adenopathy, cough).

(Choice D) Autoimmune hepatitis causes immune-mediated hepatocyte destruction and usually presents with asymptomatic transaminitis or the insidious onset of fatigue and anorexia. Fever, tachycardia, and hypotension are unexpected and more consistent with infection due to AC.

(Choice E) Acetaminophen overdose can cause RUQ pain, jaundice, vomiting, and confusion, typically around 72 hours after ingestion. However, fever is atypical and more consistent with AC.

(Choice F) Although a mass in the pancreatic head can cause biliary obstruction, pancreatic tail masses are not located near the biliary tree and therefore are not usually associated with AC. They more commonly present with epigastric abdominal pain and weight loss.

Educational objective:
Acute cholangitis is a life-threatening infection characterized by fever, right upper quadrant pain, and jaundice (Charcot triad); hypotension and altered mental status (Reynold pentad) occur in severe cases. Acute cholangitis typically develops in the setting of biliary obstruction; common etiologies include gallstones, malignancy, and strictures.

Pathology	Gastrointestinal & Nutrition	Cholangitis
Subject	System	Topic

Copyright © UWorld. All rights reserved.

A 59-year-old man is evaluated in the clinic for recent unintentional weight loss. He says, "My pants are fitting a lot looser than usual." The patient also has epigastric discomfort after meals with occasional nausea. He reports that food is not as appetizing as it used to be. He has no known medical problems and takes no medications. The patient's father has a history of peptic ulcer disease. Upper endoscopy shows a lesion in the stomach that is biopsied and displayed in the slide below.

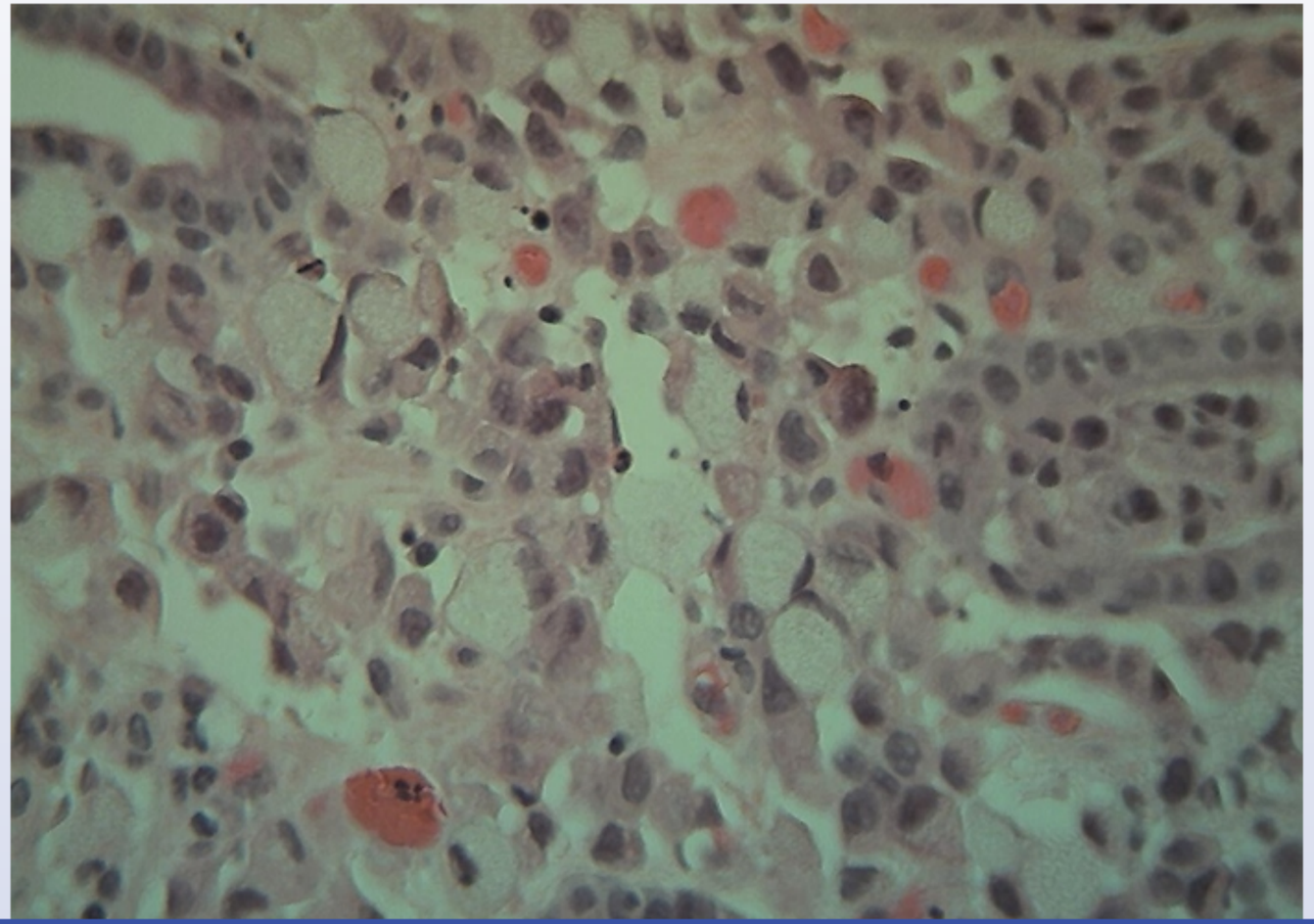

1 2 3 4 5 6 7 8 9 10 11 12 13 14 15 16 17 18 19 20 21 22 23 24 25 26 27 28 29 30

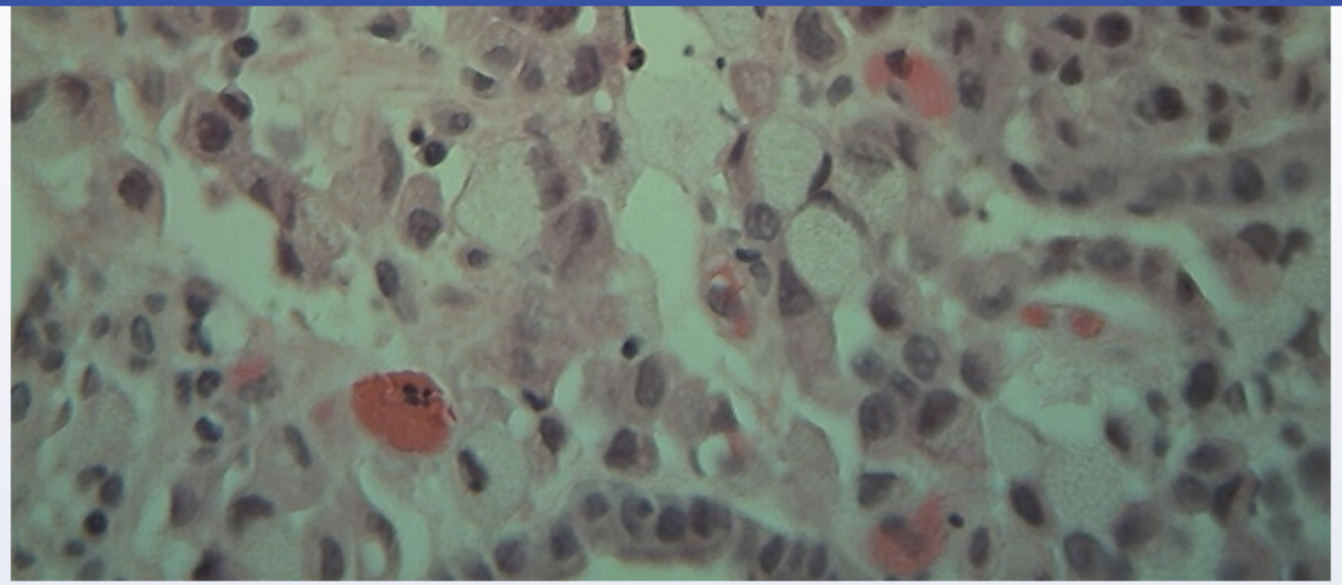

The lesion most likely demonstrates which of the following?

- A. Deep ulceration and vessel erosion
- B. Infiltrative growth within the stomach wall
- C. Progressive mucosal atrophy
- D. Rapid intraluminal expansion
- E. Rugal thickening with acid hypersecretion

Submit

1 2 3 4 5 6 7 8 9 10 11 12 13 14 15 16 17 18 19 20 21 22 23 24 25 26 27 28 29 30

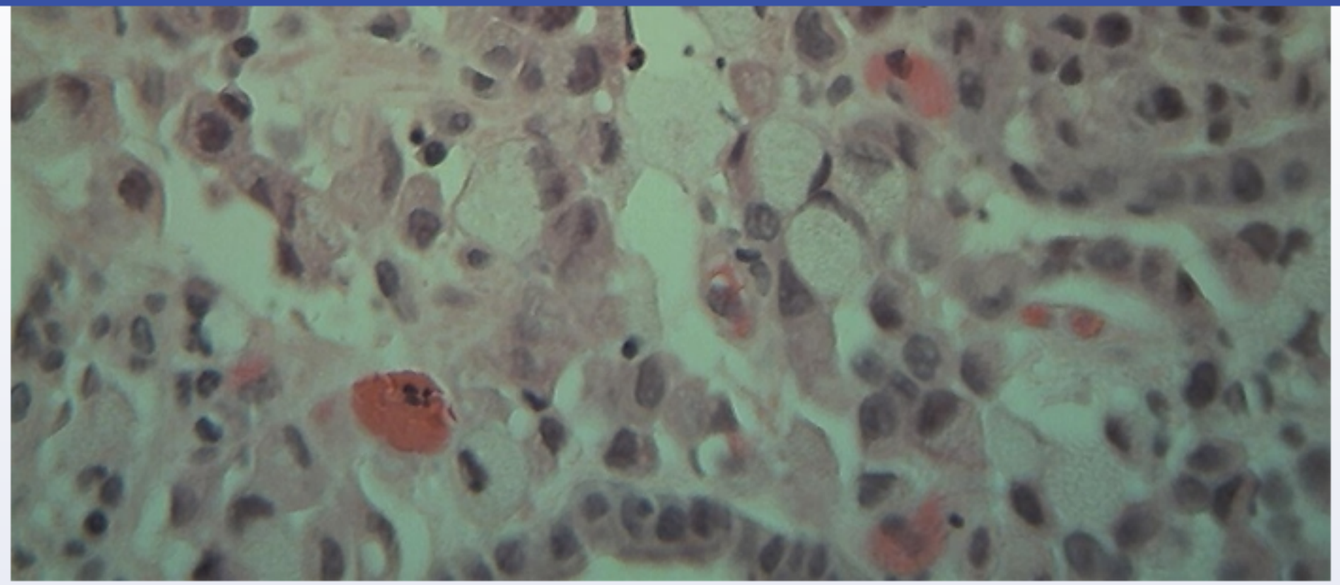

The lesion most likely demonstrates which of the following?

- A. Deep ulceration and vessel erosion (13%)
- ✓ B. Infiltrative growth within the stomach wall (52%)
- C. Progressive mucosal atrophy (12%)
- D. Rapid intraluminal expansion (3%)
- E. Rugal thickening with acid hypersecretion (17%)

Omitted
Correct answer

52%
Answered correctly

05 secs
Time Spent

01/13/2020
Last Updated

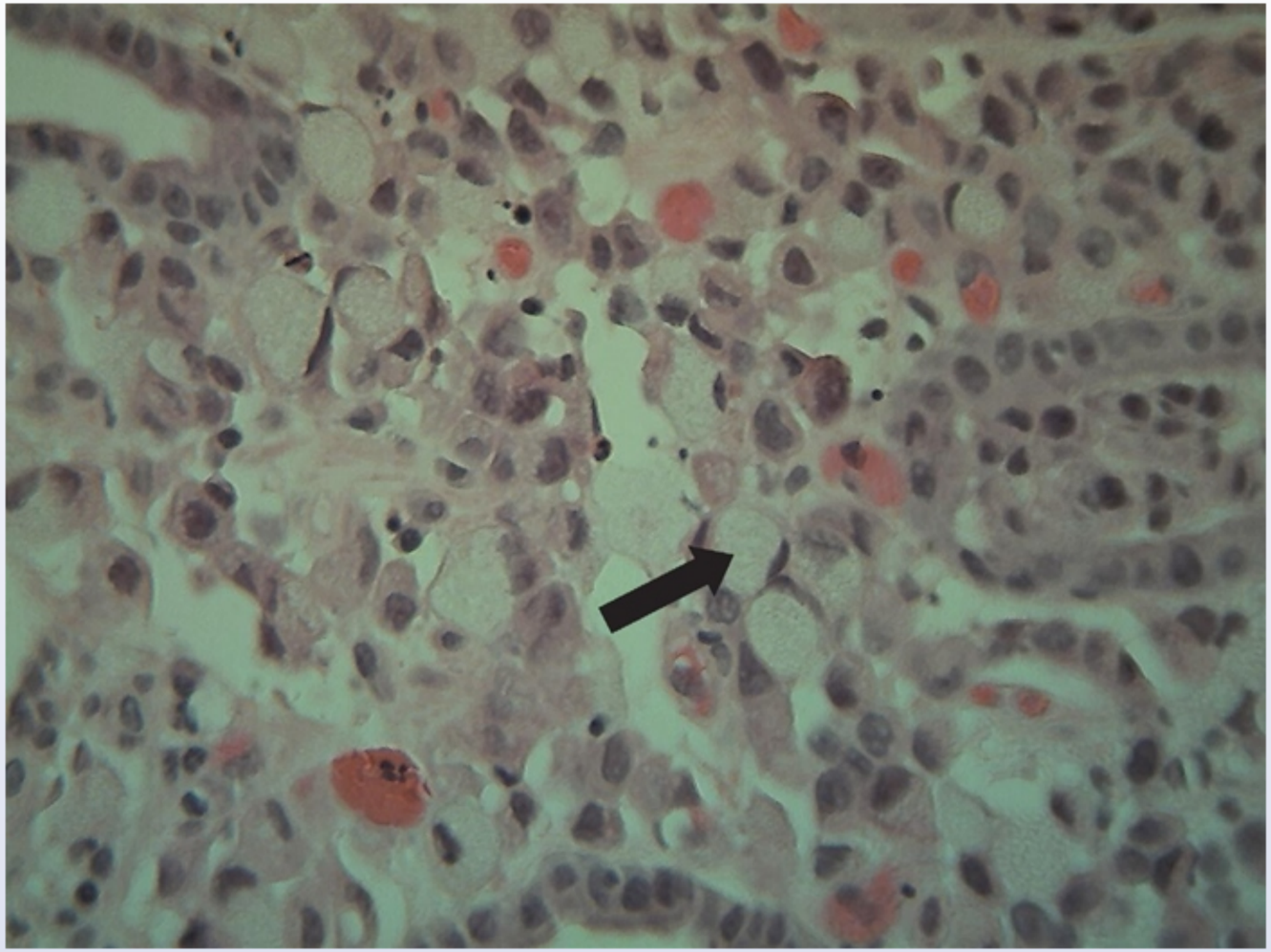

This slide shows typical features of **signet-ring carcinoma**, 1 of 2 major types of **gastric adenocarcinoma**. Signet-ring carcinomas consist of cells that do not form glands. Cells often contain abundant mucin droplets that push the nucleus to one side and lead to the characteristic appearance of a signet ring. On gross examination, signet-ring carcinomas are characterized by **diffuse** involvement of the stomach wall (due to loss of the cell adhesion protein **E-cadherin**). They have a plaquelike appearance, are ill-defined, and often infiltrate large areas of the stomach

This slide shows typical features of **signet-ring carcinoma**, 1 of 2 major types of **gastric adenocarcinoma**. Signet-ring carcinomas consist of cells that do not form glands. Cells often contain abundant mucin droplets that push the nucleus to one side and lead to the characteristic appearance of a signet ring. On gross examination, signet-ring carcinomas are characterized by **diffuse** involvement of the stomach wall (due to loss of the cell adhesion protein **E-cadherin**). They have a plaquelike appearance, are ill-defined, and often infiltrate large areas of the stomach wall, causing a "leather-bottle stomach" **(linitis plastica)**.

Intestinal-type adenocarcinomas of the stomach closely resemble colon cancers, showing well-formed glands that consist of columnar or cuboidal cells. They tend to grow as nodular, polypoid, and well-demarcated masses that rapidly expand within the gastric lumen **(Choice D)**. These lesions often ulcerate/bleed and must be differentiated from peptic gastric ulcers by biopsy **(Choice A)**.

The most important factors that influence survival rate with gastric adenocarcinoma are the depth of invasion through the gastric wall and regional lymph node involvement. Metastasis is often present at the time of diagnosis and most commonly involves the **supraclavicular** lymph node (Virchow node) and **periumbilical** nodes (Sister Mary Joseph nodule).

(Choice C) Chronic gastritis is most commonly associated with *Helicobacter pylori* infection. Long-standing inflammation of the gastric mucosa can lead to diffuse gland atrophy and intestinal metaplasia. Chronic gastric inflammation increases the risk of gastric carcinomas.

(Choice E) Rugal thickening with acid hypersecretion is a characteristic finding in the stomach of a patient with Zollinger-Ellison syndrome. Rugal hypertrophy with parietal cell atrophy and decreased acid secretion occurs with Ménétrier disease.

Educational objective:
There are 2 morphological variants of gastric adenocarcinoma. The intestinal type forms a solid mass that projects into the stomach lumen and is composed of glandular-forming cuboidal or columnar cells. In contrast, diffuse carcinoma (linitis plastica) infiltrates the stomach wall and displays signet-ring cells on light microscopy.

References

- Gastric cancer: Classification, histology and application of molecular pathology.

Settings

1
2
3
4
5
6
7
8
9
10
11
12
13
14
15
16
17
18
19
20
21
22
23
24
25
26
27
28
29
30

Item 28 of 40
Question Id: 307

Mark | Previous | Next | Full Screen | Tutorial | Lab Values | Notes | Calculator | Reverse Color | Text Zoom | Settings

Exhibit Display

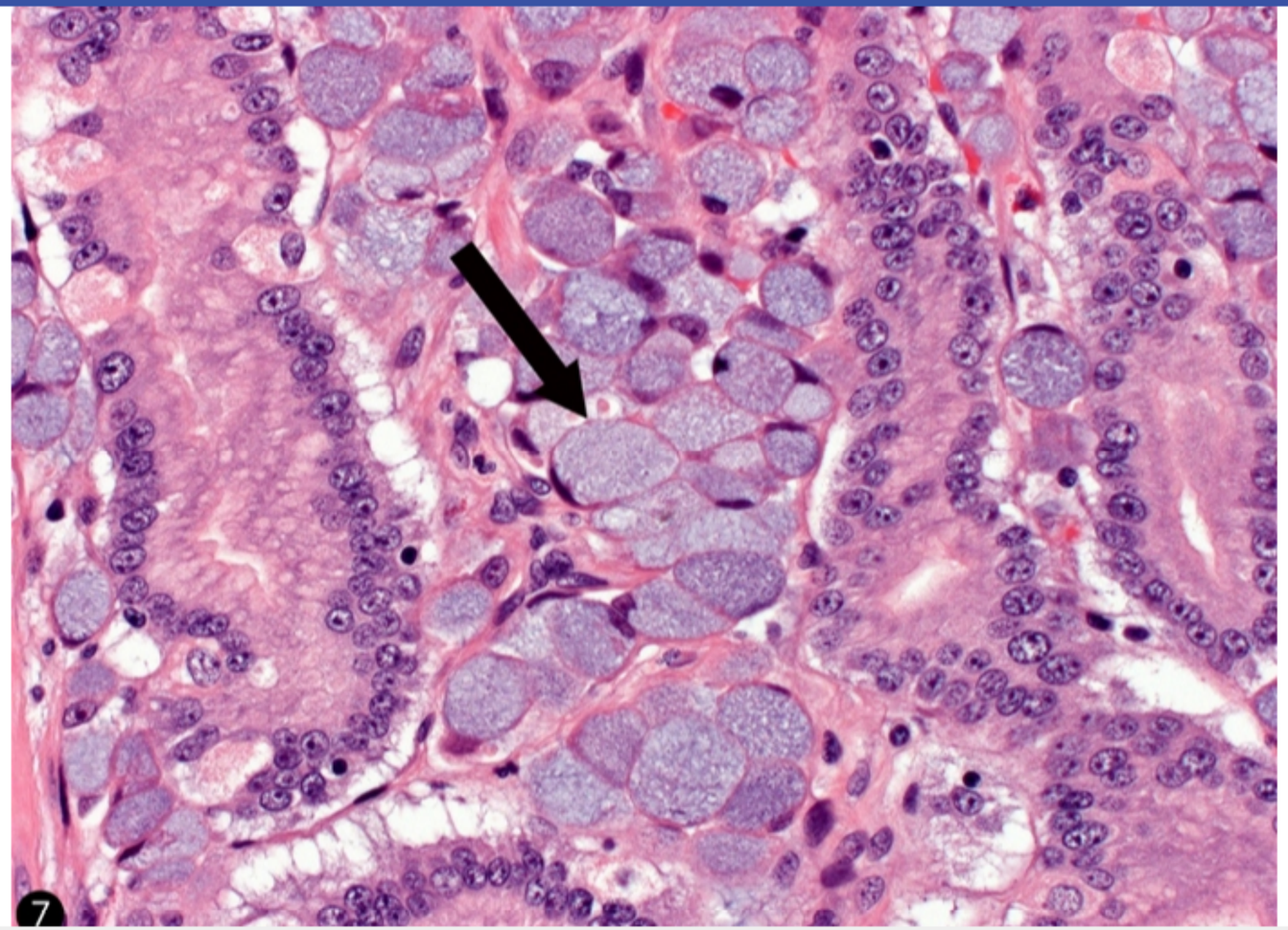

Zoom In | Zoom Out | Reset | Add To New Card | Existing Card

Block Time Remaining: 00:01:14
TUTOR

4 | Feedback | Suspend | End Block

loss of the cell adhesion protein E-cadherin). They have a plaquelike appearance, are ill-defined, and often infiltrate large areas of the stomach wall, causing a "leather-bottle stomach" **(linitis plastica)**.

Intestinal-type adenocarcinomas of the stomach closely resemble colon cancers, showing well-formed glands that consist of columnar or cuboidal cells. They tend to grow as nodular, polypoid, and well-demarcated masses that rapidly expand within the gastric lumen **(Choice D)**. These lesions often ulcerate/bleed and must be differentiated from peptic gastric ulcers by biopsy **(Choice A)**.

The most important factors that influence survival rate with gastric adenocarcinoma are the depth of invasion through the gastric wall and regional lymph node involvement. Metastasis is often present at the time of diagnosis and most commonly involves the **supraclavicular** lymph node (Virchow node) and **periumbilical** nodes (Sister Mary Joseph nodule).

(Choice C) Chronic gastritis is most commonly associated with *Helicobacter pylori* infection. Long-standing inflammation of the gastric mucosa can lead to diffuse gland atrophy and intestinal metaplasia. Chronic gastric inflammation increases the risk of gastric carcinomas.

(Choice E) Rugal thickening with acid hypersecretion is a characteristic finding in the stomach of a patient with Zollinger-Ellison syndrome. Rugal hypertrophy with parietal cell atrophy and decreased acid secretion occurs with Ménétrier disease.

Educational objective:
There are 2 morphological variants of gastric adenocarcinoma. The intestinal type forms a solid mass that projects into the stomach lumen and is composed of glandular-forming cuboidal or columnar cells. In contrast, diffuse carcinoma (linitis plastica) infiltrates the stomach wall and displays signet-ring cells on light microscopy.

References

- Gastric cancer: Classification, histology and application of molecular pathology.
- Pathology and molecular biology of gastric cancer.

Pathology	Gastrointestinal & Nutrition	Gastric cancer
Subject	System	Topic

Copyright © UWorld. All rights reserved.

1 2 3 4 5 6 7 8 9 10 11 12 13 14 15 16 17 18 19 20 21 22 23 24 25 26 27 28 29 30

A 42-year-old man comes to the office due to progressive fatigue, nausea, and itchiness. On review of systems, the patient admits that he occasionally has bloody stools. Medical history is unremarkable. Examination shows scleral icterus. Liver biopsy reveals fibrous obliteration of intrahepatic small bile ducts with concentric replacement by connective tissue. Which of the following is the most likely diagnosis?

A. Autoimmune hepatitis

B. Cytomegalovirus infection

C. Hemochromatosis

D. Primary biliary cholangitis

E. Primary sclerosing cholangitis

Submit

A 42-year-old man comes to the office due to progressive fatigue, nausea, and itchiness. On review of systems, the patient admits that he occasionally has bloody stools. Medical history is unremarkable. Examination shows scleral icterus. Liver biopsy reveals fibrous obliteration of intrahepatic small bile ducts with concentric replacement by connective tissue. Which of the following is the most likely diagnosis?

- A. Autoimmune hepatitis (2%)
- B. Cytomegalovirus infection (0%)
- C. Hemochromatosis (0%)
- D. Primary biliary cholangitis (18%)
- ✓ E. Primary sclerosing cholangitis (77%)

Omitted
Correct answer
E

77%
Answered correctly

01 sec
Time Spent

04/11/2020
Last Updated

Explanation

Autoimmune liver disease			
	Autoimmune hepatitis	**Primary biliary cholangitis**	**Primary sclerosing cholangitis**
Epidemiology	• Female > male	• Female >> male	• Male > female

Autoimmune liver disease

	Autoimmune hepatitis	Primary biliary cholangitis	Primary sclerosing cholangitis
Epidemiology	• Female > male	• Female >> male	• Male > female
Associations	• Other autoimmune disorders	• Other autoimmune disorders	• IBD (particularly UC)
Liver injury pattern	• Hepatocellular (↑ transaminases)	• Cholestatic (↑ alkaline phosphatase)	• Cholestatic (↑ alkaline phosphatase)
Antibodies	• Anti–smooth muscle • Antinuclear*	• Antimitochondrial • Antinuclear*	• ± p-ANCA*
Histology	• Interface hepatitis (portal & periportal lymphoplasmocytic infiltrate)	• Florid duct lesion (granulomatous destruction of small bile ducts)	• Fibrous obliteration of bile ducts with concentric periductal deposition of connective tissue (onion-skin pattern)

*Nonspecific.

IBD = inflammatory bowel disease; **p-ANCA** = perinuclear antineutrophil cytoplasmic antibodies; **UC** = ulcerative colitis.

This patient with fatigue, nausea, pruritus, and scleral icterus has characteristic biopsy findings associated with **primary sclerosing cholangitis** (PSC), a chronic disorder characterized by inflammation, fibrosis, and stricture of the intrahepatic and extrahepatic bile ducts. Histologic features include **fibrous obliteration of the bile ducts** and **concentric periductal deposition of connective tissue**, which resembles an onion skin–like pattern. PSC affects men disproportionately and has a strong association with **ulcerative colitis**, likely explaining this patient's bloody stools.

Manifestations of PSC are related to cholestasis and include **pruritus**, jaundice, and fatigue. Laboratory findings also reflect a **cholestatic pattern of liver injury** and include elevated alkaline phosphatase levels, direct hyperbilirubinemia, and normal to mildly elevated

IBD = inflammatory bowel disease, p-ANCA = perinuclear antineutrophil cytoplasmic antibodies, UC = ulcerative colitis.

This patient with fatigue, nausea, pruritus, and scleral icterus has characteristic biopsy findings associated with **primary sclerosing cholangitis** (PSC), a chronic disorder characterized by inflammation, fibrosis, and stricture of the intrahepatic and extrahepatic bile ducts. Histologic features include **fibrous obliteration of the bile ducts** and **concentric periductal deposition of connective tissue**, which resembles an onion skin–like pattern. PSC affects men disproportionately and has a strong association with **ulcerative colitis**, likely explaining this patient's bloody stools.

Manifestations of PSC are related to cholestasis and include **pruritus**, jaundice, and fatigue. Laboratory findings also reflect a **cholestatic pattern of liver injury** and include elevated alkaline phosphatase levels, direct hyperbilirubinemia, and normal to mildly elevated aminotransferases. Common nonspecific findings include hypergammaglobulinemia and elevated P-ANCA. The diagnosis is confirmed with cholangiography (eg, MR cholangiopancreatography, endoscopic retrograde cholangiopancreatography) demonstrating multifocal bile duct stricture with segmental dilations.

(Choice A) Autoimmune hepatitis can cause fatigue, pruritus, and jaundice but is characterized histologically by portal and periportal lymphoplasmacytic infiltration. It is usually diagnosed in women with other autoimmune conditions (eg, celiac disease).

(Choice B) Cytomegalovirus infection can cause hepatitis; however, microscopy typically reveals large cells with basophilic intracytoplasmic and intranuclear inclusions (eg, owl's eye appearance). In addition, it typically occurs in immunocompromised individuals (eg, transplant patients).

(Choice C) Hemochromatosis leads to excessive hepatic iron storage, which results in visible iron deposits within hepatocytes. It is typically associated with diabetes, skin hyperpigmentation, arthralgias, and cardiomyopathy.

(Choice D) Primary biliary cholangitis also causes cholestasis with jaundice and pruritus; however, it is characterized histologically by inflammation and granulomatous destruction of the small bile ducts (eg, florid duct lesions). In addition, it is much more common in women, and is not usually associated with inflammatory bowel disease.

Educational objective:
Primary sclerosing cholangitis is characterized by inflammation, fibrosis, and stricture of intrahepatic and extrahepatic bile ducts. Histologic findings include fibrous obliteration of bile ducts and periductal concentric connective tissue deposition (eg, onion-skin pattern). Manifestations reflect cholestasis and include jaundice, pruritus, fatigue, and a cholestatic pattern of liver injury (ie, elevated alkaline phosphatase, direct hyperbilirubinemia).

Manifestations of PSC are related to cholestasis and include **pruritus**, jaundice, and fatigue. Laboratory findings also reflect a **cholestatic pattern of liver injury** and include elevated alkaline phosphatase levels, direct hyperbilirubinemia, and normal to mildly elevated aminotransferases. Common nonspecific findings include hypergammaglobulinemia and elevated P-ANCA. The diagnosis is confirmed with cholangiography (eg, MR cholangiopancreatography, endoscopic retrograde cholangiopancreatography) demonstrating multifocal bile duct stricture with segmental dilations.

(Choice A) Autoimmune hepatitis can cause fatigue, pruritus, and jaundice but is characterized histologically by portal and periportal lymphoplasmacytic infiltration. It is usually diagnosed in women with other autoimmune conditions (eg, celiac disease).

(Choice B) Cytomegalovirus infection can cause hepatitis; however, microscopy typically reveals large cells with basophilic intracytoplasmic and intranuclear inclusions (eg, owl's eye appearance). In addition, it typically occurs in immunocompromised individuals (eg, transplant patients).

(Choice C) Hemochromatosis leads to excessive hepatic iron storage, which results in visible iron deposits within hepatocytes. It is typically associated with diabetes, skin hyperpigmentation, arthralgias, and cardiomyopathy.

(Choice D) Primary biliary cholangitis also causes cholestasis with jaundice and pruritus; however, it is characterized histologically by inflammation and granulomatous destruction of the small bile ducts (eg, florid duct lesions). In addition, it is much more common in women, and is not usually associated with inflammatory bowel disease.

Educational objective:
Primary sclerosing cholangitis is characterized by inflammation, fibrosis, and stricture of intrahepatic and extrahepatic bile ducts. Histologic findings include fibrous obliteration of bile ducts and periductal concentric connective tissue deposition (eg, onion-skin pattern). Manifestations reflect cholestasis and include jaundice, pruritus, fatigue, and a cholestatic pattern of liver injury (ie, elevated alkaline phosphatase, direct hyperbilirubinemia).

Pathology	Gastrointestinal & Nutrition	Primary Sclerosing Cholangitis
Subject	System	Topic

Copyright © UWorld. All rights reserved.

A 5-month-old boy is being evaluated for poor weight gain since birth. He is noted to have bulky and greasy stools. A jejunal biopsy shows the findings seen in the slide below.

This patient most likely suffers from which of the following conditions?

- A. Abetalipoproteinemia
- B. Celiac disease
- C. Chronic pancreatitis
- D. Crohn's disease
- E. Lactase deficiency

1 2 3 4 5 6 7 8 9 10 11 12 13 14 15 16 17 18 19 20 21 22 23 24 25 26 27 28 29 30

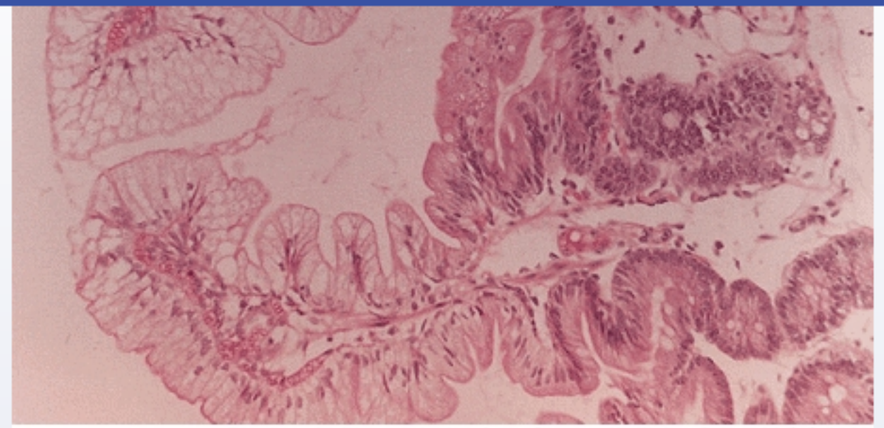

Displayed with permission from Current Medicine Group LLC © 2000.

This patient most likely suffers from which of the following conditions?

- ✓ A. Abetalipoproteinemia (40%)
- B. Celiac disease (24%)
- C. Chronic pancreatitis (3%)
- D. Crohn's disease (3%)
- E. Lactase deficiency (12%)
- F. Whipple disease (14%)
- G. Zollinger-Ellison syndrome (1%)

Omitted
Correct answer

40%
Answered correctly

05 secs
Time Spent

02/20/2020
Last Updated

Explanation

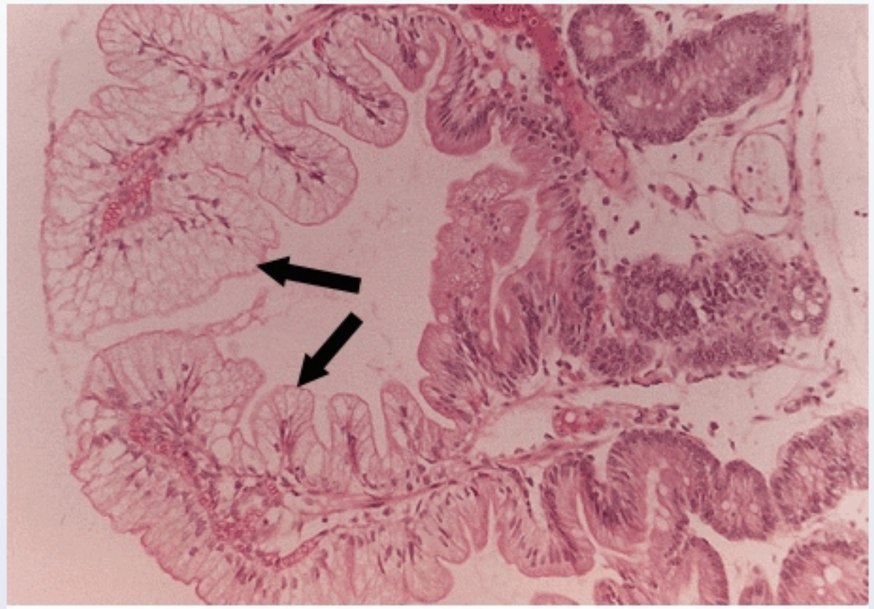

Displayed with permission from Current Medicine Group LLC © 2000.

The slide above shows normal intestinal mucosal architecture, but the enterocytes contain clear or foamy cytoplasm (arrows) which is more prominent at the tips of the villi. These findings occur due to accumulation of lipids in the absorptive cells of the intestinal epithelium and are typical of abetalipoproteinemia, a disease caused by impaired formation of apolipoprotein B (apoB)-containing lipoproteins.

Dietary lipids are normally processed in small-bowel enterocytes and secreted as chylomicrons; endogenously produced lipids are secreted from liver hepatocytes as very low-density lipoprotein (VLDL). Chylomicron and VLDL particles are synthesized within the endoplasmic reticulum as lipids accumulate around a single apoB molecule. ApoB-100 is found in VLDL, and apoB-48 (a truncated version without the LDL receptor ligand) is present in chylomicrons. During the synthesis of apoB-containing lipoproteins, microsomal triglyceride transfer protein (MTP) functions as a chaperone protein necessary for proper folding of apoB and also participates in the transfer of lipids to newly formed chylomicrons and VLDL particles.

The slide above shows normal intestinal mucosal architecture, but the enterocytes contain clear or foamy cytoplasm (arrows) which is more prominent at the tips of the villi. These findings occur due to accumulation of lipids in the absorptive cells of the intestinal epithelium and are typical of abetalipoproteinemia, a disease caused by impaired formation of apolipoprotein B (apoB)-containing lipoproteins.

Dietary lipids are normally processed in small-bowel enterocytes and secreted as chylomicrons; endogenously produced lipids are secreted from liver hepatocytes as very low-density lipoprotein (VLDL). Chylomicron and VLDL particles are synthesized within the endoplasmic reticulum as lipids accumulate around a single apoB molecule. ApoB-100 is found in VLDL, and apoB-48 (a truncated version without the LDL receptor ligand) is present in chylomicrons. During the synthesis of apoB-containing lipoproteins, microsomal triglyceride transfer protein (MTP) functions as a chaperone protein necessary for proper folding of apoB and also participates in the transfer of lipids to newly formed chylomicrons and VLDL particles.

Abetalipoproteinemia is most commonly caused by an autosomal recessive, loss-of-function mutation in the **MTP gene**. It manifests during the first year of life with symptoms of malabsorption (eg, abdominal distention, foul-smelling stool). Laboratory studies show very low plasma triglyceride and cholesterol levels, and chylomicrons, VLDLs, and apoB are entirely absent from the blood. Poor lipid absorption causes deficiency of fat-soluble vitamins (particularly vitamin E) and essential fatty acids. This results in red blood cells with abnormal membranes and thorny projections called **acanthocytes** as well as multiple **neurologic abnormalities** (eg, progressive ataxia, retinitis pigmentosa).

(Choice B) Light microscopy shows atrophy and blunting of the villi in celiac disease. Chronic inflammatory infiltrate of the lamina propria is also present. None of these features are seen in the slide above.

(Choices C, E, and G) No abnormalities are found on light microscopy of the small intestine in chronic pancreatitis, Zollinger-Ellison syndrome, or lactase deficiency.

(Choice D) Light microscopy in Crohn's disease shows chronic inflammation of all layers of the intestinal wall and noncaseating granulomas.

(Choice F) The characteristic microscopic finding in Whipple disease is distended macrophages in the lamina propria of the small intestine. Macrophages contain PAS-positive and diastase-resistant granules and rod-shaped *Tropheryma whippelii* bacilli.

Educational objective:
Abetalipoproteinemia is an inherited inability to synthesize apolipoprotein B, an important component of chylomicrons and very low-density lipoprotein. Lipids absorbed by the small intestine cannot be transported into the blood and accumulate in the intestinal epithelium, resulting in enterocytes with clear or foamy cytoplasm.

is present in chylomicrons. During the synthesis of apoB-containing lipoproteins, microsomal triglyceride transfer protein (MTP) functions as a chaperone protein necessary for proper folding of apoB and also participates in the transfer of lipids to newly formed chylomicrons and VLDL particles.

Abetalipoproteinemia is most commonly caused by an autosomal recessive, loss-of-function mutation in the **MTP gene**. It manifests during the first year of life with symptoms of malabsorption (eg, abdominal distention, foul-smelling stool). Laboratory studies show very low plasma triglyceride and cholesterol levels, and chylomicrons, VLDLs, and apoB are entirely absent from the blood. Poor lipid absorption causes deficiency of fat-soluble vitamins (particularly vitamin E) and essential fatty acids. This results in red blood cells with abnormal membranes and thorny projections called **acanthocytes** as well as multiple **neurologic abnormalities** (eg, progressive ataxia, retinitis pigmentosa).

(Choice B) Light microscopy shows atrophy and blunting of the villi in celiac disease. Chronic inflammatory infiltrate of the lamina propria is also present. None of these features are seen in the slide above.

(Choices C, E, and G) No abnormalities are found on light microscopy of the small intestine in chronic pancreatitis, Zollinger-Ellison syndrome, or lactase deficiency.

(Choice D) Light microscopy in Crohn's disease shows chronic inflammation of all layers of the intestinal wall and noncaseating granulomas.

(Choice F) The characteristic microscopic finding in Whipple disease is distended macrophages in the lamina propria of the small intestine. Macrophages contain PAS-positive and diastase-resistant granules and rod-shaped *Tropheryma whippelii* bacilli.

Educational objective:
Abetalipoproteinemia is an inherited inability to synthesize apolipoprotein B, an important component of chylomicrons and very low-density lipoprotein. Lipids absorbed by the small intestine cannot be transported into the blood and accumulate in the intestinal epithelium, resulting in enterocytes with clear or foamy cytoplasm.

Pathology	Gastrointestinal & Nutrition	Abetalipoproteinemia
Subject	System	Topic

Copyright © UWorld. All rights reserved.

is present in chylomicrons. During the synthesis of apoB-containing lipoproteins, microsomal triglyceride transfer protein (MTP) functions as a

Exhibit Display

Crohn's disease Crohn's disease

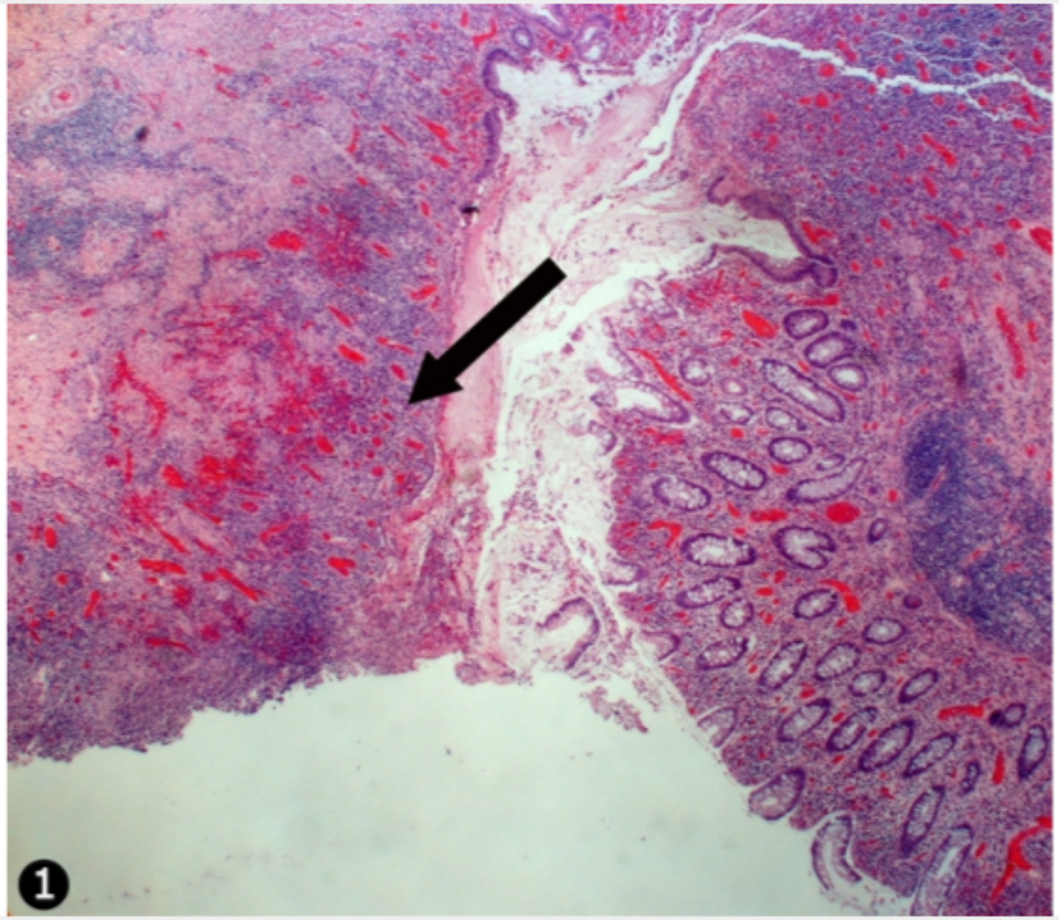

Zoom In | Zoom Out | Reset | Add To New Card | Existing Card

is present in chylomicrons. During the synthesis of apoB-containing lipoproteins, microsomal triglyceride transfer protein (MTP) functions as a

Exhibit Display

Crohn's disease Crohn's disease

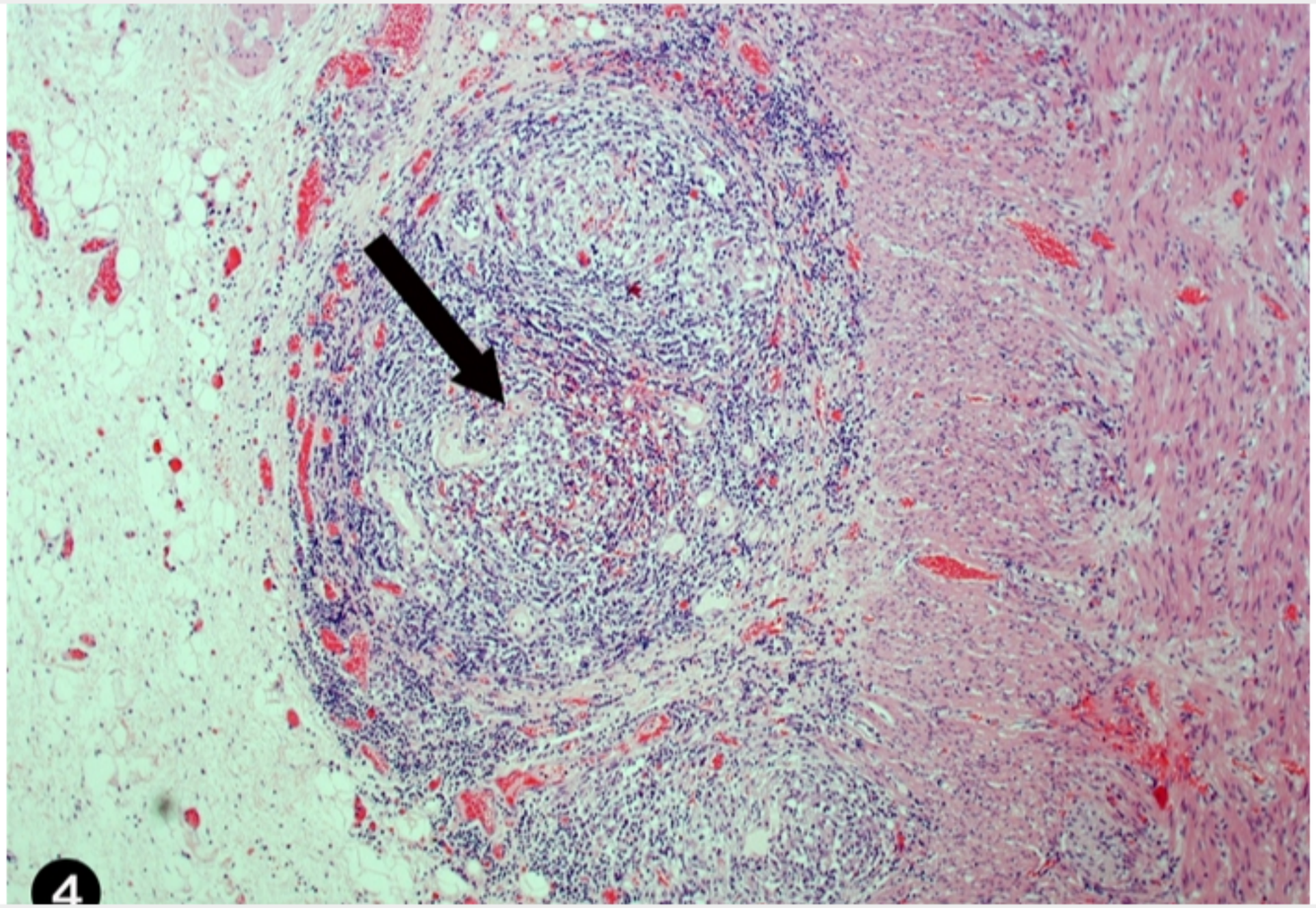

Zoom In | Zoom Out | Reset | Add To New Card | Existing Card

is present in chylomicrons. During the synthesis of apoB-containing lipoproteins, microsomal triglyceride transfer protein (MTP) functions as a

Exhibit Display

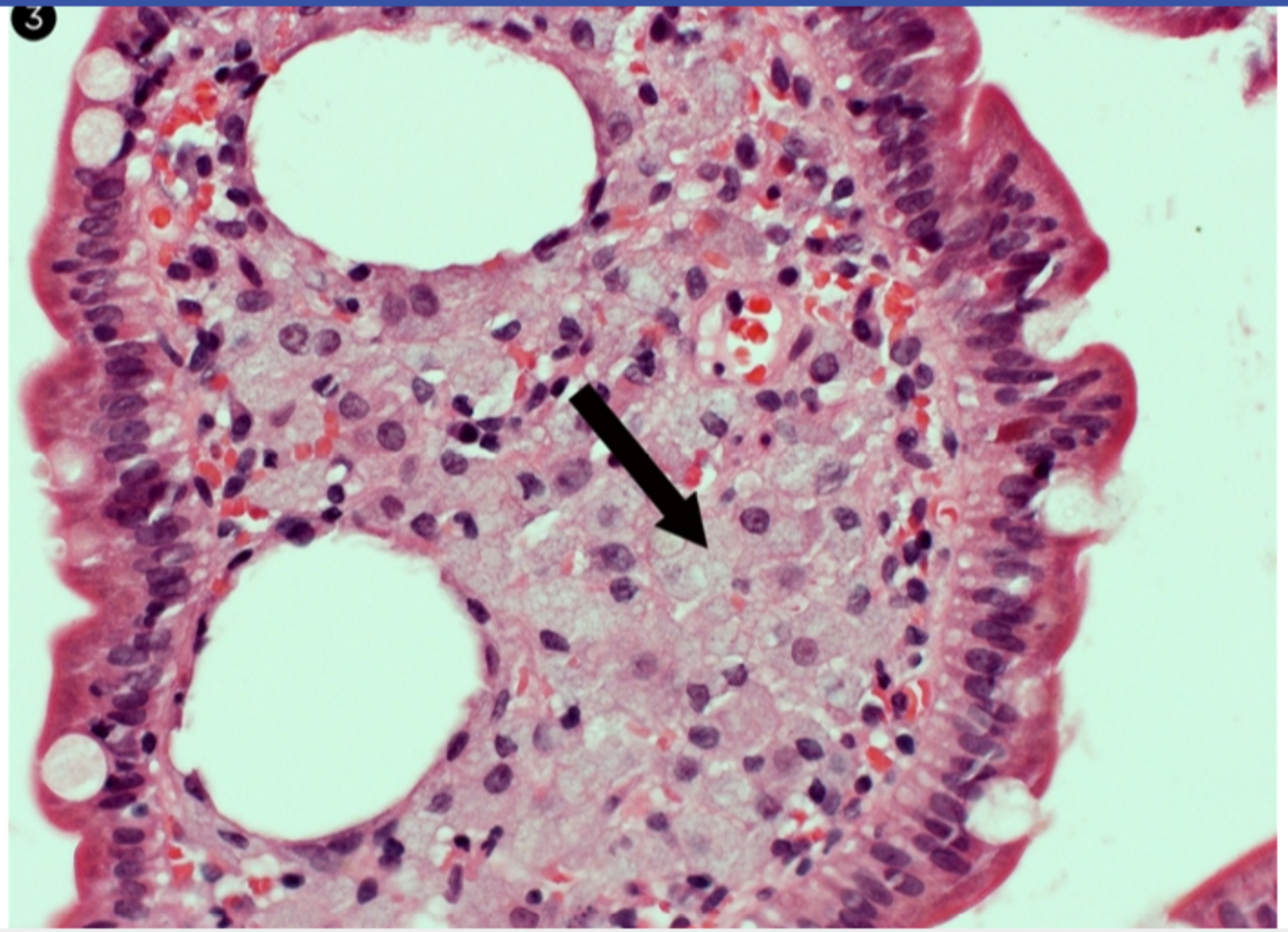

Zoom In | Zoom Out | Reset | Add To New Card | Existing Card

A 72-year-old woman comes to the office for follow-up on abdominal pain. She has had several episodes of left lower quadrant pain requiring hospitalization. Despite treatment, her symptoms continue to recur. Elective surgery is performed and a segment of resected and opened sigmoid colon is shown below.

Which of the following most likely contributed to this patient's condition?

A. Consumption of high-residue foods

B. Frequent consumption of seeds and nuts

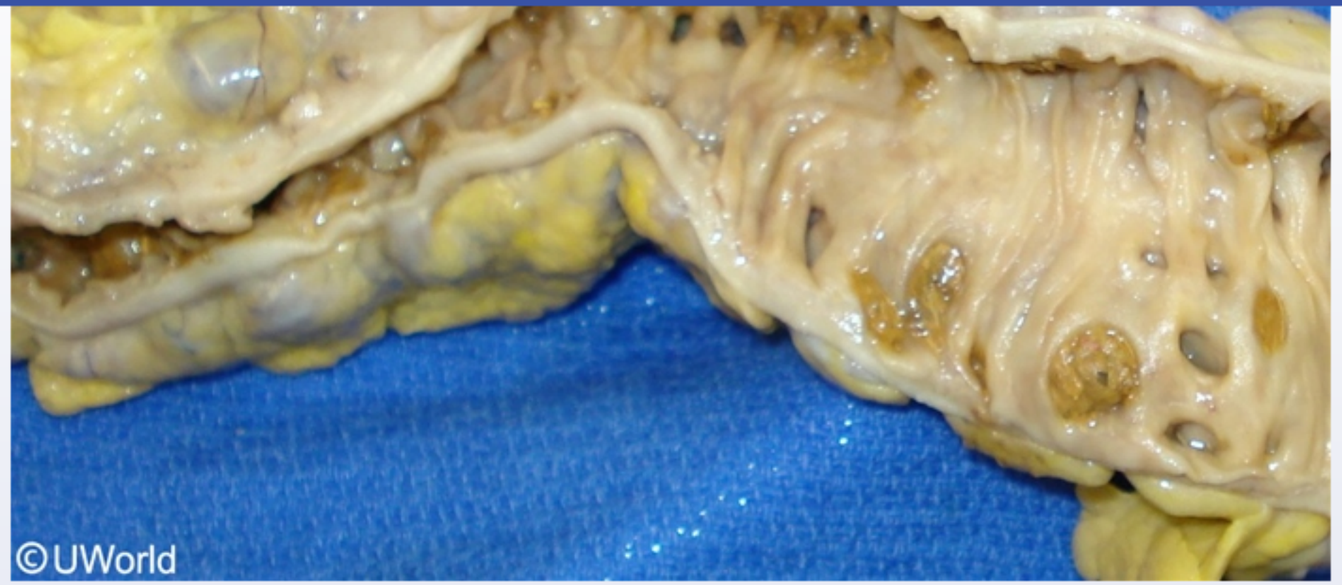

Which of the following most likely contributed to this patient's condition?

- A. Consumption of high-residue foods
- B. Frequent consumption of seeds and nuts
- C. High dietary intake of fat and red meat
- D. Infection with *Helicobacter pylori*
- E. Prolonged and excessive alcohol intake

Submit

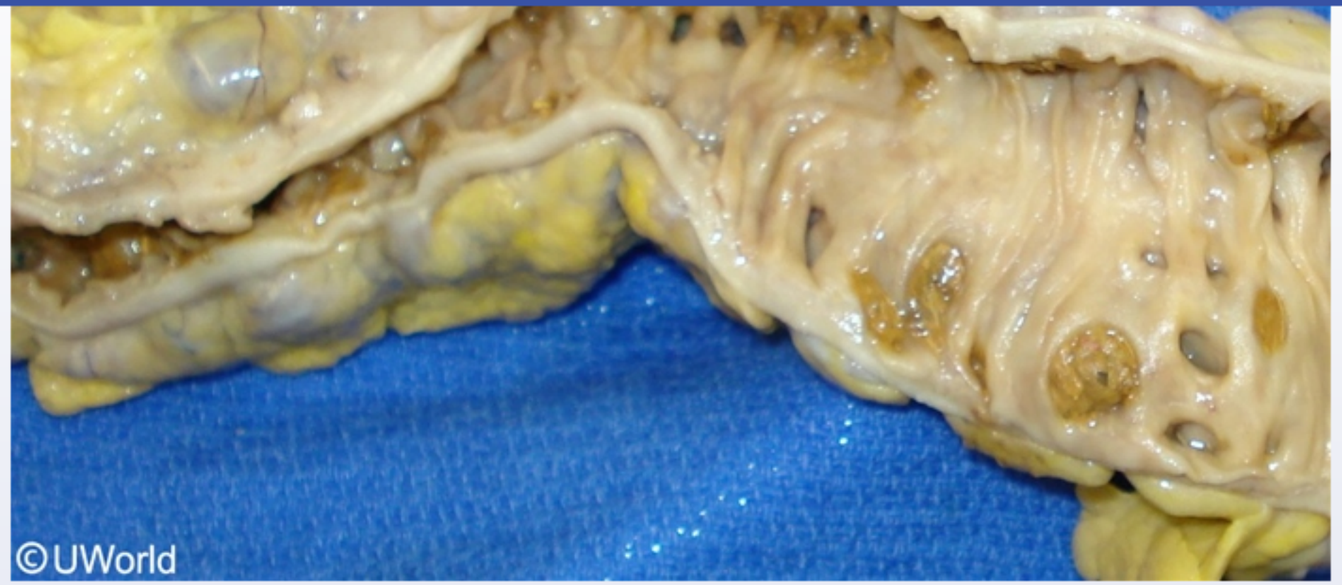

Which of the following most likely contributed to this patient's condition?

- A. Consumption of high-residue foods (13%)
- B. Frequent consumption of seeds and nuts (14%)
- ✓ C. High dietary intake of fat and red meat (67%)
- D. Infection with *Helicobacter pylori* (1%)
- E. Prolonged and excessive alcohol intake (3%)

Omitted
Correct answer

67%
Answered correctly

05 secs
Time Spent

02/11/2020
Last Updated

Diverticular disease	
Etiology	• Diverticulosis: ↑ intraluminal pressure causing herniation through points of weakness (vasa recta penetration) • Diverticular bleeding: injury to exposed vasa recta • Diverticulitis: trapped food particles & ↑ intraluminal pressure causing microperforation
Symptoms	• Diverticulosis: none • Diverticular bleeding: painless hematochezia • Diverticulitis: left lower quadrant pain, nausea, vomiting, fever
Risk factors	• Diet high in red meat & fat & low in fiber • Obesity, physical inactivity, smoking

This patient's gross pathology demonstrates multiple sac-like outpouchings from the sigmoid colon, which is consistent with diverticulosis. **Diverticulosis** occurs due to excessive colonic contractions that cause increased intraluminal pressure; this forces the mucosa and submucosa to herniate through the muscularis at naturally weak areas where the vasa recta penetrate. It is an exceedingly common disorder, particularly in Western nations, and its incidence increases with age.

Diverticulosis may be clinically silent, but up to 30% of patients develop complications, including diverticular bleeding and diverticulitis. **Diverticular bleeding** occurs with injury to the exposed vasa recta within the colonic lumen and typically presents with **painless hematochezia**. **Diverticulitis** is caused by trapped food particles or excessive intraluminal pressure within the diverticula, leading to focal necrosis and microperforation. Patients develop **abdominal pain** (usually in the **left lower quadrant**), fever, nausea and vomiting, and alterations in bowel habits (eg, diarrhea, constipation). Diverticulitis is typically managed with antibiotics and bowel rest; however, surgery may be required for recurrent disease.

The risk for diverticular disease is increased by dietary factors, including **diets high in red meat**, high in **fat**, and **low in residue** (eg, fiber). Other risk factors include obesity, physical inactivity, and smoking. Patients who adhere to a low-risk lifestyle have a 50% lower risk of diverticulitis

Diverticular bleeding occurs with injury to the exposed vasa recta within the colonic lumen and typically presents with **painless hematochezia**. **Diverticulitis** is caused by trapped food particles or excessive intraluminal pressure within the diverticula, leading to focal necrosis and microperforation. Patients develop **abdominal pain** (usually in the **left lower quadrant**), fever, nausea and vomiting, and alterations in bowel habits (eg, diarrhea, constipation). Diverticulitis is typically managed with antibiotics and bowel rest; however, surgery may be required for recurrent disease.

The risk for diverticular disease is increased by dietary factors, including **diets high in red meat**, high in **fat**, and **low in residue** (eg, fiber). Other risk factors include obesity, physical inactivity, and smoking. Patients who adhere to a low-risk lifestyle have a 50% lower risk of diverticulitis **(Choice A)**.

(Choice B) Although previously thought to be associated with diverticular diseases, the ingestion of nuts, seeds, and popcorn is not correlated with increased risk of diverticulosis, diverticular bleeding, or diverticulitis.

(Choice D) *Helicobacter pylori* infection is associated with peptic ulcer and gastric cancer but does not increase the risk of diverticular disease.

(Choice E) Excessive alcohol intake is associated with liver cirrhosis and squamous cell carcinoma of the esophagus; it is not associated with diverticular disease.

Educational objective:
Colonic diverticulosis refers to multiple sac-like outpouchings within the sigmoid colon. Complications include diverticular bleeding and diverticulitis. Risk factors for diverticulosis include a diet high in red meat and fat and low in fiber, as well as obesity, physical inactivity, and smoking.

References

- Diagnosis and management of acute diverticulitis.

Pathology	Gastrointestinal & Nutrition	Diverticular disease
Subject	System	Topic

Copyright © UWorld. All rights reserved.

A 63-year-old man comes to the office due to several months of dysphagia, fatigue, occasional chest discomfort, and indigestion. He has a history of hypertension and takes amlodipine. The patient smokes 1 or 2 cigars daily. His blood pressure is 140/80 mm Hg. Physical examination is normal. An endoscopic evaluation with esophageal biopsy is performed. The histopathology of the specimen is shown in the image below.

Which of the following is the most likely cause of this patient's dysphagia?

- A. Benign tumor with slow growth
- B. Malignancy with probable poor prognosis
- C. Metaplasia with increased risk of adenocarcinoma
- D. Motor dysfunction with increased risk of carcinoma
- E. Reflux esophagitis with high risk of metaplasia

Submit

of hypertension and takes amlodipine. The patient smokes 1 or 2 cigars daily. His blood pressure is 140/80 mm Hg. Physical examination is normal. An endoscopic evaluation with esophageal biopsy is performed. The histopathology of the specimen is shown in the image below.

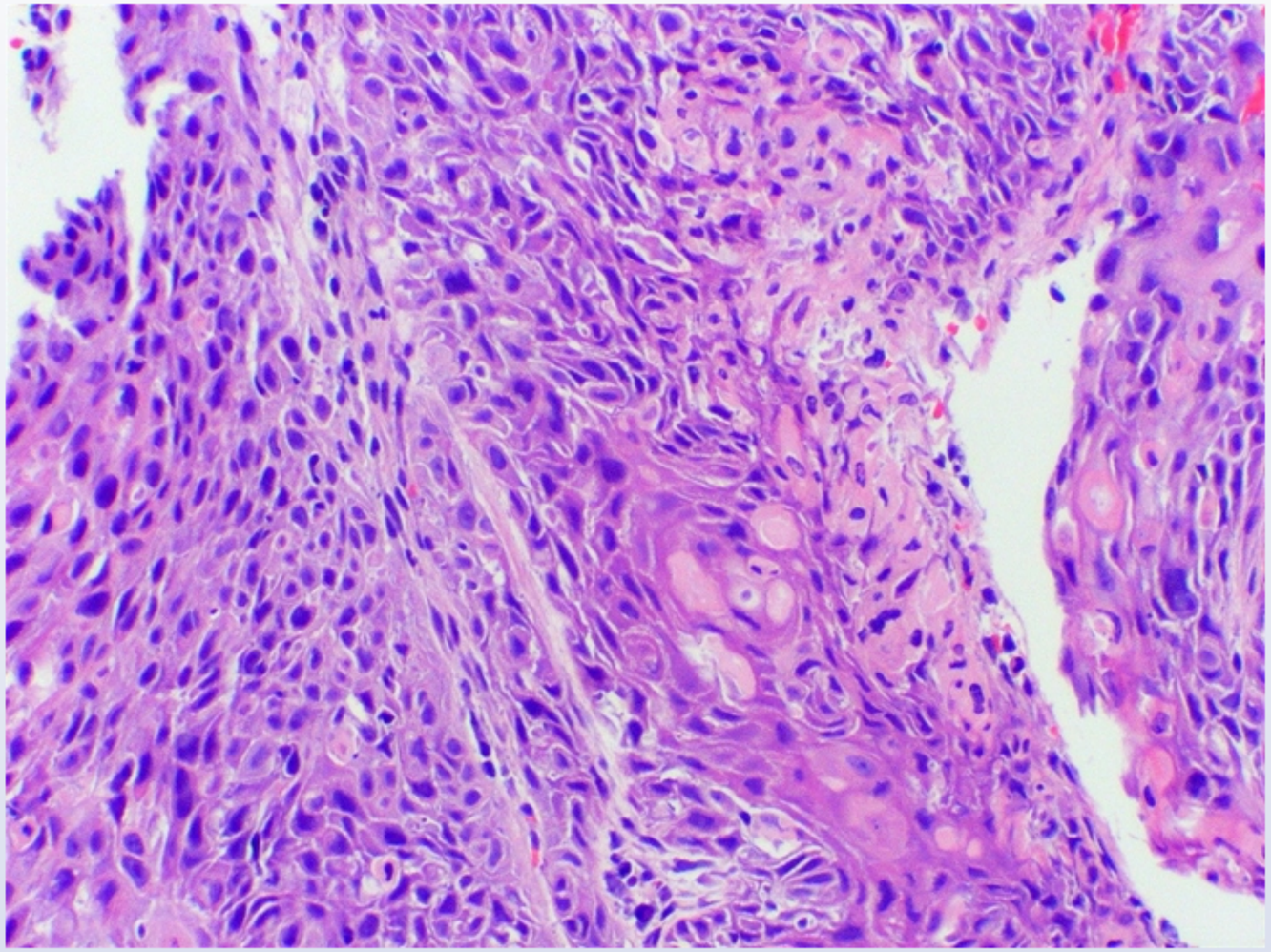

Which of the following is the most likely cause of this patient's dysphagia?

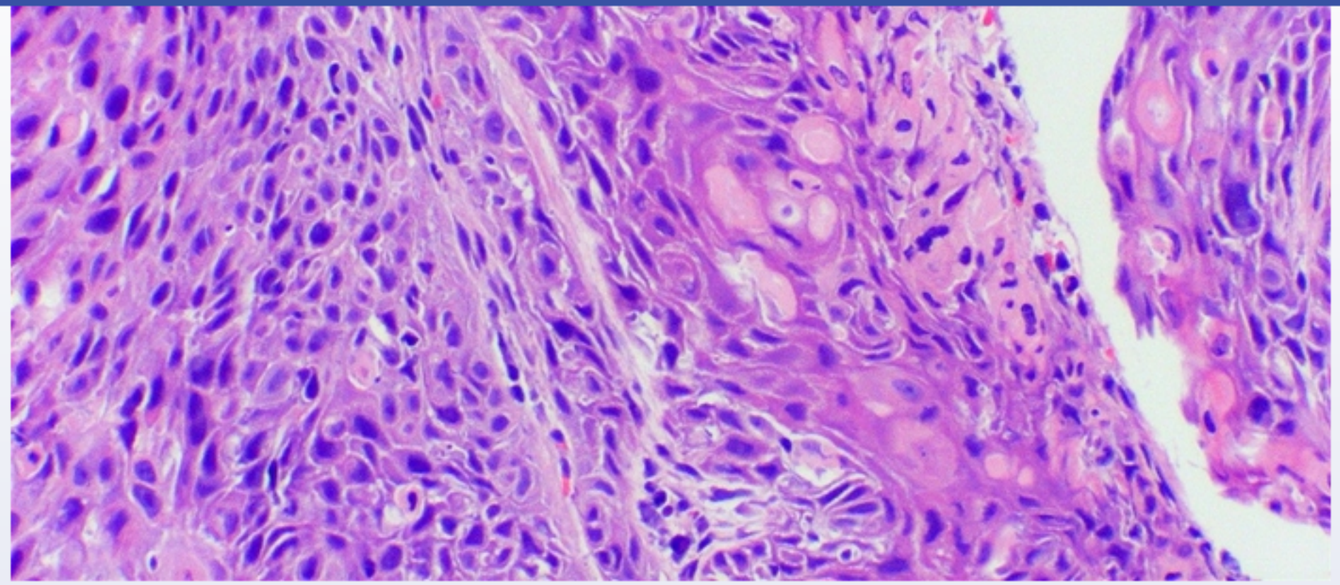

Which of the following is the most likely cause of this patient's dysphagia?

A. Benign tumor with slow growth

B. Malignancy with probable poor prognosis

C. Metaplasia with increased risk of adenocarcinoma

D. Motor dysfunction with increased risk of carcinoma

E. Reflux esophagitis with high risk of metaplasia

Submit

1 2 3 4 5 6 7 8 9 10 11 12 13 14 15 16 17 18 19 20 21 22 23 24 25 26 27 28 29 30

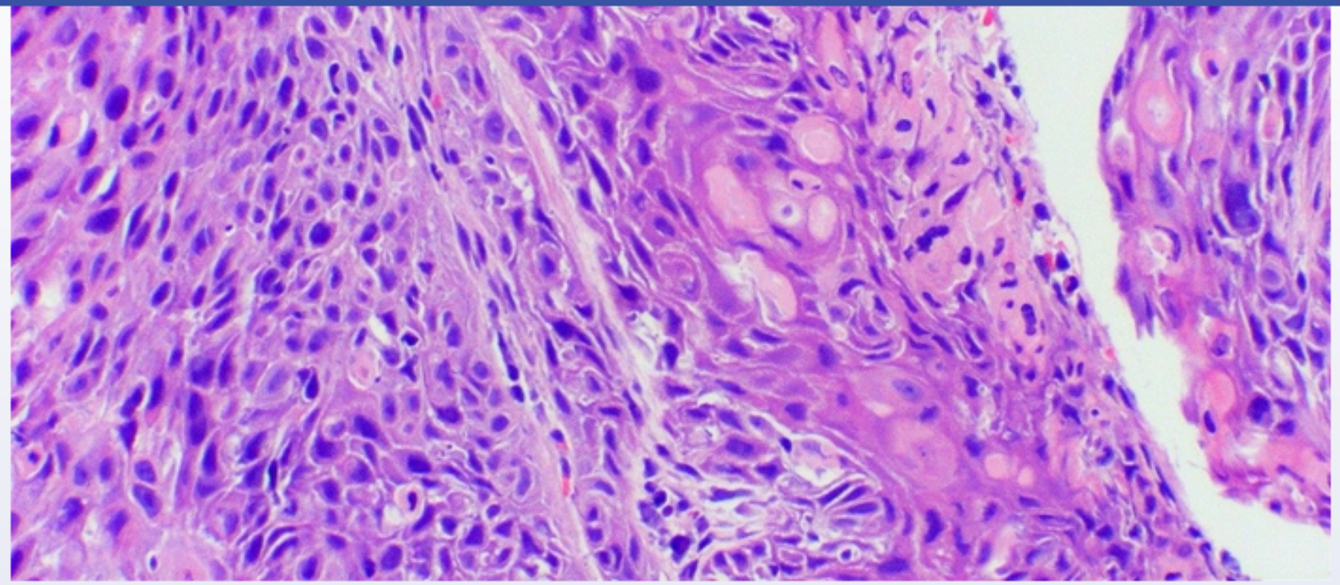

Which of the following is the most likely cause of this patient's dysphagia?

- A. Benign tumor with slow growth (1%)
- ✓ B. Malignancy with probable poor prognosis (57%)
- C. Metaplasia with increased risk of adenocarcinoma (28%)
- D. Motor dysfunction with increased risk of carcinoma (3%)
- E. Reflux esophagitis with high risk of metaplasia (8%)

Omitted
Correct answer

57%
Answered correctly

06 secs
Time Spent

01/17/2020
Last Updated

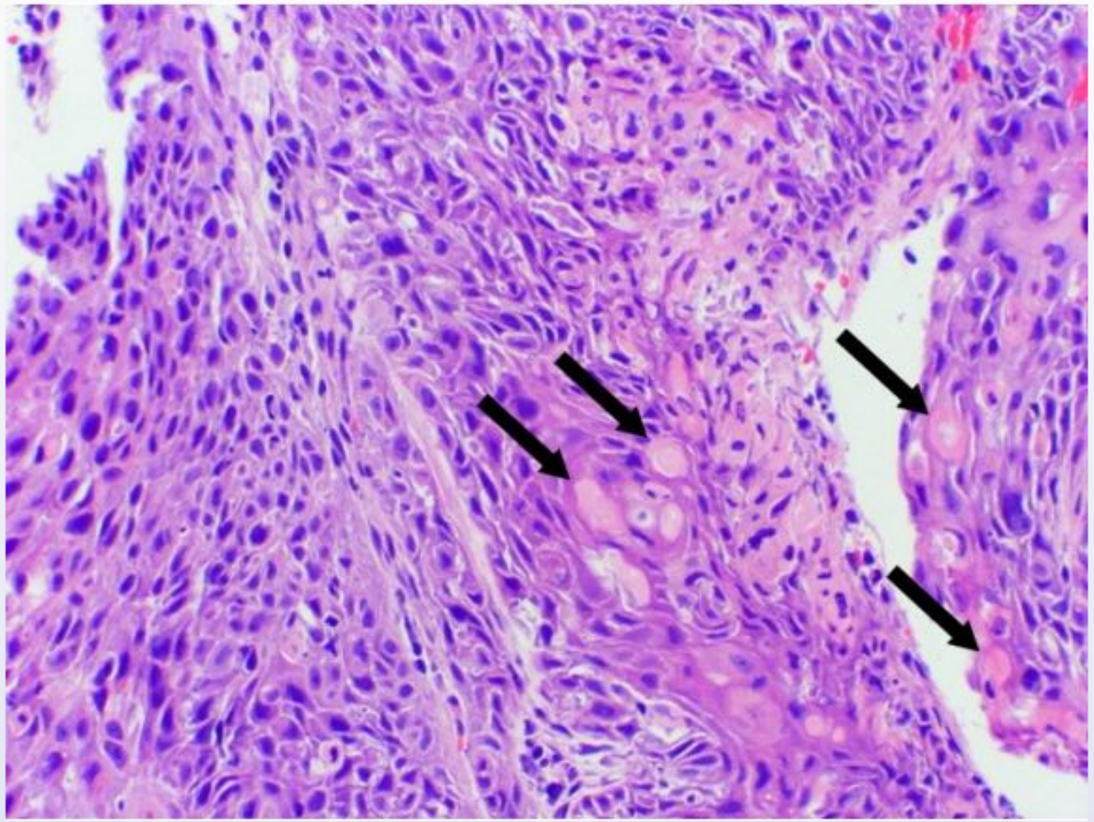

This patient's biopsy is consistent with **esophageal squamous cell carcinoma** (SCC). The histopathologic features of this condition include solid nests of neoplastic squamous cells with abundant eosinophilic cytoplasm and distinct borders (compared to normal esophagus). Areas of **keratinization** (arrows) are easily identified (keratin pearls), and the presence of intercellular bridges is also characteristic of squamous differentiation.

Most cases of esophageal SCC occur in men age >50 with a history of prolonged smoking and alcohol use. Patients typically present with solid food **dysphagia** as the tumor gradually obstructs the esophageal lumen, which can progress to liquid dysphagia. Retrosternal discomfort/burning and significant **weight loss** are also common. Chronic gastrointestinal blood loss may result in iron deficiency anemia with fatigue. The

This patient's biopsy is consistent with **esophageal squamous cell carcinoma** (SCC). The histopathologic features of this condition include solid nests of neoplastic squamous cells with abundant eosinophilic cytoplasm and distinct borders (compared to normal esophagus). Areas of **keratinization** (arrows) are easily identified (keratin pearls), and the presence of intercellular bridges is also characteristic of squamous differentiation.

Most cases of esophageal SCC occur in men age >50 with a history of prolonged smoking and alcohol use. Patients typically present with solid food **dysphagia** as the tumor gradually obstructs the esophageal lumen, which can progress to liquid dysphagia. Retrosternal discomfort/burning and significant **weight loss** are also common. Chronic gastrointestinal blood loss may result in iron deficiency anemia with fatigue. The prognosis for esophageal cancer is generally poor as many patients present with incurable locally advanced or metastatic disease.

(Choice A) Benign tumors of the esophagus (most commonly leiomyomas) are rare and slow growing. On light microscopy, leiomyomas consist of fascicles of spindle cells with variable amounts of fibrosis.

(Choices C and E) Reflux esophagitis commonly occurs due to gastroesophageal reflux disease and is characterized histologically by elongation of the papillae, basal cell hypertrophy, and intraepithelial eosinophils (arrows). Repeated epithelial injury caused by reflux esophagitis may lead to Barrett esophagus, which is characterized by intestinal metaplasia with goblet cells. Barrett esophagus is a premalignant condition that significantly increases the risk of esophageal adenocarcinoma.

(Choice D) Achalasia is an esophageal motility disorder characterized by failed relaxation of the lower esophageal sphincter resulting in food retention, dilation of the esophageal body, and symptoms of solid/liquid dysphagia. Achalasia increases the risk of squamous cell carcinoma of the esophagus.

Educational objective:
The histopathologic features of esophageal squamous cell carcinoma include solid nests of neoplastic squamous cells with abundant eosinophilic cytoplasm and distinct borders. Areas of keratinization and the presence of intercellular bridges are also characteristic. Patients typically present with progressive solid and eventually liquid dysphagia and weight loss.

References

- Distinctive clinicopathological characteristics in esophageal squamous cell carcinoma.

Settings

1 2 3 4 5 6 7 8 9 10 11 12 13 14 15 16 17 18 19 20 21 22 23 24 25 26 27 28 29 30

Item 32 of 40
Question Id: 287

Mark | Previous | Next | Full Screen | Tutorial | Lab Values | Notes | Calculator | Reverse Color | Text Zoom | Settings

This patient's biopsy is consistent with **esophageal squamous cell carcinoma** (SCC). The histopathologic features of this condition include solid

Exhibit Display

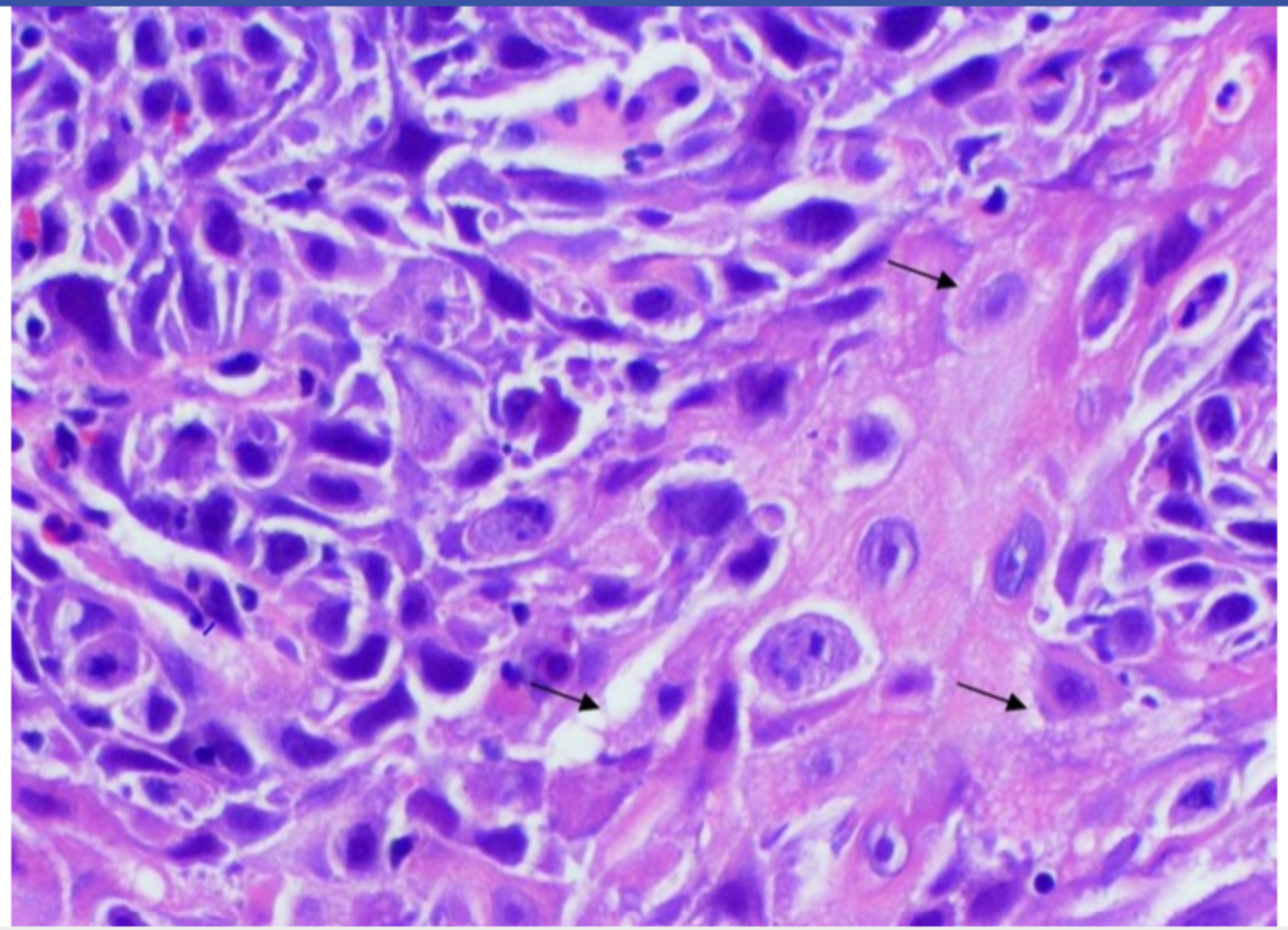

Zoom In | Zoom Out | Reset | Add To New Card | Existing Card

Block Time Remaining: 00:01:31
TUTOR

7 | Feedback | Suspend | End Block

Settings

1 2 3 4 5 6 7 8 9 10 11 12 13 14 15 16 17 18 19 20 21 22 23 24 25 26 27 28 29 30

Item 32 of 40
Question Id: 287

Mark | Previous | Next | Full Screen | Tutorial | Lab Values | Notes | Calculator | Reverse Color | Text Zoom | Settings

This patient's biopsy is consistent with **esophageal squamous cell carcinoma** (SCC). The histopathologic features of this condition include solid

Exhibit Display

Reflux Esophagitis Reflux esophagitis Reflux Esophagitis

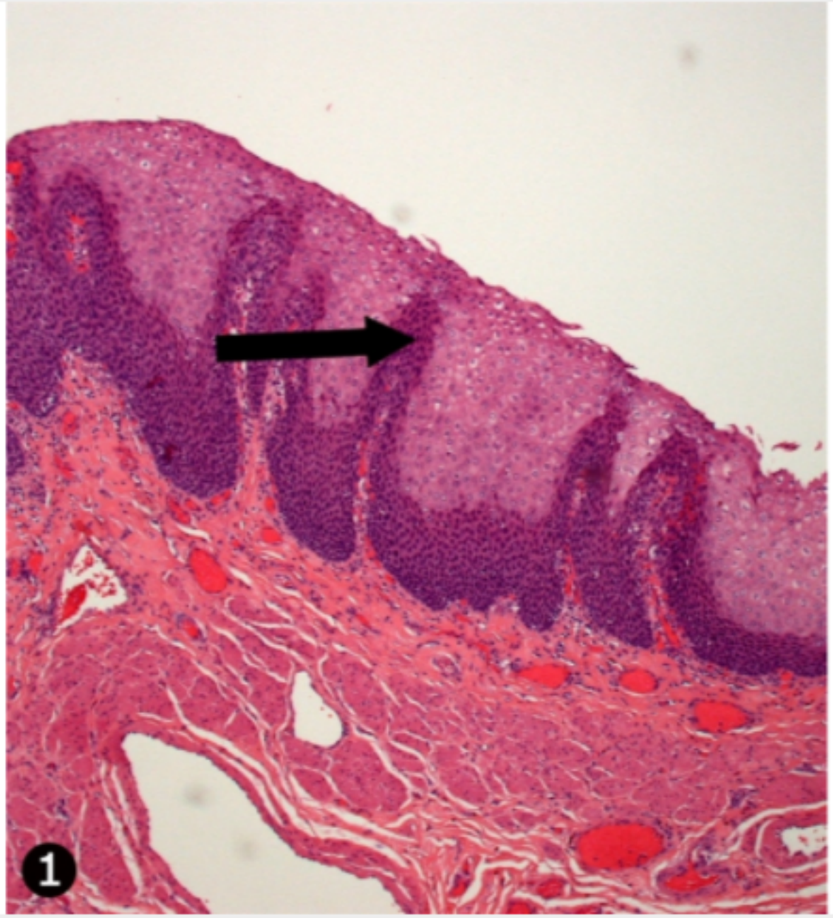

Zoom In | Zoom Out | Reset | Add To New Card | Existing Card

Block Time Remaining: 00:01:31
TUTOR

7 | Feedback | Suspend | End Block

Settings

1 2 3 4 5 6 7 8 9 10 11 12 13 14 15 16 17 18 19 20 21 22 23 24 25 26 27 28 29 30

Item 32 of 40
Question Id: 287

Mark | Previous | Next | Full Screen | Tutorial | Lab Values | Notes | Calculator | Reverse Color | Text Zoom | Settings

This patient's biopsy is consistent with **esophageal squamous cell carcinoma** (SCC). The histopathologic features of this condition include solid

Exhibit Display

Reflux Esophagitis Reflux esophagitis Reflux Esophagitis

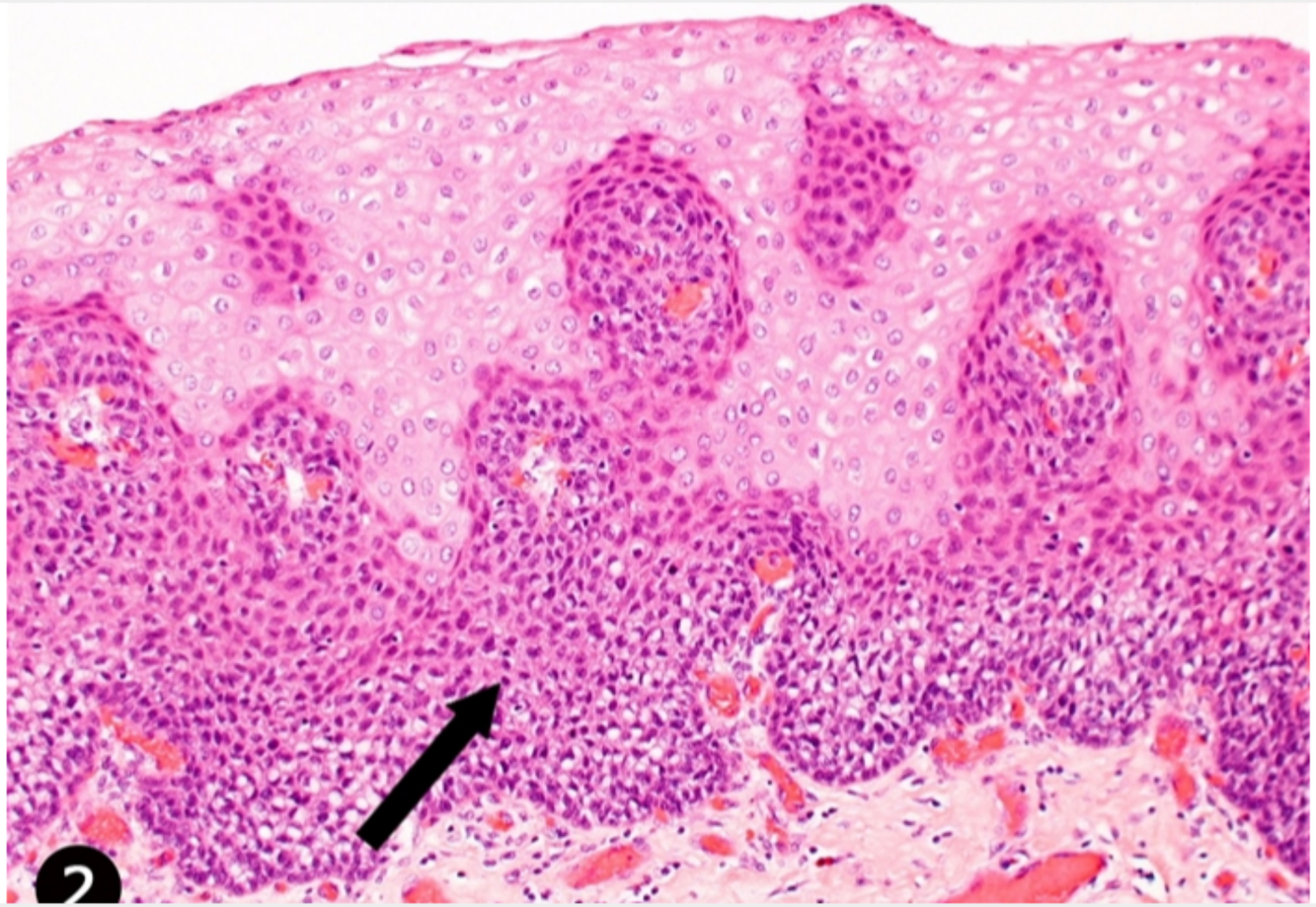

Zoom In | Zoom Out | Reset | Add To New Card | Existing Card

Block Time Remaining: 00:01:31
TUTOR

7 | Feedback | Suspend | End Block

Settings

1 2 3 4 5 6 7 8 9 10 11 12 13 14 15 16 17 18 19 20 21 22 23 24 25 26 27 28 29 30

Item 32 of 40
Question Id: 287

Mark | Previous | Next | Full Screen | Tutorial | Lab Values | Notes | Calculator | Reverse Color | Text Zoom | Settings

This patient's biopsy is consistent with **esophageal squamous cell carcinoma** (SCC). The histopathologic features of this condition include solid

Exhibit Display

Reflux Esophagitis Reflux esophagitis Reflux Esophagitis

Zoom In | Zoom Out | Reset | Add To New Card | Existing Card

Block Time Remaining: 00:01:31
TUTOR

7 | Feedback | Suspend | End Block

Settings

1 2 3 4 5 6 7 8 9 10 11 12 13 14 15 16 17 18 19 20 21 22 23 24 25 26 27 28 29 30

Item 32 of 40
Question Id: 287

Mark | Previous | Next | Full Screen | Tutorial | Lab Values | Notes | Calculator | Reverse Color | Text Zoom | Settings

This patient's biopsy is consistent with **esophageal squamous cell carcinoma** (SCC). The histopathologic features of this condition include solid

Exhibit Display

Reflux Esophagitis Reflux esophagitis Reflux Esophagitis

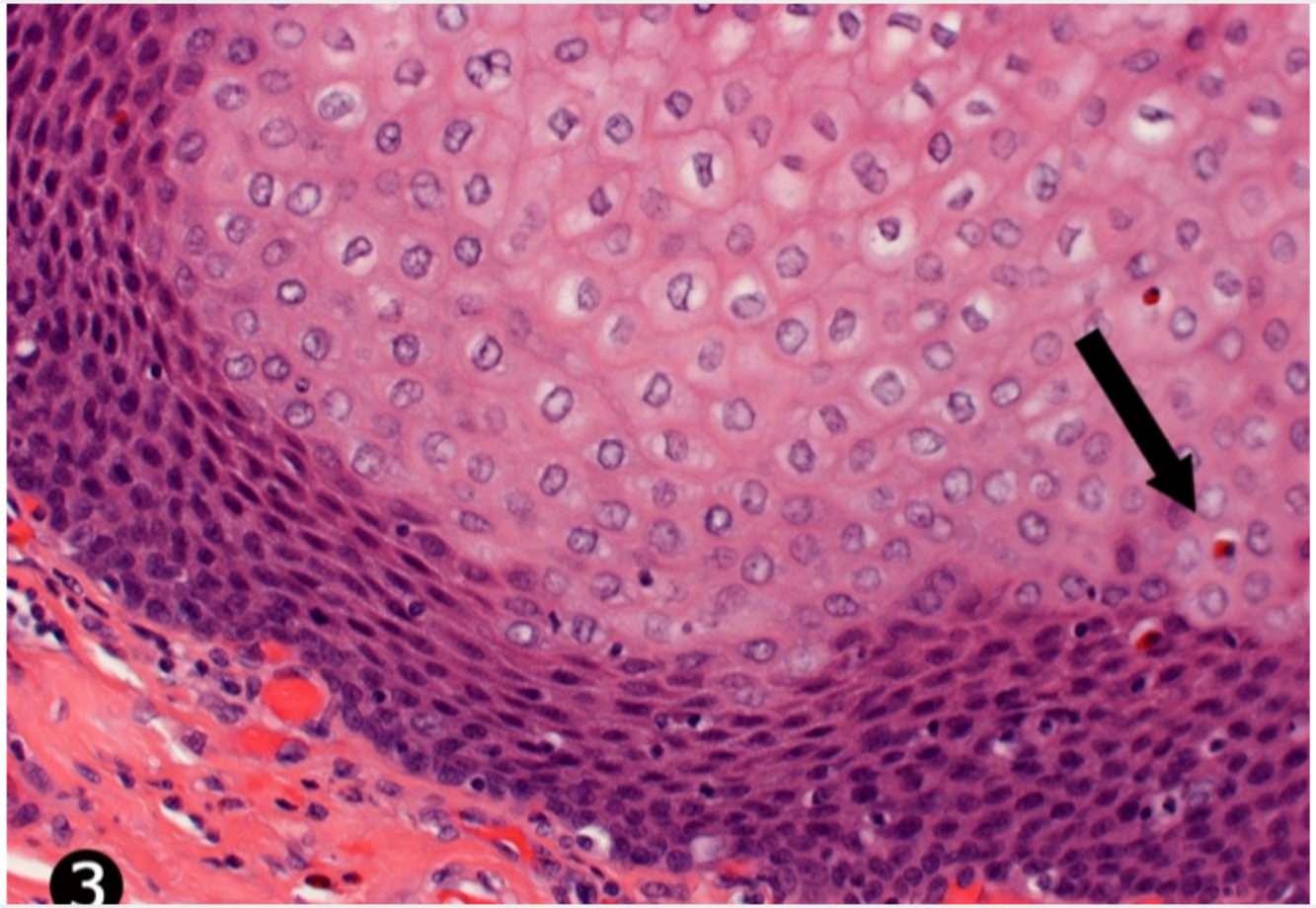

Zoom In | Zoom Out | Reset | Add To New Card | Existing Card

Block Time Remaining: 00:01:31
TUTOR

7 | Feedback | Suspend | End Block

This patient's biopsy is consistent with **esophageal squamous cell carcinoma** (SCC). The histopathologic features of this condition include solid nests of neoplastic squamous cells with abundant eosinophilic cytoplasm and distinct borders (compared to normal esophagus). Areas of **keratinization** (arrows) are easily identified (keratin pearls), and the presence of intercellular bridges is also characteristic of squamous differentiation.

Most cases of esophageal SCC occur in men age >50 with a history of prolonged smoking and alcohol use. Patients typically present with solid food **dysphagia** as the tumor gradually obstructs the esophageal lumen, which can progress to liquid dysphagia. Retrosternal discomfort/burning and significant **weight loss** are also common. Chronic gastrointestinal blood loss may result in iron deficiency anemia with fatigue. The prognosis for esophageal cancer is generally poor as many patients present with incurable locally advanced or metastatic disease.

(Choice A) Benign tumors of the esophagus (most commonly leiomyomas) are rare and slow growing. On light microscopy, leiomyomas consist of fascicles of spindle cells with variable amounts of fibrosis.

(Choices C and E) Reflux esophagitis commonly occurs due to gastroesophageal reflux disease and is characterized histologically by elongation of the papillae, basal cell hypertrophy, and intraepithelial eosinophils (arrows). Repeated epithelial injury caused by reflux esophagitis may lead to Barrett esophagus, which is characterized by intestinal metaplasia with goblet cells. Barrett esophagus is a premalignant condition that significantly increases the risk of esophageal adenocarcinoma.

(Choice D) Achalasia is an esophageal motility disorder characterized by failed relaxation of the lower esophageal sphincter resulting in food retention, dilation of the esophageal body, and symptoms of solid/liquid dysphagia. Achalasia increases the risk of squamous cell carcinoma of the esophagus.

Educational objective:
The histopathologic features of esophageal squamous cell carcinoma include solid nests of neoplastic squamous cells with abundant eosinophilic cytoplasm and distinct borders. Areas of keratinization and the presence of intercellular bridges are also characteristic. Patients typically present with progressive solid and eventually liquid dysphagia and weight loss.

References

- Distinctive clinicopathological characteristics in esophageal squamous cell carcinoma.

Settings

1 2 3 4 5 6 7 8 9 10 11 12 13 14 15 16 17 18 19 20 21 22 23 24 25 26 27 28 29 30

Item 32 of 40
Question Id: 287

Mark | Previous | Next | Full Screen | Tutorial | Lab Values | Notes | Calculator | Reverse Color | Text Zoom | Settings

This patient's biopsy is consistent with **esophageal squamous cell carcinoma** (SCC). The histopathologic features of this condition include solid

Exhibit Display

Reflux Esophagitis Reflux esophagitis Reflux Esophagitis

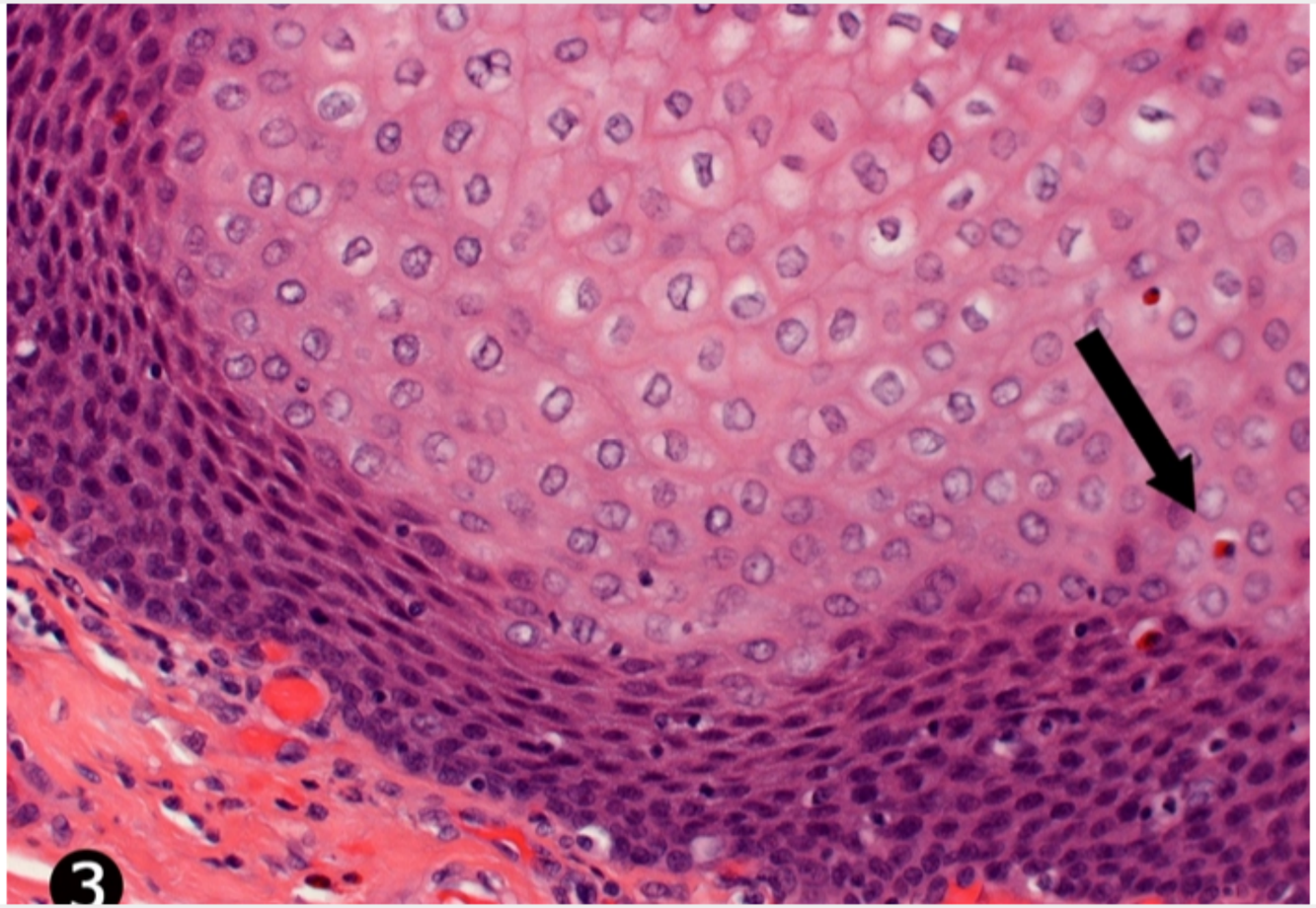

Zoom In | Zoom Out | Reset | Add To New Card | Existing Card

Block Time Remaining: 00:01:31
TUTOR

7 | Feedback | Suspend | End Block

Settings

1 2 3 4 5 6 7 8 9 10 11 12 13 14 15 16 17 18 19 20 21 22 23 24 25 26 27 28 29 30

Item 32 of 40
Question Id: 287

Mark | Previous | Next | Full Screen | Tutorial | Lab Values | Notes | Calculator | Reverse Color | Text Zoom | Settings

This patient's biopsy is consistent with **esophageal squamous cell carcinoma** (SCC). The histopathologic features of this condition include solid

Exhibit Display

Reflux Esophagitis Reflux esophagitis Reflux Esophagitis

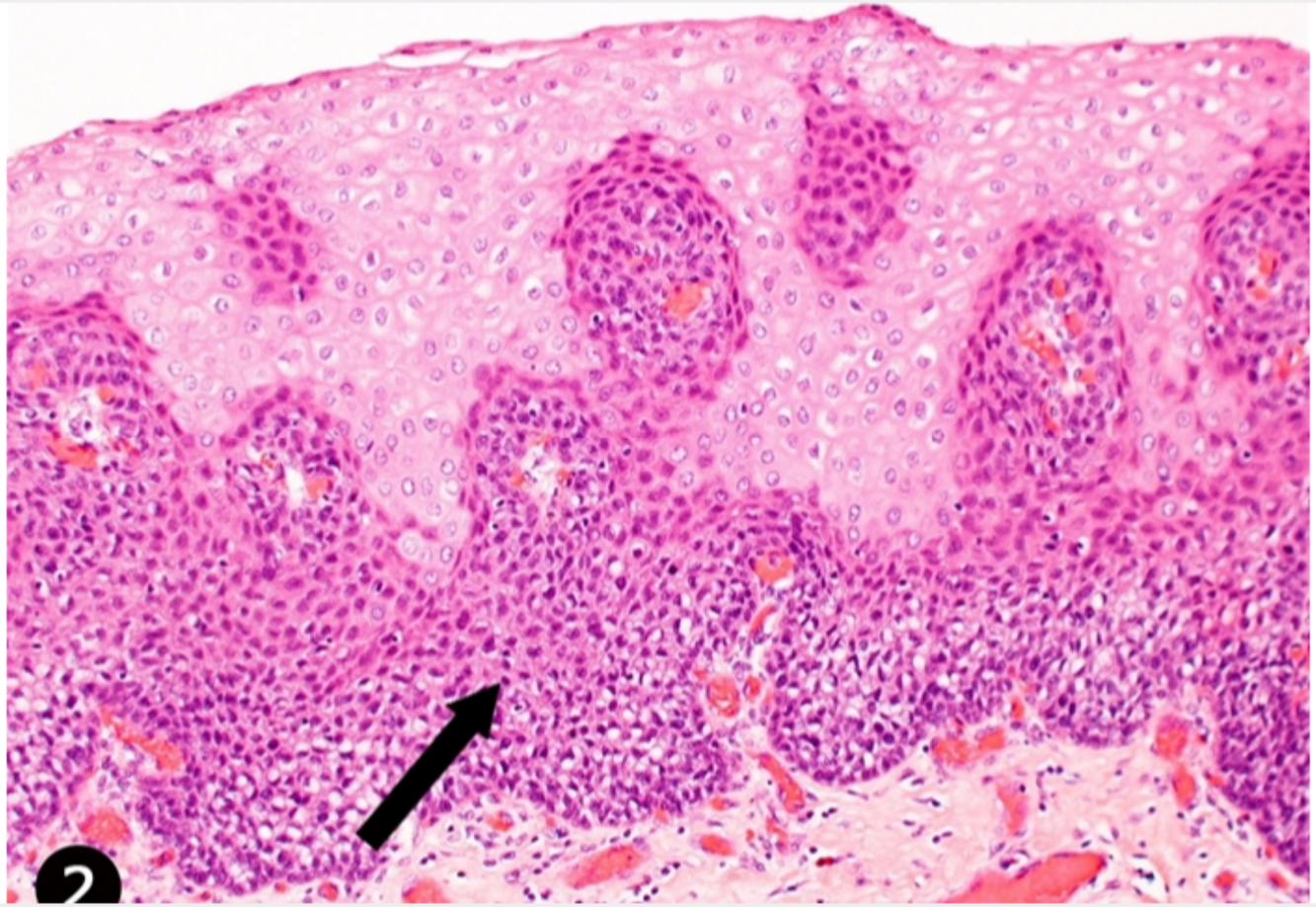

Zoom In | Zoom Out | Reset | Add To New Card | Existing Card

Block Time Remaining: 00:01:31
TUTOR

7 | Feedback | Suspend | End Block

Settings

1 2 3 4 5 6 7 8 9 10 11 12 13 14 15 16 17 18 19 20 21 22 23 24 25 26 27 28 29 30

Item 32 of 40
Question Id: 287

Mark | Previous | Next | Full Screen | Tutorial | Lab Values | Notes | Calculator | Reverse Color | Text Zoom | Settings

This patient's biopsy is consistent with **esophageal squamous cell carcinoma** (SCC). The histopathologic features of this condition include solid

Exhibit Display

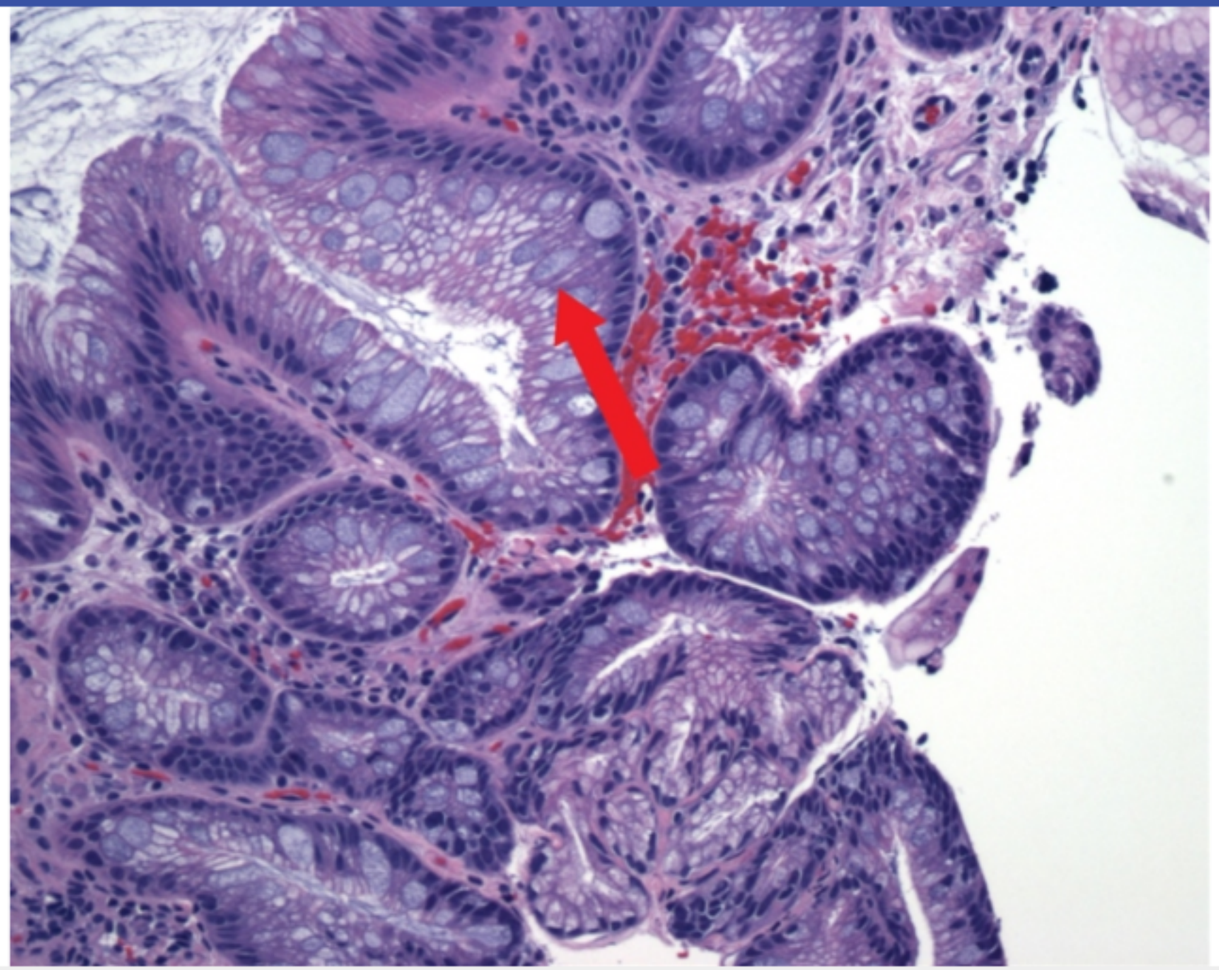

Zoom In | Zoom Out | Reset | Add To New Card | Existing Card

Block Time Remaining: 00:01:31
TUTOR

7 | Feedback | Suspend | End Block

Settings

1 2 3 4 5 6 7 8 9 10 11 12 13 14 15 16 17 18 19 20 21 22 23 24 25 26 27 28 29 30

Item 32 of 40
Question Id: 287

Mark | Previous | Next | Full Screen | Tutorial | Lab Values | Notes | Calculator | Reverse Color | Text Zoom | Settings

This patient's biopsy is consistent with **esophageal squamous cell carcinoma** (SCC). The histopathologic features of this condition include solid

Exhibit Display

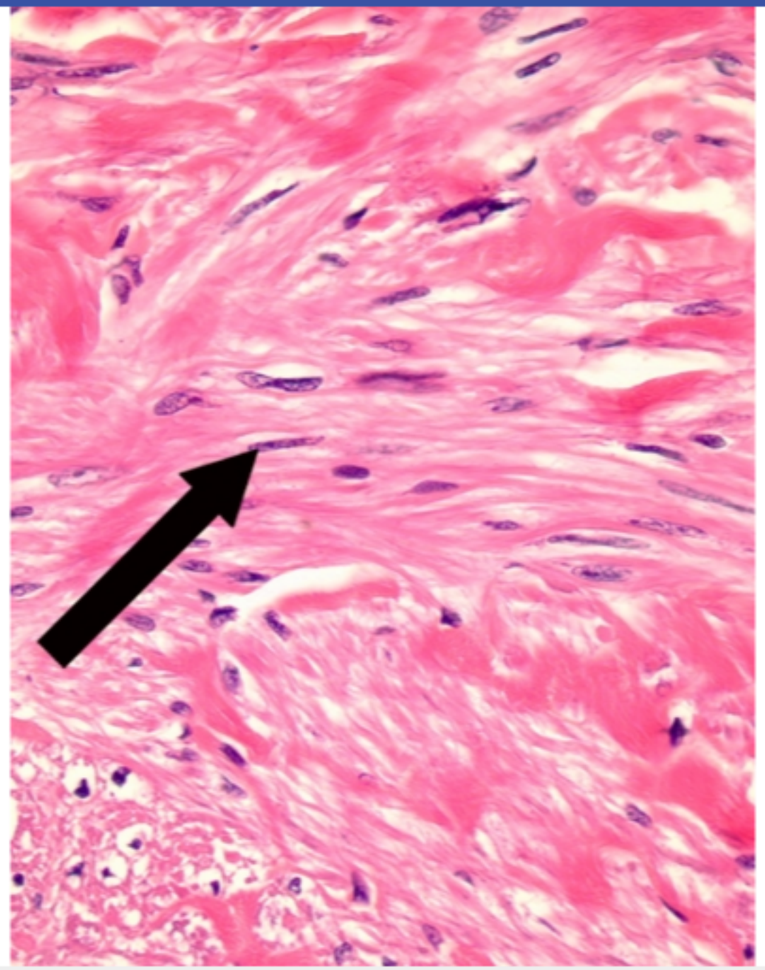

Zoom In | Zoom Out | Reset | Add To New Card | Existing Card

Block Time Remaining: 00:01:31
TUTOR

7 | Feedback | Suspend | End Block

A 25-year-old man comes to the hospital due to worsening abdominal pain, distension, and nausea and vomiting for 3 days. He has a 4-year history of recurrent abdominal pain associated with diarrhea, low-grade fever, and easy fatigability. The symptoms usually occur after stress and resolve spontaneously in a few days. However, this time, the patient's symptoms persisted and worsened. He has no other medical problems and takes no medications on a regular basis. Temperature is 38.2 C (100.8 F), blood pressure is 110/70 mm Hg, pulse is 104/min, and respirations are 16/min. BMI is 19 kg/m^2. Examination shows a tender mass in the right lower quadrant of the abdomen. Imaging is consistent with small-bowel obstruction. Laparotomy reveals that the abdominal mass is composed of inflamed small bowel, adherent and indurated mesentery, and enlarged abdominal lymph nodes. The affected region of the small bowel is resected. Which of the following is most likely to be seen on histologic examination of this patient's intestine?

- A. Caseating granulomas in all layers of the intestine
- B. Flask-shaped ulcers with narrow necks and broad bases
- C. Inflammation limited to the mucosa and submucosa
- D. Pseudomembranes of fibrin and inflammatory debris
- E. Thickening of the muscularis mucosae

Submit

A 25-year-old man comes to the hospital due to worsening abdominal pain, distension, and nausea and vomiting for 3 days. He has a 4-year history of recurrent abdominal pain associated with diarrhea, low-grade fever, and easy fatigability. The symptoms usually occur after stress and resolve spontaneously in a few days. However, this time, the patient's symptoms persisted and worsened. He has no other medical problems and takes no medications on a regular basis. Temperature is 38.2 C (100.8 F), blood pressure is 110/70 mm Hg, pulse is 104/min, and respirations are 16/min. BMI is 19 kg/m^2. Examination shows a tender mass in the right lower quadrant of the abdomen. Imaging is consistent with small-bowel obstruction. Laparotomy reveals that the abdominal mass is composed of inflamed small bowel, adherent and indurated mesentery, and enlarged abdominal lymph nodes. The affected region of the small bowel is resected. Which of the following is most likely to be seen on histologic examination of this patient's intestine?

A. Caseating granulomas in all layers of the intestine (45%)

B. Flask-shaped ulcers with narrow necks and broad bases (11%)

C. Inflammation limited to the mucosa and submucosa (17%)

D. Pseudomembranes of fibrin and inflammatory debris (8%)

✓ E. Thickening of the muscularis mucosae (17%)

Omitted
Correct answer
E

17%
Answered correctly

02 secs
Time Spent

03/28/2020
Last Updated

Explanation

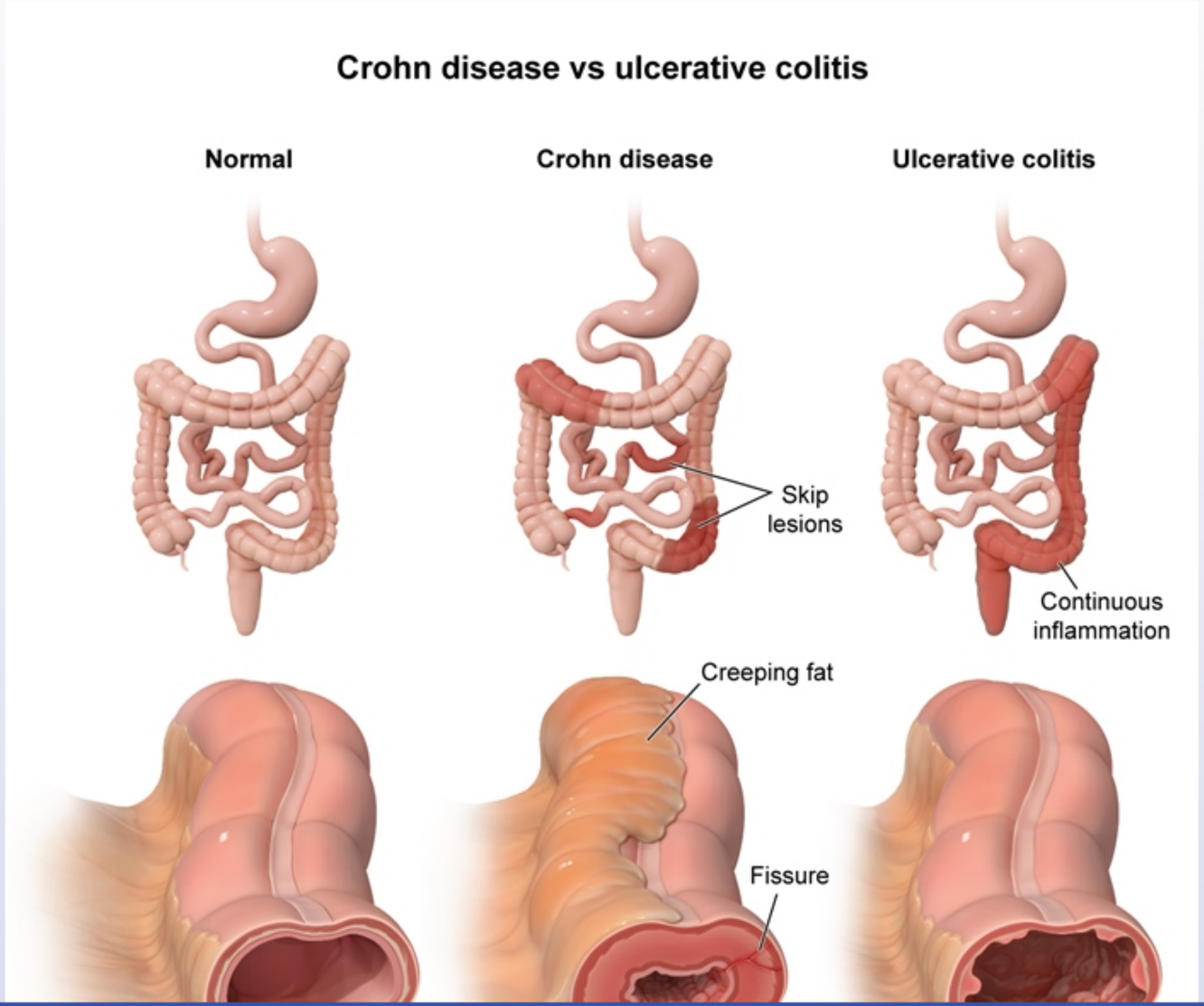
Crohn disease vs ulcerative colitis
Normal
Crohn disease
Ulcerative colitis
Skip lesions
Continuous inflammation
Creeping fat
Fissure

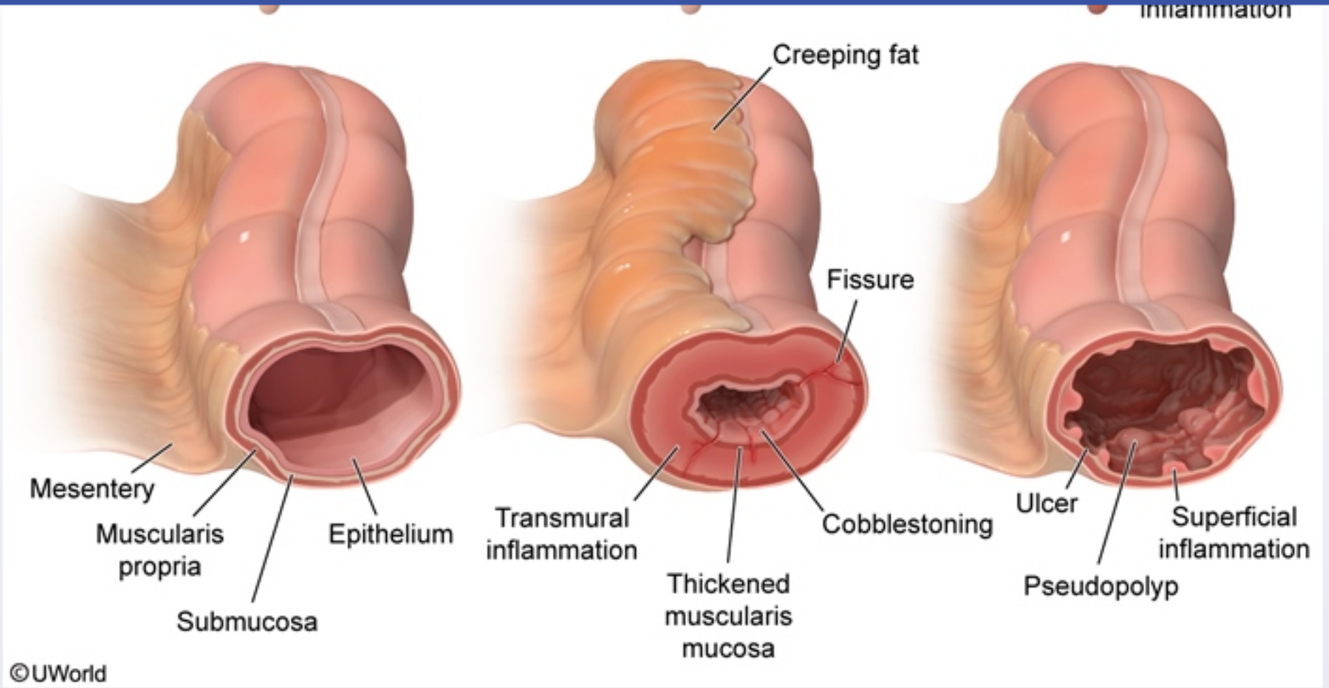

This patient with recurrent abdominal pain and diarrhea likely has **Crohn disease** (CD) complicated by small-bowel obstruction. CD is an inflammatory bowel disease that occurs most commonly in young adults. It typically presents as recurrent episodes of abdominal pain associated with diarrhea, low-grade fevers, and fatigue; symptoms may worsen during periods of stress. The inflammation can affect any part of the gastrointestinal tract from the mouth to the anus and is typically patchy with interspersed areas of normal bowel (skip lesions). CD is characterized by **transmural inflammation** (all layers of the bowel wall are involved), which predisposes to several complications:

- **Strictures** occur as a result of bowel wall edema, fibrosis, and **hypertrophy (thickening)** of the muscularis mucosae, which narrows the intestinal lumen. This can progress to **bowel obstruction**.
- Fistulas occur when ulcers penetrate the entire thickness of the intestinal wall, leading to a sinus tract that communicates between multiple organs (eg, enterovesicular, enterovaginal, enteroenteric).
- Abscesses form when sinus tracts become walled off. They can also perforate, leading to diffuse peritonitis.

This patient with recurrent abdominal pain and diarrhea likely has **Crohn disease** (CD) complicated by small-bowel obstruction. CD is an inflammatory bowel disease that occurs most commonly in young adults. It typically presents as recurrent episodes of abdominal pain associated with diarrhea, low-grade fevers, and fatigue; symptoms may worsen during periods of stress. The inflammation can affect any part of the gastrointestinal tract from the mouth to the anus and is typically patchy with interspersed areas of normal bowel (skip lesions). CD is characterized by **transmural inflammation** (all layers of the bowel wall are involved), which predisposes to several complications:

- **Strictures** occur as a result of bowel wall edema, fibrosis, and **hypertrophy (thickening)** of the muscularis mucosae, which narrows the intestinal lumen. This can progress to **bowel obstruction**.
- Fistulas occur when ulcers penetrate the entire thickness of the intestinal wall, leading to a sinus tract that communicates between multiple organs (eg, enterovesicular, enterovaginal, enteroenteric).
- Abscesses form when sinus tracts become walled off. They can also perforate, leading to diffuse peritonitis.

(Choice A) Caseating granulomas are typically seen in multiple infectious processes, most notably tuberculosis (TB). Abdominal TB can present with abdominal pain, fevers, and occasional obstruction; however, symptoms are unlikely to spontaneously wax and wane, and evidence of TB is often present in other sites (eg, hemoptysis with pulmonary TB). CD is associated with noncaseating, rather than caseating, granulomas.

(Choice B) Flask-shaped ulcers in the cecum and colon are seen in *Entamoeba histolytica* infection, which occurs more commonly in developing countries and presents with bloody diarrhea. Severe cases can cause fulminant colitis with bowel necrosis, but obstruction is uncommon.

(Choice C) Ulcerative colitis is an inflammatory bowel disease that involves only the mucosa and submucosa. Inflammation involves contiguous areas of the colon only, and the small bowel is not involved. Due to the superficial nature of the inflammation, strictures and fistulas are not seen.

(Choice D) Pseudomembranes composed of fibrin and inflammatory debris are seen with *Clostridium difficile* infection, which is typically associated with antibiotic use. Complications include toxic megacolon; however, *C difficile* does not cause obstruction and the small bowel is not typically involved.

Educational objective:
Crohn disease is characterized by patchy, transmural inflammation of the gastrointestinal tract. It can affect any part of the tract from the mouth to the anus. Complications include strictures (due to bowel wall edema, fibrosis, and thickening of the muscularis mucosae), fistulas (due to

Exhibit Display

Small intestinal histology

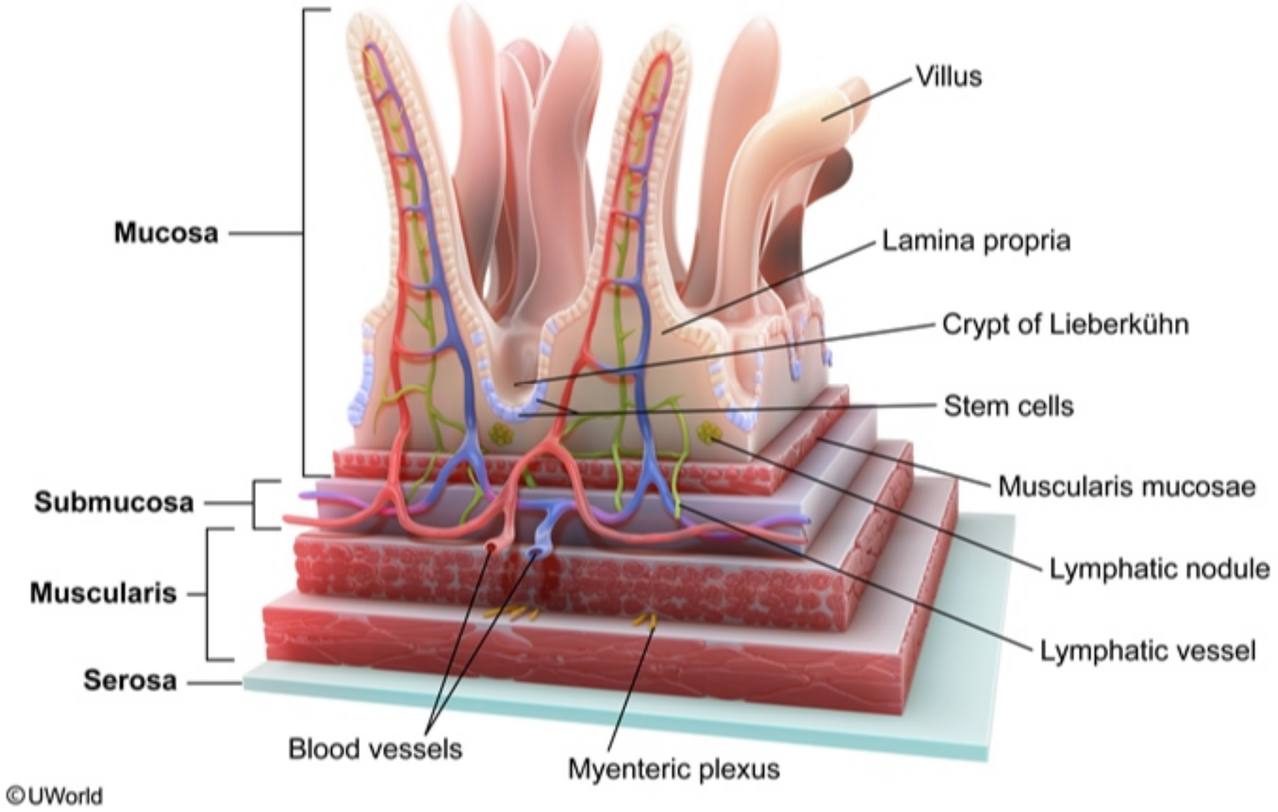

©UWorld

Zoom In | Zoom Out | Reset | Add To New Card | Existing Card

the anus. Complications include strictures (due to bowel wall edema, fibrosis, and thickening of the muscularis mucosae), fistulas (due to

Exhibit Display

Crohn disease

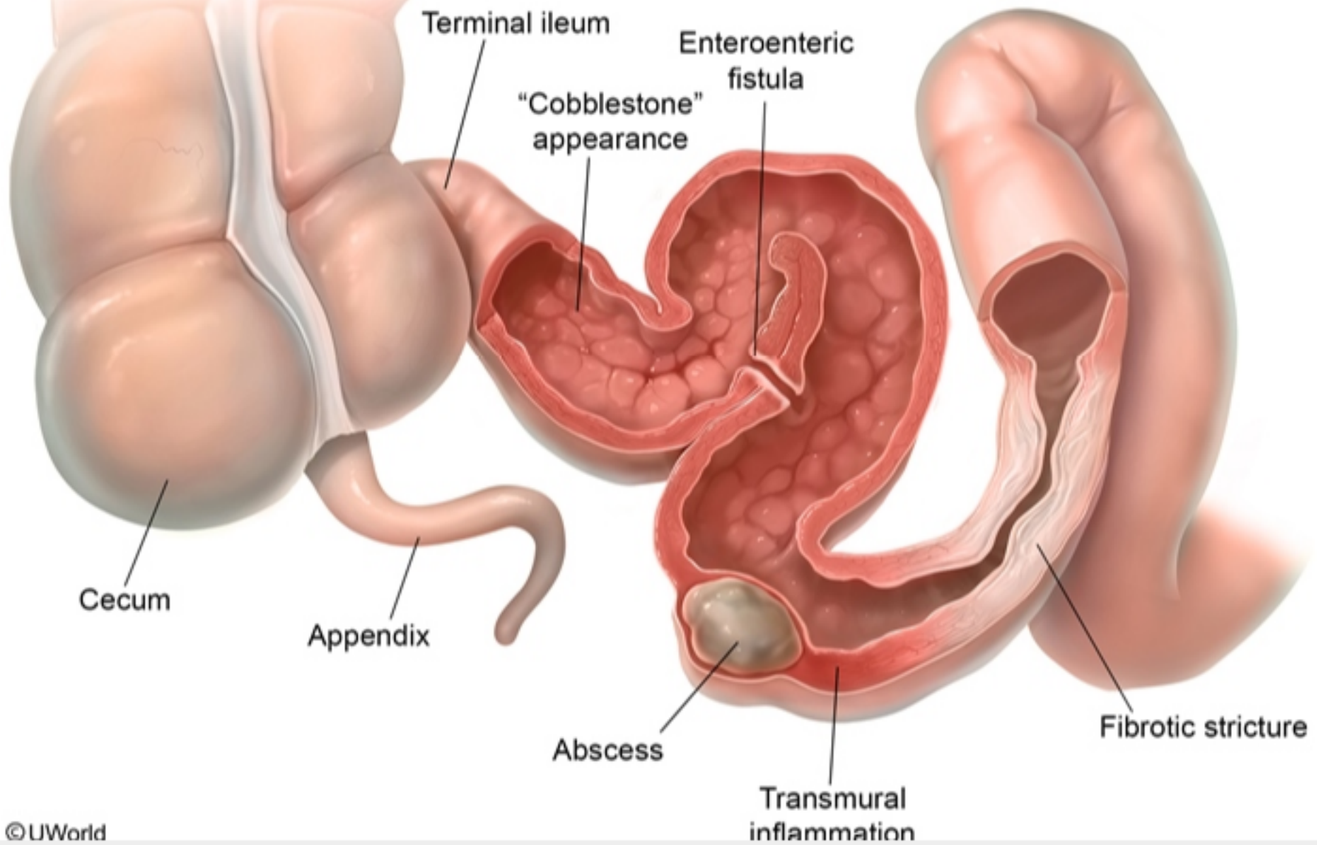

©UWorld

Zoom In | Zoom Out | Reset | Add To New Card | Existing Card

the anus. Complications include strictures (due to bowel wall edema, fibrosis, and thickening of the muscularis mucosae), fistulas (due to

Settings

1 2 3 4 5 6 7 8 9 10 11 12 13 14 15 16 17 18 19 20 21 22 23 24 25 26 27 28 29 30

Item 33 of 40
Question Id: 409

Mark | Previous | Next | Full Screen | Tutorial | Lab Values | Notes | Calculator | Reverse Color | Text Zoom | Settings

Exhibit Display

Pseudomembranous colitis

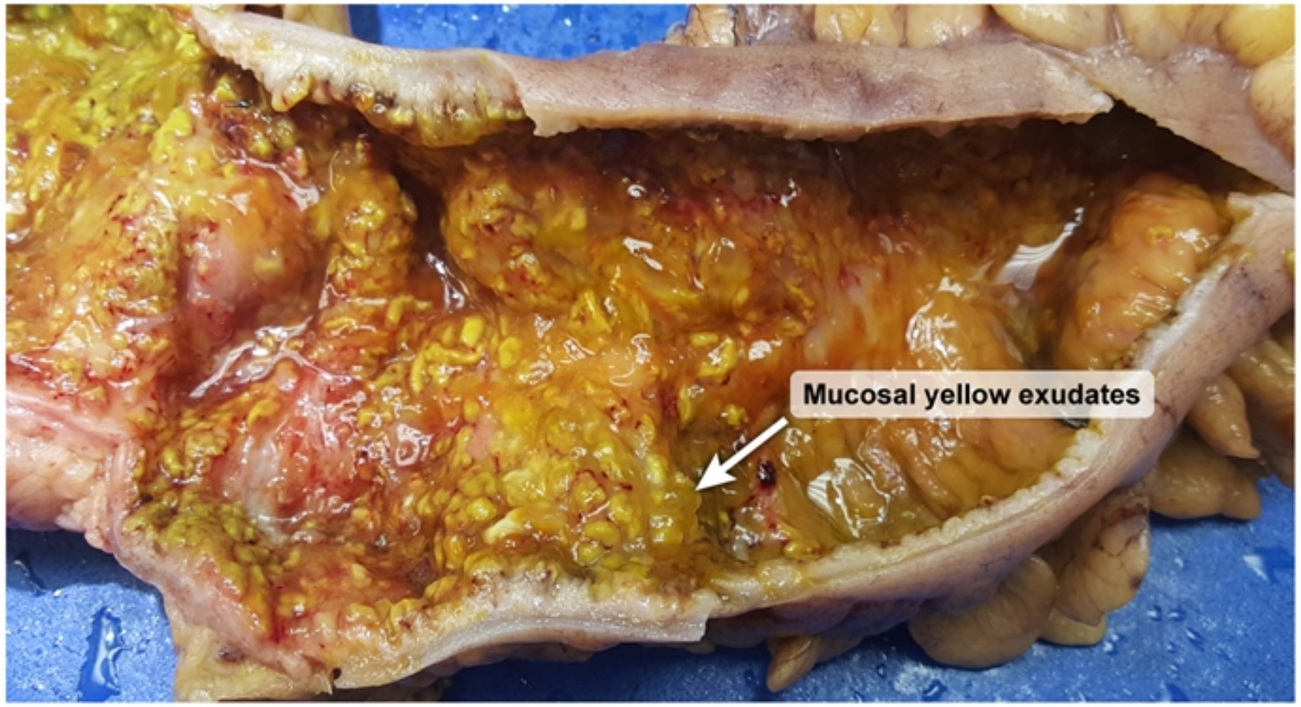

©UWorld

Zoom In | Zoom Out | Reset | Add To New Card | Existing Card

the anus. Complications include strictures (due to bowel wall edema, fibrosis, and thickening of the muscularis mucosae), fistulas (due to

Block Time Remaining: 00:01:33
TUTOR

4 | Feedback | Suspend | End Block

intestinal lumen. This can progress to **bowel obstruction**.

- Fistulas occur when ulcers penetrate the entire thickness of the intestinal wall, leading to a sinus tract that communicates between multiple organs (eg, enterovesicular, enterovaginal, enteroenteric).
- Abscesses form when sinus tracts become walled off. They can also perforate, leading to diffuse peritonitis.

(Choice A) Caseating granulomas are typically seen in multiple infectious processes, most notably tuberculosis (TB). Abdominal TB can present with abdominal pain, fevers, and occasional obstruction; however, symptoms are unlikely to spontaneously wax and wane, and evidence of TB is often present in other sites (eg, hemoptysis with pulmonary TB). CD is associated with noncaseating, rather than caseating, granulomas.

(Choice B) Flask-shaped ulcers in the cecum and colon are seen in *Entamoeba histolytica* infection, which occurs more commonly in developing countries and presents with bloody diarrhea. Severe cases can cause fulminant colitis with bowel necrosis, but obstruction is uncommon.

(Choice C) Ulcerative colitis is an inflammatory bowel disease that involves only the mucosa and submucosa. Inflammation involves contiguous areas of the colon only, and the small bowel is not involved. Due to the superficial nature of the inflammation, strictures and fistulas are not seen.

(Choice D) Pseudomembranes composed of fibrin and inflammatory debris are seen with *Clostridium difficile* infection, which is typically associated with antibiotic use. Complications include toxic megacolon; however, *C difficile* does not cause obstruction and the small bowel is not typically involved.

Educational objective:
Crohn disease is characterized by patchy, transmural inflammation of the gastrointestinal tract. It can affect any part of the tract from the mouth to the anus. Complications include strictures (due to bowel wall edema, fibrosis, and thickening of the muscularis mucosae), fistulas (due to penetration of ulcers through the intestinal wall), and abscesses.

Pathology	Gastrointestinal & Nutrition	Inflammatory bowel disease
Subject	System	Topic

Copyright © UWorld. All rights reserved.

A 34-year-old woman is found dead in her apartment. Medical history is significant for substance abuse and a prior hospitalization for upper extremity cellulitis. An autopsy examination is performed. A ruptured plaque in the proximal anterior descending artery with an overlying occlusive thrombus is found. Incidentally, a 4-cm hepatic mass in the right lobe of the liver is also found. The mass is lighter than the surrounding liver tissue and appears lobulated with a central, gray-white, depressed stellate scar from which fibrous septae radiate to the periphery. The rest of the liver is normal. No additional abnormalities are noted on autopsy. Which of the following is the most likely diagnosis of this patient's liver lesion?

A. Focal nodular hyperplasia

B. Hepatic adenoma

C. Hepatic hemangioma

D. Hepatocellular carcinoma

E. Hydatid cyst

Submit

A 34-year-old woman is found dead in her apartment. Medical history is significant for substance abuse and a prior hospitalization for upper extremity cellulitis. An autopsy examination is performed. A ruptured plaque in the proximal anterior descending artery with an overlying occlusive thrombus is found. Incidentally, a 4-cm hepatic mass in the right lobe of the liver is also found. The mass is lighter than the surrounding liver tissue and appears lobulated with a central, gray-white, depressed stellate scar from which fibrous septae radiate to the periphery. The rest of the liver is normal. No additional abnormalities are noted on autopsy. Which of the following is the most likely diagnosis of this patient's liver lesion?

- ✓ A. Focal nodular hyperplasia (26%)
- B. Hepatic adenoma (21%)
- C. Hepatic hemangioma (8%)
- D. Hepatocellular carcinoma (25%)
- E. Hydatid cyst (16%)

Omitted
Correct answer
A

26%
Answered correctly

02 secs
Time Spent

06/30/2020
Last Updated

Explanation

This patient's liver mass is characteristic of **focal nodular hyperplasia** (FNH), a nonmalignant lesion that most commonly occurs in **young women**. FNH is thought to result from a hepatic vascular abnormality causing localized hyperperfusion with a secondary hyperplastic response. Classically, the lesions appear as small, solitary, **pale nodules** composed of cords of normal-appearing hepatocytes and a **central stellate scar** with fibrous septae that surround abnormally large hepatic arterial branches.

This patient's liver mass is characteristic of **focal nodular hyperplasia** (FNH), a nonmalignant lesion that most commonly occurs in **young women**. FNH is thought to result from a hepatic vascular abnormality causing localized hyperperfusion with a secondary hyperplastic response. Classically, the lesions appear as small, solitary, **pale nodules** composed of cords of normal-appearing hepatocytes and a **central stellate scar** with fibrous septae that surround abnormally large hepatic arterial branches.

FNH is **benign** and typically does not enlarge, undergo malignant transformation, or rupture; therefore, most cases do not require treatment. These lesions are usually **asymptomatic** and discovered incidentally during autopsy or abdominal imaging for a different condition. The diagnosis is confirmed most often by observing a characteristic solitary mass on imaging with features indicating the arterial origin of FNH (eg, enhancement with contrast in the arterial phase).

(Choice B) Hepatic adenoma is a benign liver lesion that is strongly associated with oral contraceptive use and may undergo malignant transformation or rupture. Although it can also be discovered incidentally, a hepatic adenoma will usually appear as an irregular, tan-colored group of nodules composed of large plates of adenoma cells with an absence of normal hepatic architecture (no portal structures or bile ducts).

(Choice C) Hepatic hemangioma is the most common benign hepatic tumor but would be characterized by a dark, vascular tumor with areas of hemorrhage. Histologically, these tumors display cavernous vascular compartments lined by epithelium and filled with red blood cells.

(Choice D) Hepatocellular carcinoma (HCC) is a malignant liver tumor that usually develops in the setting of underlying chronic liver disease (eg, chronic viral hepatitis, alcohol-induced cirrhosis). Well-differentiated HCC can appear similar to normal liver tissue; however, these tumors are typically larger, irregular, and symptomatic (eg, abdominal pain, elevated LFTs) with areas of hemorrhage on gross examination.

(Choice E) Hydatid cysts are caused by the larvae form of *Echinococcus granulosus*, a canine tapeworm. This pathogen is rare in the United States, and hepatic echinococcal lesions would present as fluid-filled cysts lined by a membrane derived from the parasite.

Educational objective:
Focal nodular hyperplasia is a benign liver tumor marked by a central stellate scar containing an abnormally large artery. It usually arises in young women and most cases are asymptomatic and found incidentally.

Pathology	Gastrointestinal & Nutrition	Focal nodular hyperplasia
Subject	System	Topic

Settings

1 2 3 4 5 6 7 8 9 10 11 12 13 14 15 16 17 18 19 20 21 22 23 24 25 26 27 28 29 30

Item 34 of 40
Question Id: 16070

Mark | Previous | Next | Full Screen | Tutorial | Lab Values | Notes | Calculator | Reverse Color | Text Zoom | Settings

This patient's liver mass is characteristic of **focal nodular hyperplasia** (FNH), a nonmalignant lesion that most commonly occurs in **young**

Exhibit Display

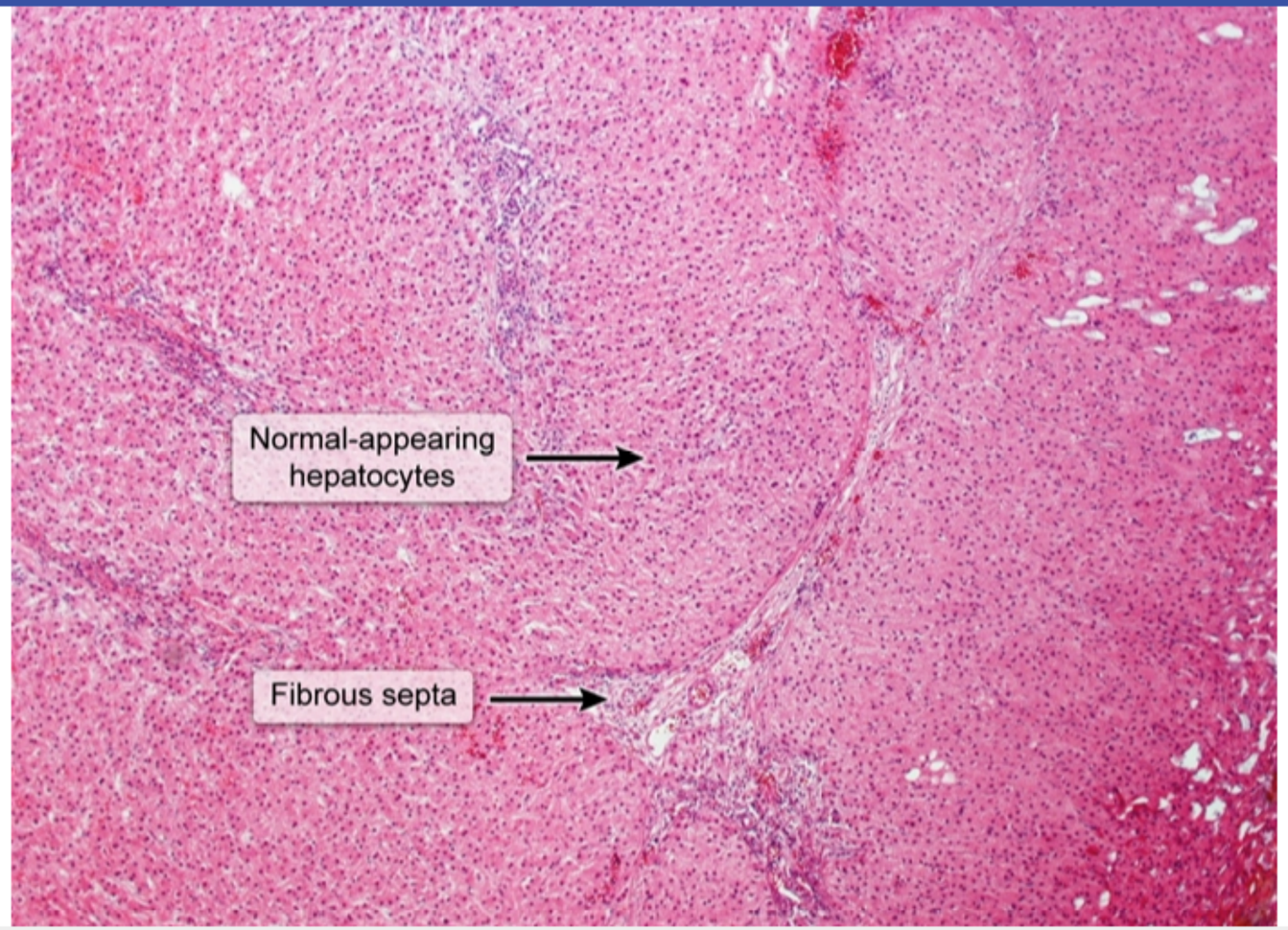

Zoom In | Zoom Out | Reset | Add To New Card | Existing Card

Block Time Remaining: 00:01:35
TUTOR

3 | Feedback | Suspend | End Block

Settings

1 2 3 4 5 6 7 8 9 10 11 12 13 14 15 16 17 18 19 20 21 22 23 24 25 26 27 28 29 30

Item 34 of 40
Question Id: 16070

Mark | Previous | Next | Full Screen | Tutorial | Lab Values | Notes | Calculator | Reverse Color | Text Zoom | Settings

This patient's liver mass is characteristic of **focal nodular hyperplasia** (FNH), a nonmalignant lesion that most commonly occurs in **young**

Exhibit Display

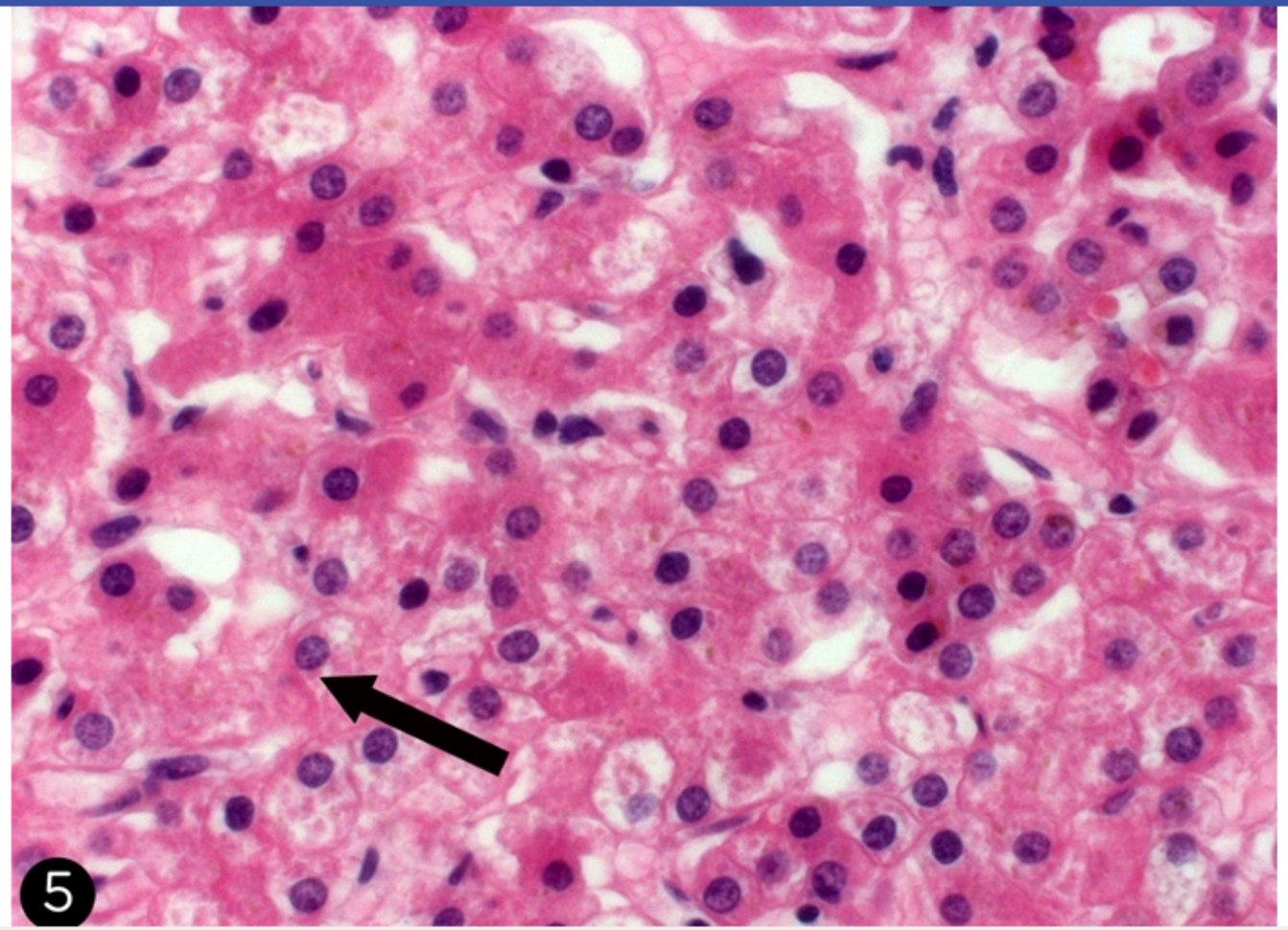

Zoom In | Zoom Out | Reset | Add To New Card | Existing Card

Block Time Remaining: 00:01:35
TUTOR

3 | Feedback | Suspend | End Block

Settings

1 2 3 4 5 6 7 8 9 10 11 12 13 14 15 16 17 18 19 20 21 22 23 24 25 26 27 28 29 30

Item 34 of 40
Question Id: 16070

Mark | Previous | Next | Full Screen | Tutorial | Lab Values | Notes | Calculator | Reverse Color | Text Zoom | Settings

This patient's liver mass is characteristic of **focal nodular hyperplasia** (FNH), a nonmalignant lesion that most commonly occurs in **young**

Exhibit Display

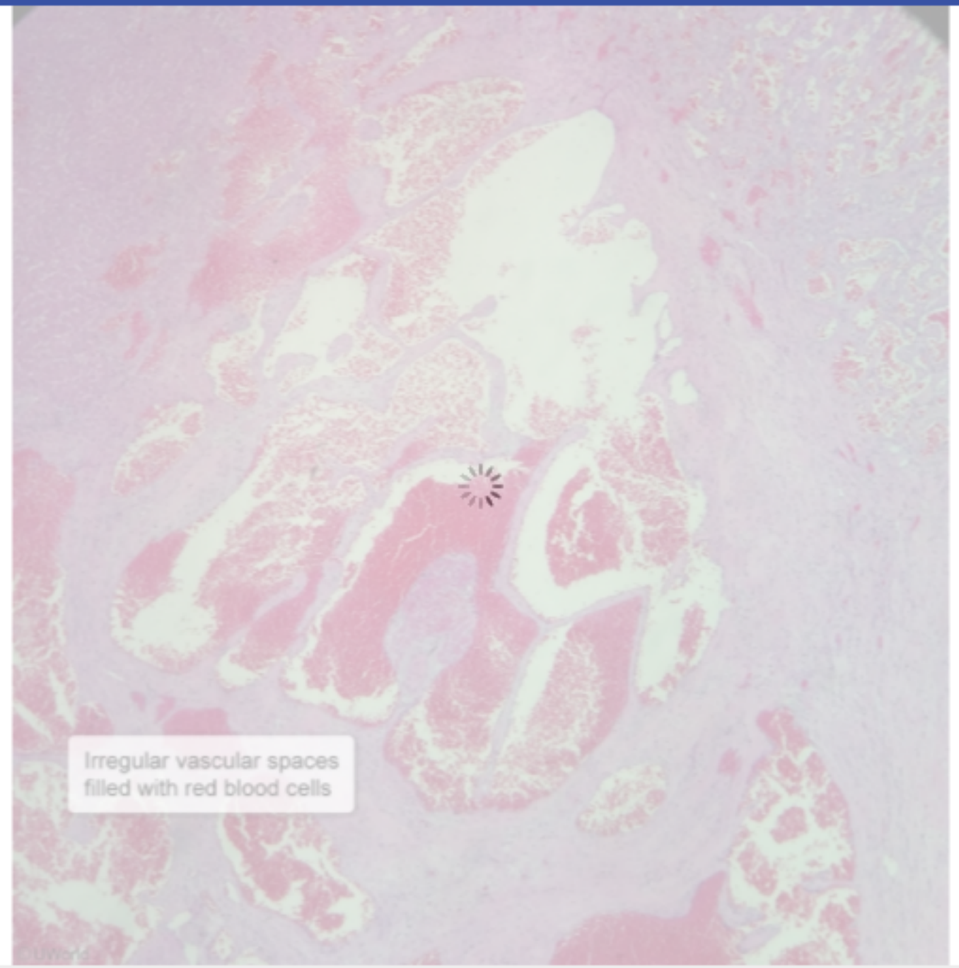

Zoom In | Zoom Out | Reset | Add To New Card | Existing Card

Block Time Remaining: 00:01:35
TUTOR

3 | Feedback | Suspend | End Block

A 60-year-old woman comes to the office with persistent, profuse mucoid diarrhea. Despite not eating much for the past 2 days, her diarrhea has not decreased, but she has no other symptoms. The patient has not had age-appropriate colon cancer screening. Family history is unremarkable. She does not use tobacco, alcohol, or illicit drugs. Vital signs and cardiopulmonary examination are normal. The abdomen is soft and nondistended. There is no hepatosplenomegaly. Laboratory studies show hypokalemia and microcytic anemia. Colonoscopy reveals a 2.5-cm, cauliflower-like mass in the sigmoid colon. The mass is resected and the histopathology of the lesion is shown in the exhibit. Which of the following is the most likely diagnosis in this patient?

A. Carcinoid tumor

B. Hamartomatous polyp

C. Hyperplastic polyp

D. Signet ring cell carcinoma

E. Villous adenoma

Submit

A 60-year-old woman comes to the office with persistent, profuse mucoid diarrhea. Despite not eating much for the past 2 days, her diarrhea has not decreased, but she has no other symptoms. The patient has not had age-appropriate colon cancer screening. Family history is unremarkable. She does not use tobacco, alcohol, or illicit drugs. Vital signs and cardiopulmonary examination are normal. The abdomen is soft and nondistended. There is no hepatosplenomegaly. Laboratory studies show hypokalemia and microcytic anemia. Colonoscopy reveals a 2.5-cm, cauliflower-like mass in the sigmoid colon. The mass is resected and the histopathology of the lesion is shown in the exhibit. Which of the following is the most likely diagnosis in this patient?

A. Carcinoid tumor (6%)

B. Hamartomatous polyp (5%)

C. Hyperplastic polyp (8%)

D. Signet ring cell carcinoma (1%)

✓ E. Villous adenoma (78%)

Omitted
Correct answer
E

78%
Answered correctly

02 secs
Time Spent

04/13/2020
Last Updated

Explanation

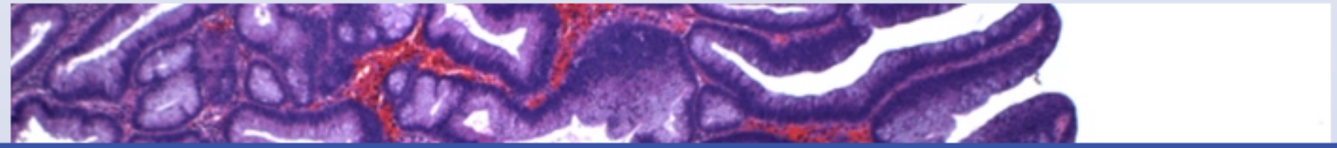

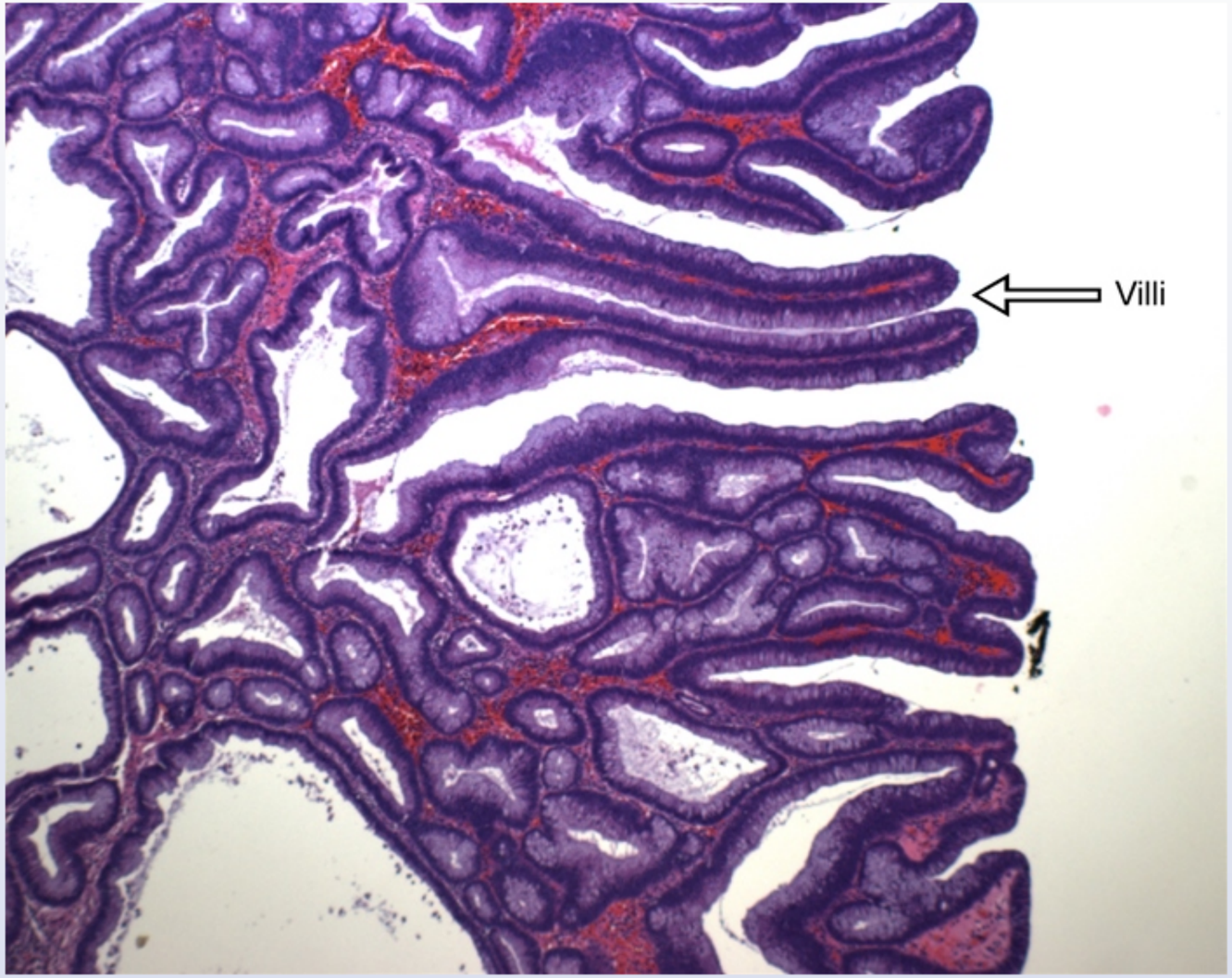

This patient has a large mass with high-grade dysplasia. Histology demonstrates long glands with finger-like (villous) projections extending from

This patient has a large mass with high-grade dysplasia. Histology demonstrates long glands with finger-like (villous) projections extending from the surface, which are characteristic of a **villous adenoma**. A villous adenoma is often large and sessile and can have velvety or cauliflower-like projections. By contrast, a tubular adenoma is composed of dysplastic colonic mucosal cells that form tube-shaped glands and tends to be smaller and pedunculated. A mixture of these 2 types indicates a tubulovillous adenoma. Of these, villous adenomas are the most likely to undergo **malignant transformation**.

Adenomas in the colon can cause occult or visible bleeding, leading to iron-deficiency anemia. Large polyps may occasionally cause partial obstruction with pain, constipation, and abdominal distension. In addition, villous adenomas can produce large quantities of prostaglandin E2, which results in **increased mucin** production and a **secretory diarrhea** characterized by watery, mucinous stools. Mucin is a potassium-rich glycoprotein; excessive production can result in **hypoproteinemia** and **hypokalemia**.

(Choice A) Intestinal carcinoids can cause diarrhea and are often associated with additional symptoms such as flushing, wheezing, and vascular telangiectasia when they metastasize. Histopathology is typified by insular (nesting) masses of small, round cells with peripheral palisading, granular cytoplasm, small nucleoli, and salt-and-pepper chromatin.

(Choice B) Hamartomatous polyps consist of disorganized mucosal glands, smooth muscle, and connective tissue. They may occur sporadically or in Peutz-Jeghers syndrome or juvenile polyposis. These polyps can cause bleeding and intussusception, but not secretory diarrhea.

(Choice C) Hyperplastic polyps are composed of well-differentiated mucosal cells that form glands and crypts. The crypts may be large or irregular but are not associated with dysplastic changes. They are almost always asymptomatic.

(Choice D) Signet ring cell carcinoma can occur in different locations, such as the stomach, breast, ovary, and colorectal area. Tumor cells contain abundant mucins that push the nuclei to the periphery and give the tumor cells their characteristic appearance.

Educational objective:
Adenomatous polyps are either tubular, villous, or tubulovillous, depending on their histologic appearance. Villous adenomas tend to be larger, sessile, and more severely dysplastic than tubular adenomas. Villous adenomas can cause a secretory diarrhea from increased mucin production; patients may develop hypoproteinemia and hypokalemia.

Pathology	Gastrointestinal & Nutrition	Colonic polyps
Subject	System	Topic

This patient has a large mass with high-grade dysplasia. Histology demonstrates long glands with finger-like (villous) projections extending from

Exhibit Display

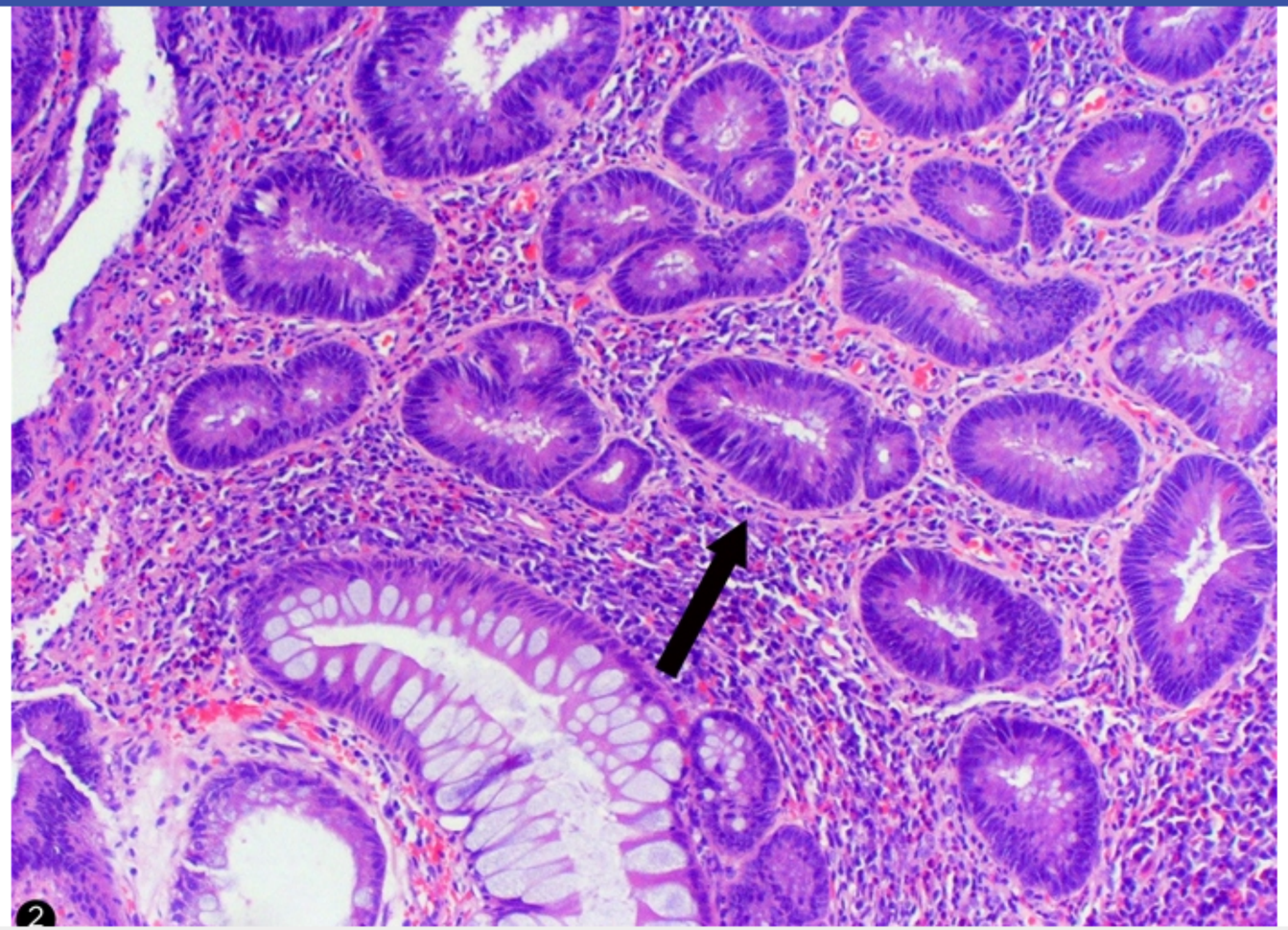

Zoom In | Zoom Out | Reset | Add To New Card | Existing Card

This patient has a large mass with high-grade dysplasia. Histology demonstrates long glands with finger-like (villous) projections extending from

Exhibit Display

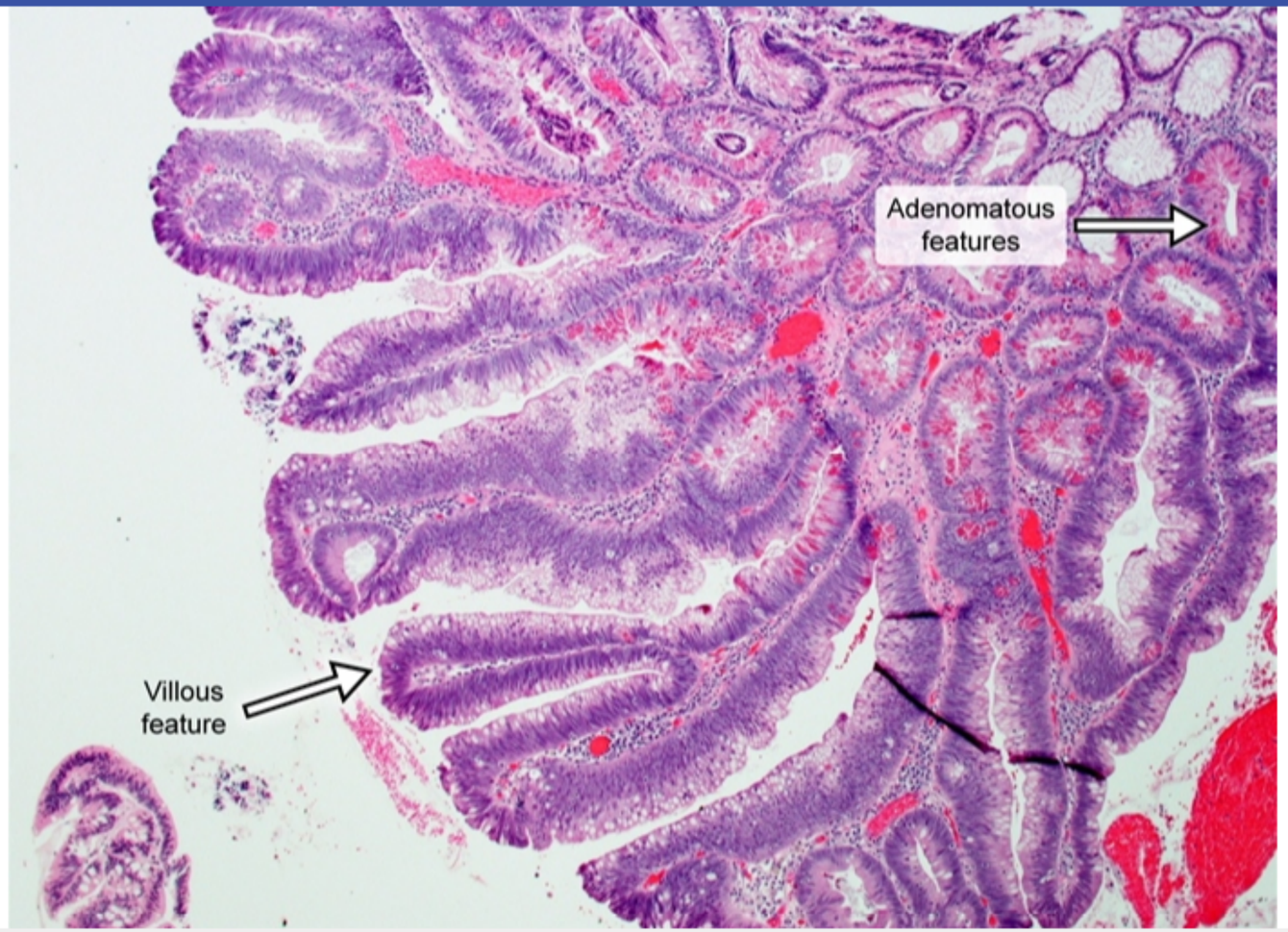

Zoom In | Zoom Out | Reset | Add To New Card | Existing Card

Settings

Item 35 of 40
Question Id: 430

Mark | Previous | Next | Full Screen | Tutorial | Lab Values | Notes | Calculator | Reverse Color | Text Zoom | Settings

This patient has a large mass with high-grade dysplasia. Histology demonstrates long glands with finger-like (villous) projections extending from the surface, which are characteristic of a **villous adenoma**. A villous adenoma is often large and sessile and can have velvety or cauliflower-like projections. By contrast, a tubular adenoma is composed of dysplastic colonic mucosal cells that form tube-shaped glands and tends to be smaller and peduncl
undergo **malignant**

Adenomas in the co
obstruction with pai
which results in **incr**
glycoprotein; excess

(Choice A) Intestin
telangiectasia when
granular cytoplasm,

(Choice B) Hamart
or in Peutz-Jeghers

(Choice C) Hyperp
irregular but are not

(Choice D) Signet
contain abundant m

Educational object
Adenomatous polyp
sessile, and more se
patients may develo

Pathology Ga

Exhibit Display

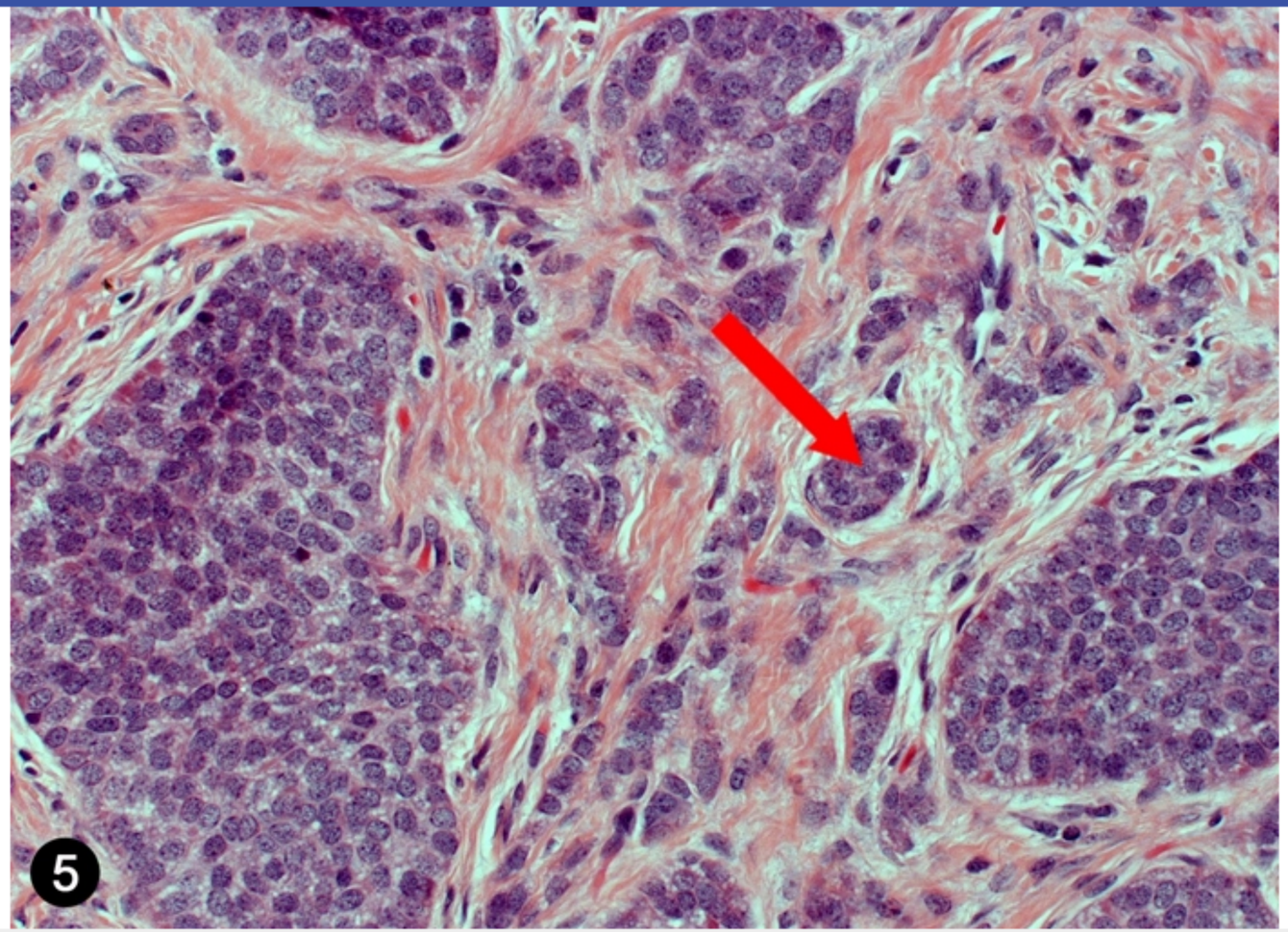

Zoom In | Zoom Out | Reset | Add To New Card | Existing Card

Block Time Remaining:
TUTOR

9 | Feedback | Suspend | End Block

Settings

1 2 3 4 5 6 7 8 9 10 11 12 13 14 15 16 17 18 19 20 21 22 23 24 25 26 27 28 29 30

Item 35 of 40
Question Id: 430

Mark | Previous | Next | Full Screen | Tutorial | Lab Values | Notes | Calculator | Reverse Color | Text Zoom | Settings

This patient has a large mass with high-grade dysplasia. Histology demonstrates long glands with finger-like (villous) projections extending from

Exhibit Display

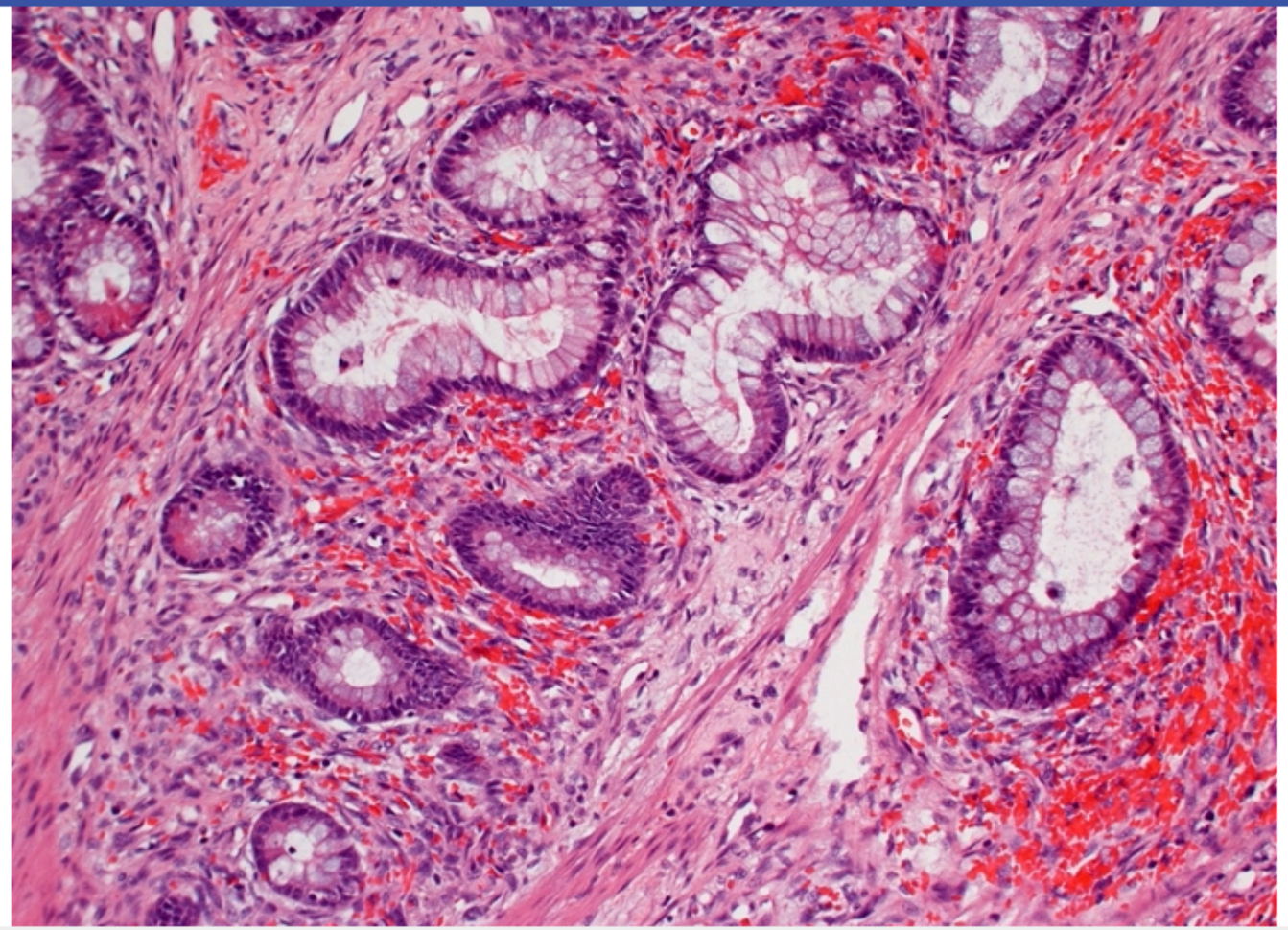

Zoom In | Zoom Out | Reset | Add To New Card | Existing Card

Block Time Remaining: 00:01:37
TUTOR

9 | Feedback | Suspend | End Block

Settings

1 2 3 4 5 6 7 8 9 10 11 12 13 14 15 16 17 18 19 20 21 22 23 24 25 26 27 28 29 30

Item 35 of 40
Question Id: 430

Mark | Previous | Next | Full Screen | Tutorial | Lab Values | Notes | Calculator | Reverse Color | Text Zoom | Settings

This patient has a large mass with high-grade dysplasia. Histology demonstrates long glands with finger-like (villous) projections extending from

Exhibit Display

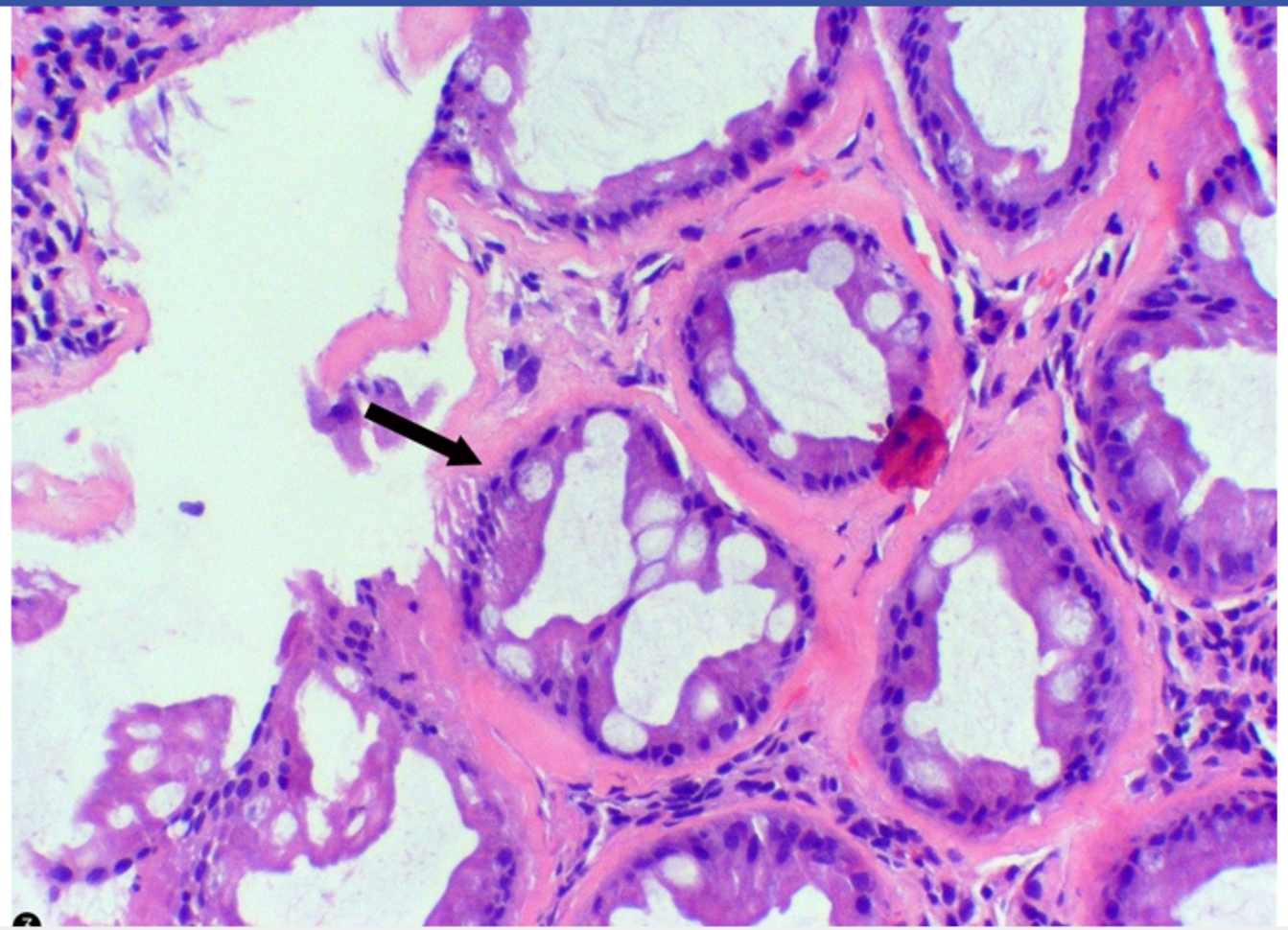

Zoom In | Zoom Out | Reset | Add To New Card | Existing Card

Block Time Remaining: 00:01:37
TUTOR

9 | Feedback | Suspend | End Block

This patient has a large mass with high-grade dysplasia. Histology demonstrates long glands with finger-like (villous) projections extending from

Exhibit Display

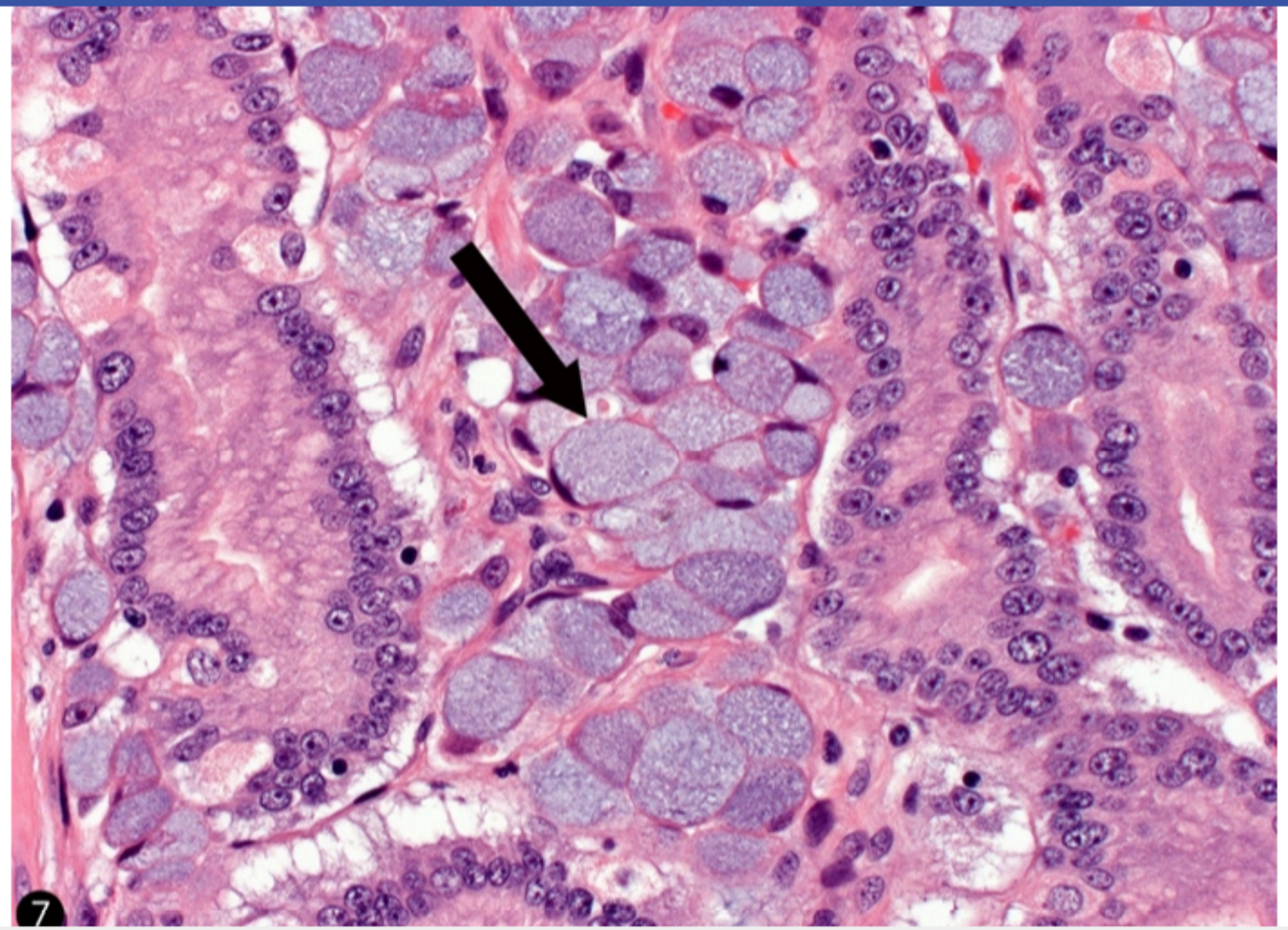

Zoom In | Zoom Out | Reset | Add To New Card | Existing Card

A 43-year-old man comes to the office due to yellowing of the skin over the past several days. He has had no fever or abdominal pain and has not traveled recently or received blood transfusions. The patient has also experienced increased shortness of breath with exercise over the past few months. He has no other medical conditions and takes no medications. The patient drinks 1 or 2 glasses of wine on social occasions and does not use tobacco or illicit drugs. His father died of liver cirrhosis attributed to alcohol use. On physical examination, expiration is prolonged and there are scattered bilateral wheezes. Laboratory results show total bilirubin of 4.1 mg/dL and alanine aminotransferase of 90 U/L. Viral hepatitis serology is negative. Chest x-ray shows hyperlucency of lung fields and flattening of the diaphragm. Abdominal ultrasound reveals increased liver span and echogenicity of the liver parenchyma but no masses. Which of the following is the most likely underlying cause of this patient's symptoms?

- A. Autoimmune injury of the intrahepatic bile ducts
- B. Decreased UDP-glucuronosyltransferase activity
- C. Defective chloride transport at epithelial surfaces
- D. Defective transport and accumulation of copper
- E. Inherited deficiency of a serine protease inhibitor
- F. Unregulated gastrointestinal iron absorption

Submit

A 43-year-old man comes to the office due to yellowing of the skin over the past several days. He has had no fever or abdominal pain and has not traveled recently or received blood transfusions. The patient has also experienced increased shortness of breath with exercise over the past few months. He has no other medical conditions and takes no medications. The patient drinks 1 or 2 glasses of wine on social occasions and does not use tobacco or illicit drugs. His father died of liver cirrhosis attributed to alcohol use. On physical examination, expiration is prolonged and there are scattered bilateral wheezes. Laboratory results show total bilirubin of 4.1 mg/dL and alanine aminotransferase of 90 U/L. Viral hepatitis serology is negative. Chest x-ray shows hyperlucency of lung fields and flattening of the diaphragm. Abdominal ultrasound reveals increased liver span and echogenicity of the liver parenchyma but no masses. Which of the following is the most likely underlying cause of this patient's symptoms?

- A. Autoimmune injury of the intrahepatic bile ducts (8%)
- B. Decreased UDP-glucuronosyltransferase activity (10%)
- C. Defective chloride transport at epithelial surfaces (4%)
- D. Defective transport and accumulation of copper (4%)
- ✓ E. Inherited deficiency of a serine protease inhibitor (67%)
- F. Unregulated gastrointestinal iron absorption (4%)

Omitted
Correct answer
E

67%
Answered correctly

02 secs
Time Spent

01/27/2020
Last Updated

Explanation

1 2 3 4 5 6 7 8 9 10 11 12 13 14 15 16 17 18 19 20 21 22 23 24 25 26 27 28 29 30

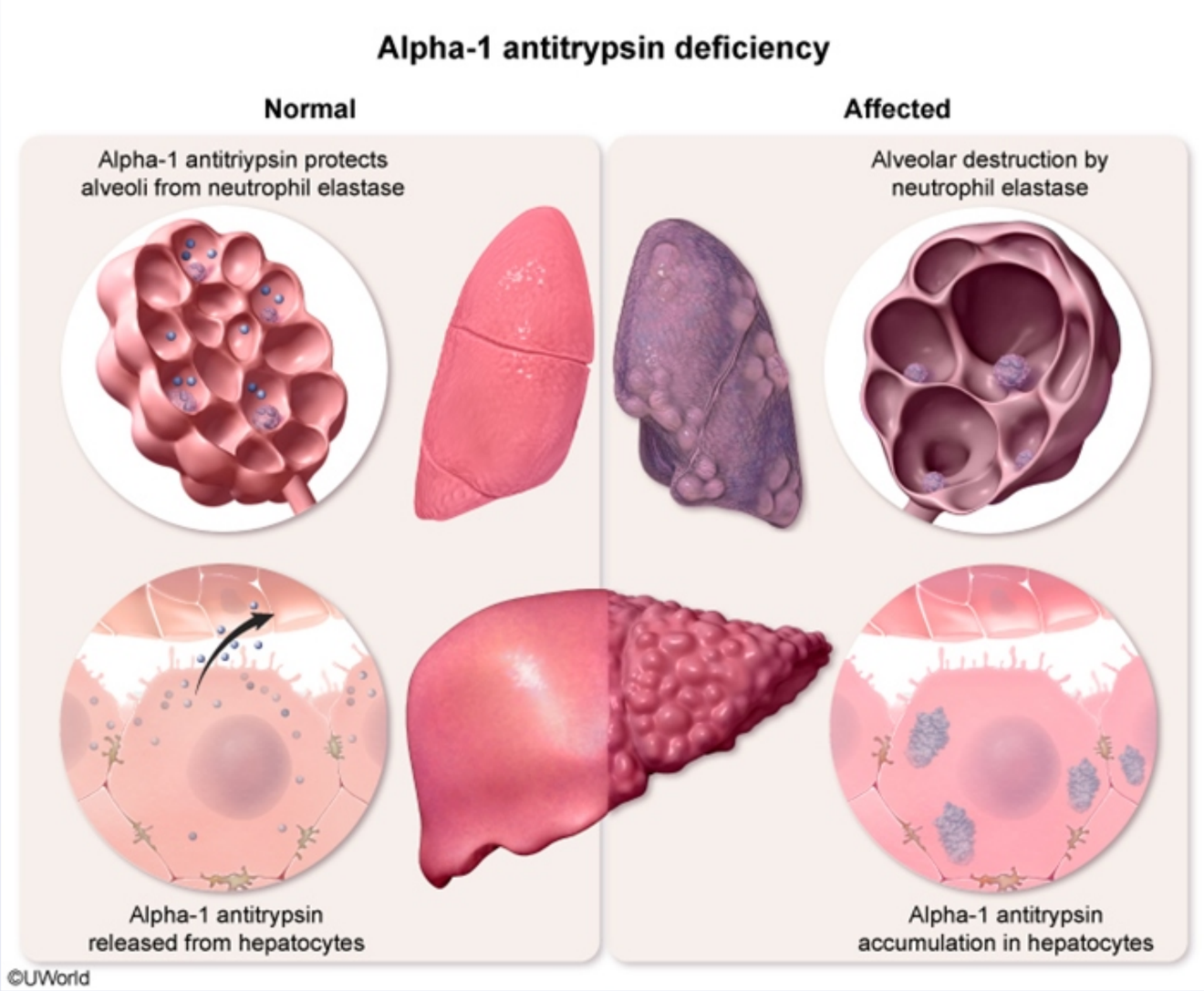

This patient with signs of liver dysfunction (ie, jaundice, transaminitis) and evidence of **emphysema** on chest x-ray (eg, hyperlucency, diaphragmatic flattening) likely has **alpha-1 antitrypsin deficiency** (AATD). Alpha-1 antitrypsin is a **serine protease inhibitor** that regulates the activity of a number of tissue-destructive proteases, most importantly neutrophil **elastase**. Deficiency is inherited in an autosomal codominant fashion.

AATD leads to unchecked elastase activity in the lungs, resulting in alveolar destruction and lung hyperinflation; the panacinar emphysema tends to favor the basilar lung regions and typically develops prior to age 50. In addition, some patients can develop **liver disease** due to accumulation of improperly folded alpha-1 antitrypsin proteins in hepatocytes. Liver disease is of greatest concern in the first 2 decades of life, but it can present in any decade. Patients can experience hepatomegaly, hyperbilirubinemia, elevated transaminases, and eventual cirrhosis and end-stage liver disease. Hepatocellular carcinoma may also develop.

(Choice A) Autoimmune injury of intrahepatic bile ducts occurs in primary biliary cholangitis (PBC, formerly primary biliary cirrhosis). PBC predominantly affects women and is characterized by positive antimitochondrial antibodies. It is not associated with emphysema.

(Choice B) UDP-glucuronosyltransferase is an enzyme that converts unconjugated bilirubin to its conjugated form, and inherited deficiency can exist in varying degrees. Mild deficiency results in benign elevations in unconjugated bilirubin during periods of stress (ie, Gilbert syndrome), while severe deficiency can be fatal during infancy (ie, Crigler-Najjar syndrome type I).

(Choice C) Defective epithelial chloride transport occurs in cystic fibrosis. Patients typically develop obstructive lung disease in the form of bronchiectasis and can have pancreatic insufficiency leading to malabsorption. In addition, cirrhosis can sometimes occur. Cystic fibrosis usually presents during childhood; onset of disease manifestations at age >40 would be highly unusual.

(Choice D) Defective copper transport resulting in accumulation of intracellular copper occurs in Wilson disease. Patients can develop cirrhosis as well as brain degeneration leading to neurologic (eg, dysarthria, gait abnormalities) and psychiatric (eg, impulsivity) manifestations.

(Choice F) Unregulated gastrointestinal iron absorption occurs in hemochromatosis. Patients can develop cirrhosis due to iron overload. The joints (arthritis), pancreas (diabetes mellitus), and heart (cardiomyopathy) are also commonly affected, but lung involvement is not typical.

Educational objective:
Alpha-1 antitrypsin (AAT) is a serine protease inhibitor that regulates the activity of elastase in the lung. Inherited deficiency of AAT leads to

predominantly affects women and is characterized by positive antimitochondrial antibodies. It is not associated with emphysema.

(Choice B) UDP-glucuronosyltransferase is an enzyme that converts unconjugated bilirubin to its conjugated form, and inherited deficiency can exist in varying degrees. Mild deficiency results in benign elevations in unconjugated bilirubin during periods of stress (ie, Gilbert syndrome), while severe deficiency can be fatal during infancy (ie, Crigler-Najjar syndrome type I).

(Choice C) Defective epithelial chloride transport occurs in cystic fibrosis. Patients typically develop obstructive lung disease in the form of bronchiectasis and can have pancreatic insufficiency leading to malabsorption. In addition, cirrhosis can sometimes occur. Cystic fibrosis usually presents during childhood; onset of disease manifestations at age >40 would be highly unusual.

(Choice D) Defective copper transport resulting in accumulation of intracellular copper occurs in Wilson disease. Patients can develop cirrhosis as well as brain degeneration leading to neurologic (eg, dysarthria, gait abnormalities) and psychiatric (eg, impulsivity) manifestations.

(Choice F) Unregulated gastrointestinal iron absorption occurs in hemochromatosis. Patients can develop cirrhosis due to iron overload. The joints (arthritis), pancreas (diabetes mellitus), and heart (cardiomyopathy) are also commonly affected, but lung involvement is not typical.

Educational objective:
Alpha-1 antitrypsin (AAT) is a serine protease inhibitor that regulates the activity of elastase in the lung. Inherited deficiency of AAT leads to alveolar destruction and panacinar emphysema; in addition, accumulation of improperly folded AAT proteins in hepatocytes can lead to liver dysfunction and cirrhosis in some patients.

References

- Diagnosis and management of patients with a1-antitrypsin (A1AT) deficiency.
- An update on laboratory diagnosis of liver inherited diseases.

Pathology	Gastrointestinal & Nutrition	Alpha1 antitrypsin deficiency
Subject	System	Topic

Copyright © UWorld. All rights reserved.

A 50-year-old man is scheduled to undergo a colonoscopy for routine colorectal cancer screening. He has no abdominal pain, gross blood in the stool, constipation, change in stool caliber, or unintentional weight loss. He also has no family history of colon cancer. The procedure is uncomplicated, but the patient is found to have a small mucosal lesion (~1 cm) in his sigmoid colon. The lesion is biopsied and its histology is shown in the image below.

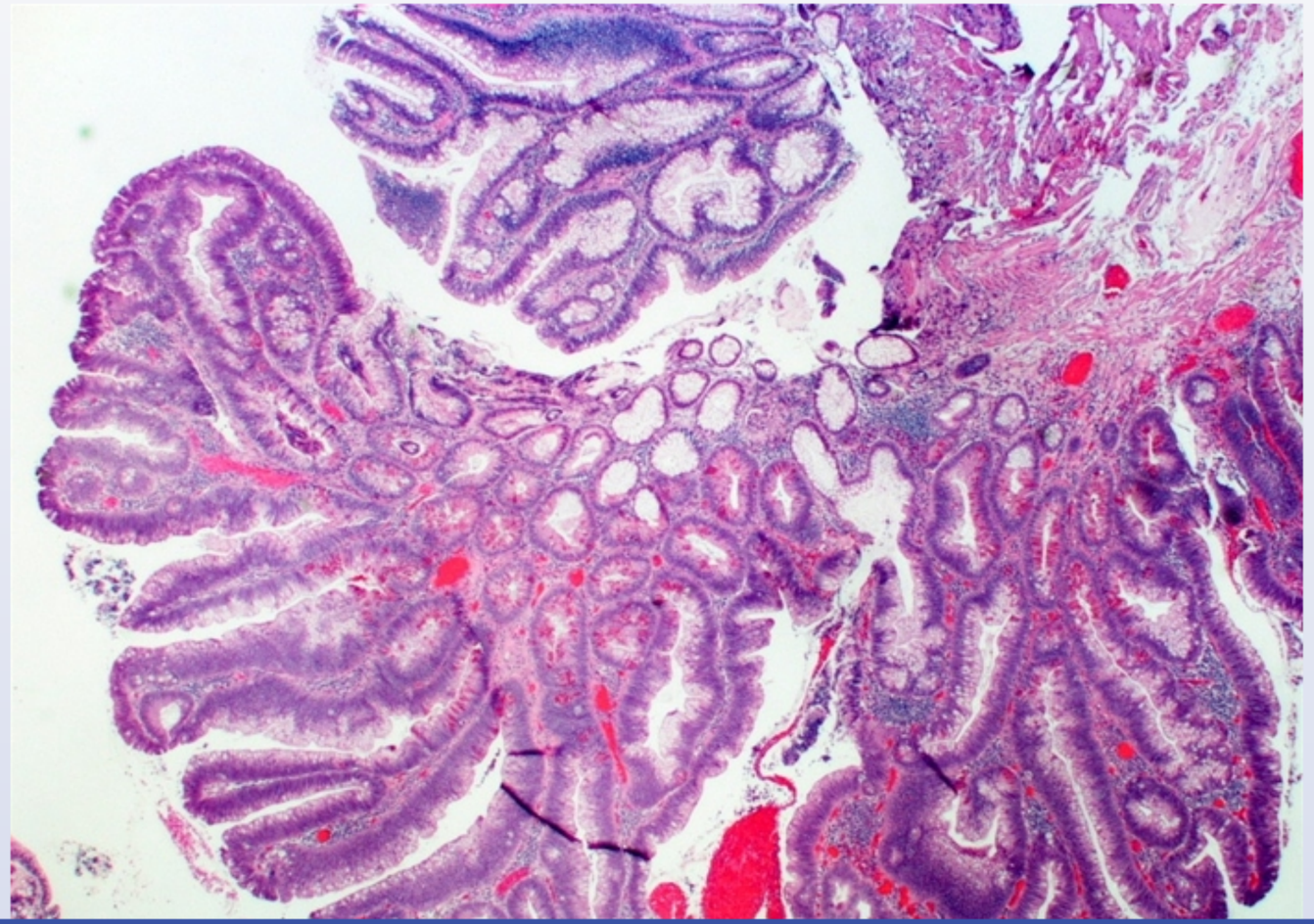

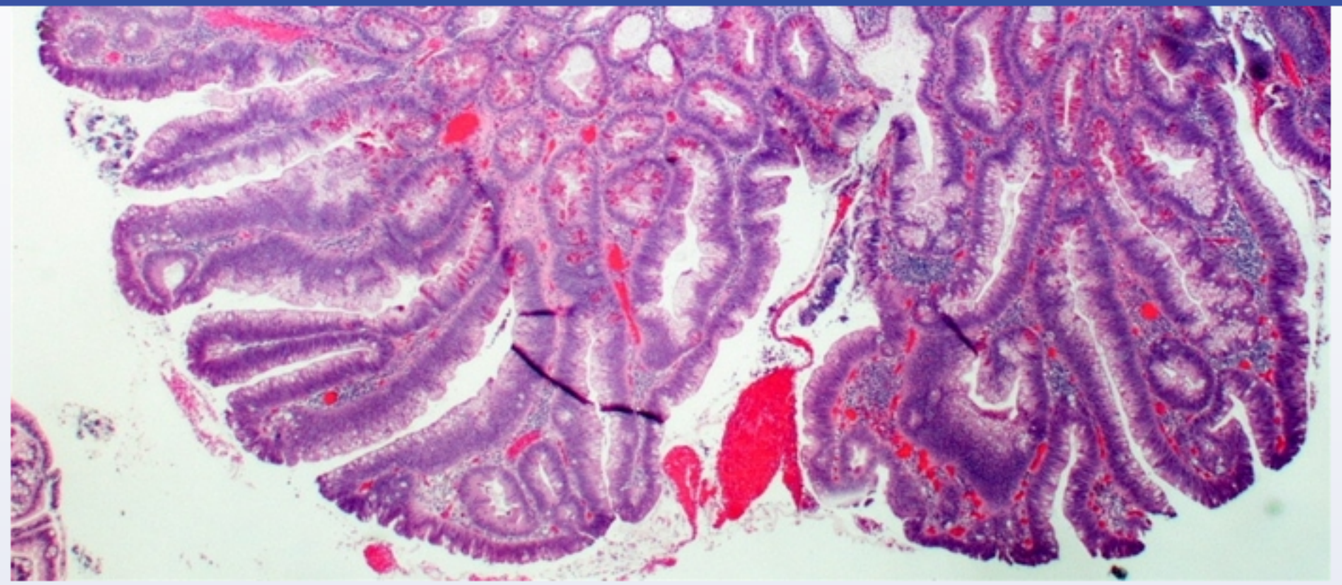

The pathogenesis of this patient's lesion most likely began with a mutation involving which of the following genes?

- A. APC
- B. DCC
- C. K-RAS
- D. MSH2
- E. p53

Submit

1 2 3 4 5 6 7 8 9 10 11 12 13 14 15 16 17 18 19 20 21 22 23 24 25 26 27 28 29 30

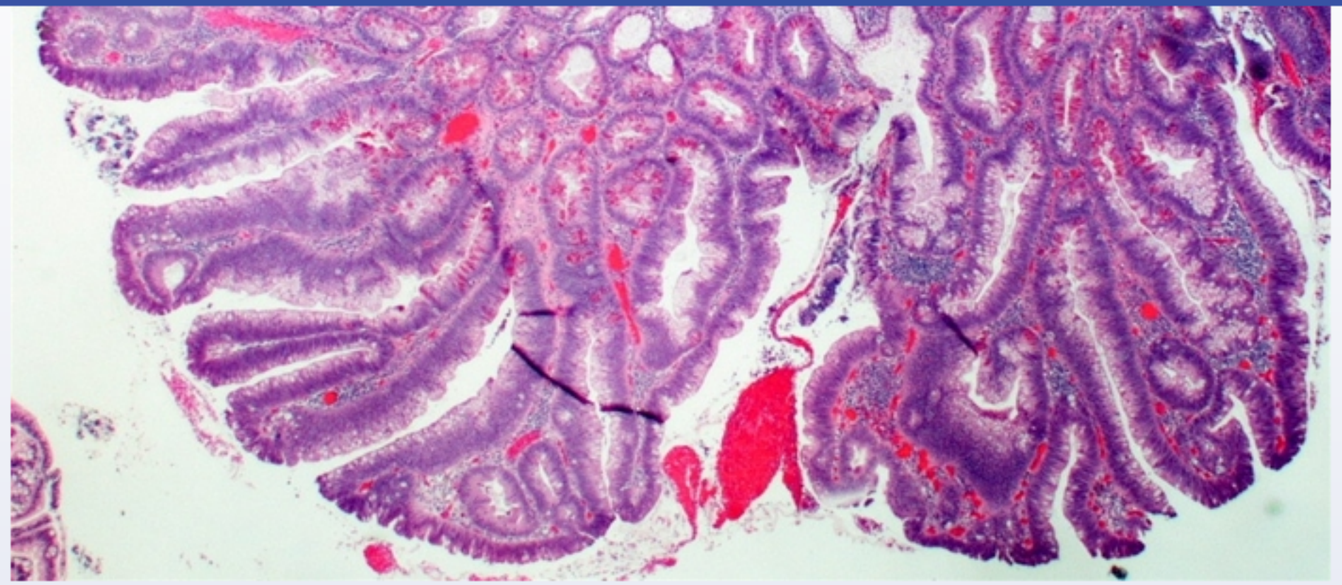

The pathogenesis of this patient's lesion most likely began with a mutation involving which of the following genes?

- ✓ A. APC (77%)
- B. DCC (2%)
- C. K-RAS (9%)
- D. MSH2 (4%)
- E. p53 (5%)

Omitted
Correct answer

77%
Answered correctly

05 secs
Time Spent

06/12/2020
Last Updated

Explanation

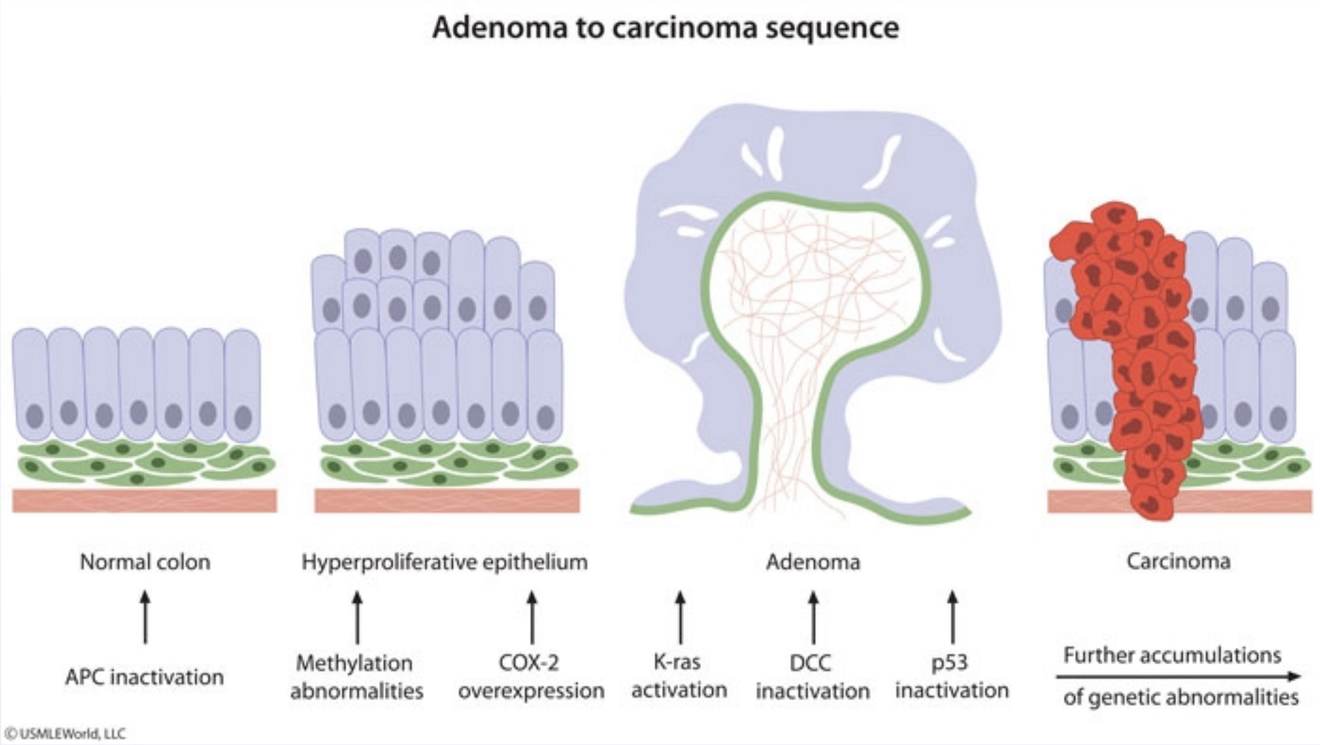

The image above shows a tubulovillous **adenomatous polyp** composed of a fibrovascular stalk with tubular glands and villous components. The glands are lined by dysplastic columnar epithelial cells that are seen in all colonic adenomatous polyps. The malignant potential of an adenomatous polyp is partly determined by the degree of dysplasia. Mildly dysplastic cells are elongated and hyperchromatic and show loss of mucin from the cytoplasm. With continued proliferation, dysplastic cells display increased variation in shape/size (pleomorphism) and the nuclei become enlarged and deeply stained (hyperchromatic). Other findings include an increase in number/size of nucleoli, nuclear-to-cytoplasmic ratio, and number of mitotic figures.

Most cases of **sporadic** colorectal carcinoma arise via the classic adenoma-to-carcinoma sequence (APC/beta-catenin pathway). The **first**

The image above shows a tubulovillous **adenomatous polyp** composed of a fibrovascular stalk with tubular glands and villous components. The glands are lined by dysplastic columnar epithelial cells that are seen in all colonic adenomatous polyps. The malignant potential of an adenomatous polyp is partly determined by the degree of dysplasia. Mildly dysplastic cells are elongated and hyperchromatic and show loss of mucin from the cytoplasm. With continued proliferation, dysplastic cells display increased variation in shape/size (pleomorphism) and the nuclei become enlarged and deeply stained (hyperchromatic). Other findings include an increase in number/size of nucleoli, nuclear-to-cytoplasmic ratio, and number of mitotic figures.

Most cases of **sporadic** colorectal carcinoma arise via the classic adenoma-to-carcinoma sequence (APC/beta-catenin pathway). The **first mutation** in this pathway usually involves the **APC tumor suppressor gene**, which is responsible for regulating cell growth/adhesion. APC gene mutation is also found in all patients with familial adenomatous polyposis. Mutations in K-RAS, DCC (Deleted in Colon Cancer), and p53 occur **later** in the adenoma-to-carcinoma sequence **(Choices B, C, and E)**. K-RAS proto-oncogene and DCC gene mutations lead to unregulated cell proliferation and avoidance of apoptosis, respectively. They are usually observed in larger adenomas (>1 cm) or carcinomas. The p53 tumor suppressor gene regulates the cell cycle and promotes repair of damaged DNA; mutations are found in most colon carcinomas but rarely adenomas.

(Choice D) Mutations in DNA mismatch repair genes such as MLH1 and MSH2 result in microsatellite instability and an accumulation of genetic errors in many of the other genes implicated in colorectal carcinogenesis. Mutations in MLH1 and MSH2 cause hereditary nonpolyposis colorectal cancer (Lynch syndrome) but are not frequently associated with sporadic colorectal carcinoma.

Educational objective:
Mutation of the APC tumor suppressor gene is the first step in the classic adenoma-to-carcinoma sequence; it is found in most cases of sporadic colon cancer and in all patients with familial adenomatous polyposis. The microsatellite instability pathway is characterized by mutations in DNA mismatch repair genes and is implicated in the development of hereditary nonpolyposis colorectal cancer (Lynch syndrome).

References

- The American College of Gastroenterology Emily Couric Lecture--the adenoma-carcinoma sequence revisited: has the era of genetic tailoring finally arrived?
- Colorectal cancer: molecular features and clinical opportunities.

Settings

1 2 3 4 5 6 7 8 9 10 11 12 13 14 15 16 17 18 19 20 21 22 23 24 25 26 27 28 29 30

Item 37 of 40
Question Id: 428

Mark | Previous | Next | Full Screen | Tutorial | Lab Values | Notes | Calculator | Reverse Color | Text Zoom | Settings

The image above shows a tubulevilleous **adenomatous polyp** composed of a fibrovascular stalk with tubular glands and villous components. The

Exhibit Display

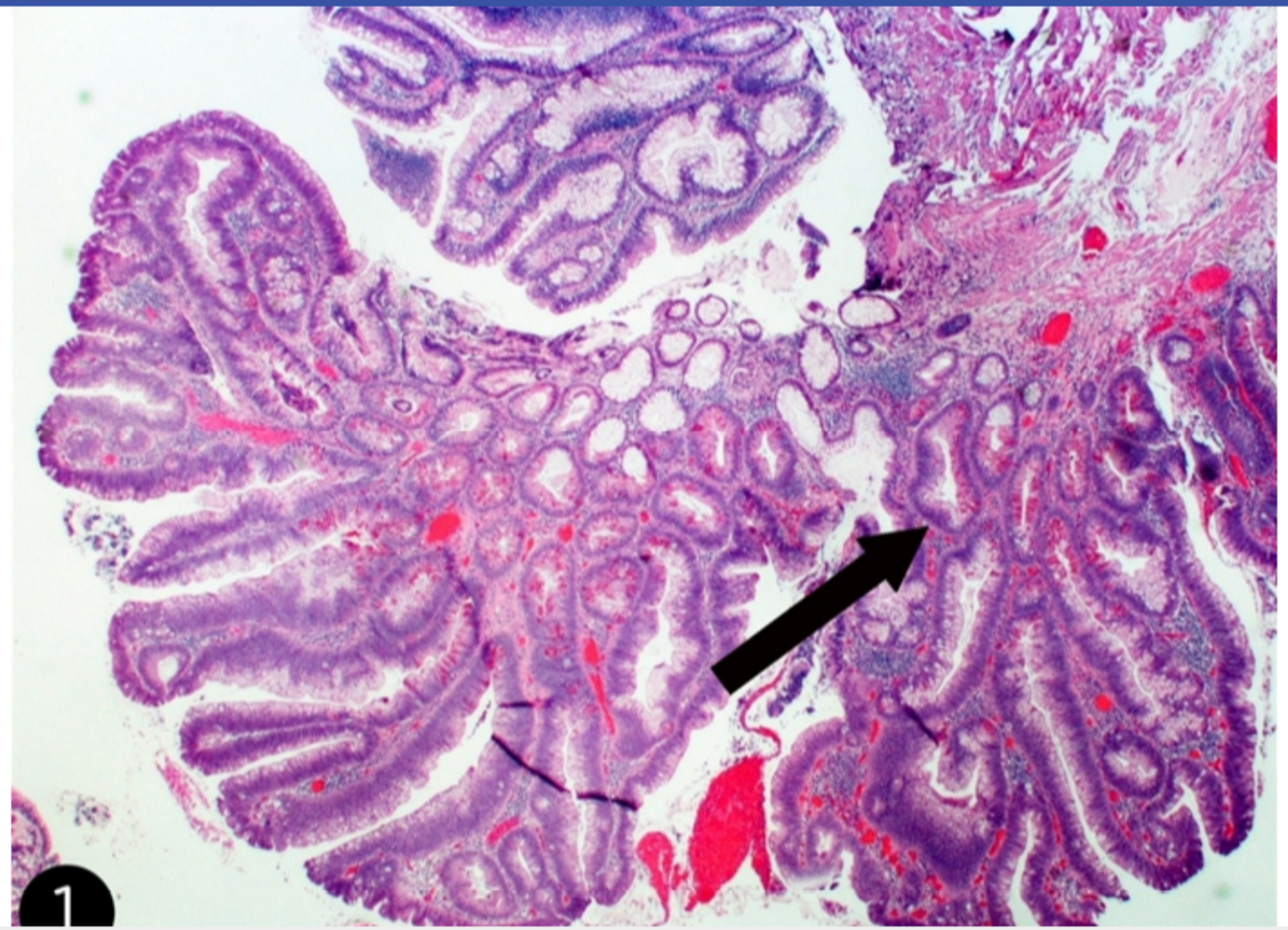

Zoom In | Zoom Out | Reset | Add To New Card | Existing Card

Block Time Remaining: 00:01:44
TUTOR

5 | Feedback | Suspend | End Block

Settings

1 2 3 4 5 6 7 8 9 10 11 12 13 14 15 16 17 18 19 20 21 22 23 24 25 26 27 28 29 30

Item 37 of 40
Question Id: 428

Mark | Previous | Next | Full Screen | Tutorial | Lab Values | Notes | Calculator | Reverse Color | Text Zoom | Settings

The image above shows a tubulovillous **adenomatous polyp** composed of a fibrovascular stalk with tubular glands and villous components. The

Exhibit Display

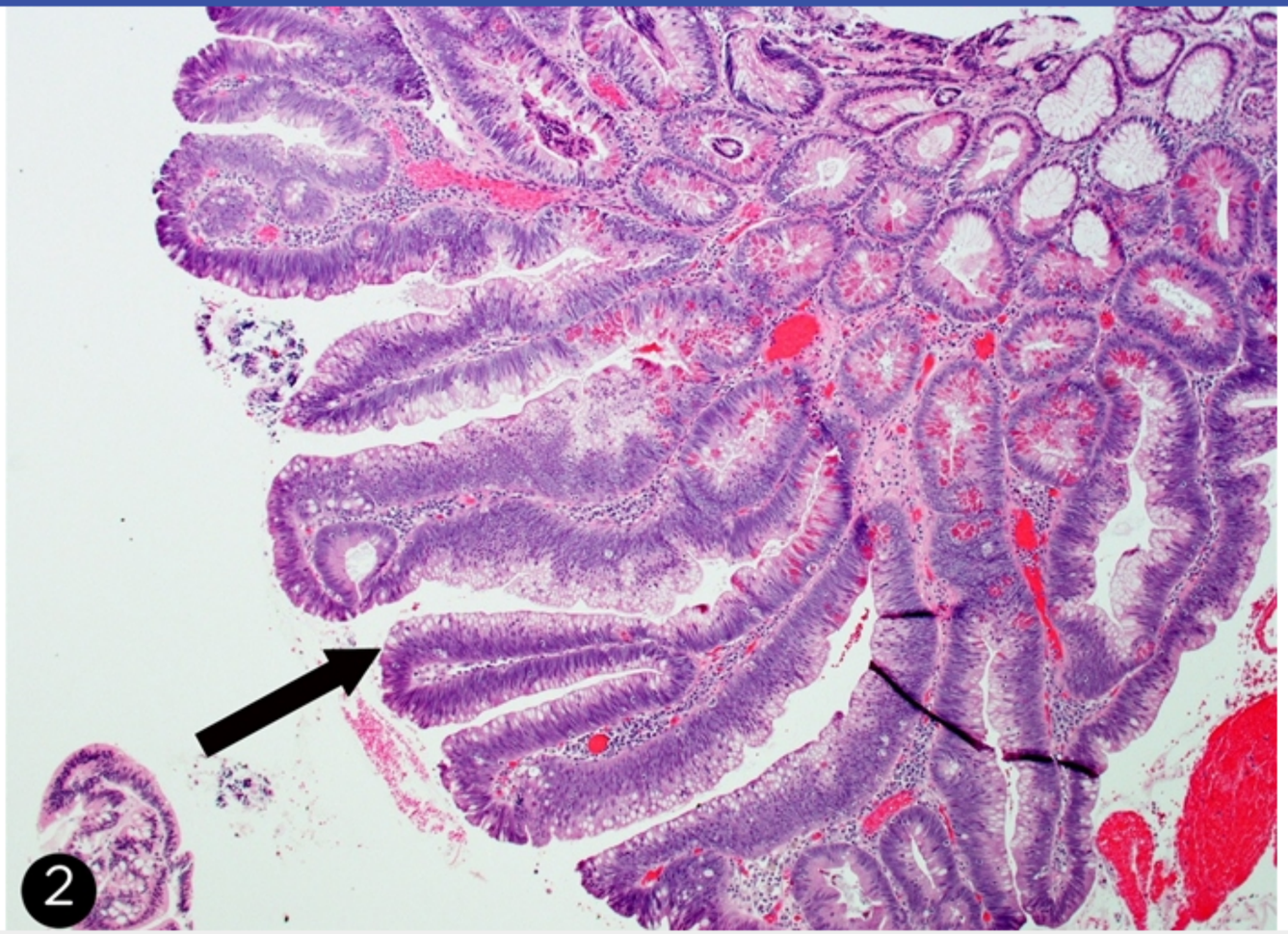

Zoom In | Zoom Out | Reset | Add To New Card | Existing Card

Block Time Remaining: 00:01:44
TUTOR

5 | Feedback | Suspend | End Block

Settings

1 2 3 4 5 6 7 8 9 10 11 12 13 14 15 16 17 18 19 20 21 22 23 24 25 26 27 28 29 30

Item 37 of 40
Question Id: 428

Mark | Previous | Next | Full Screen | Tutorial | Lab Values | Notes | Calculator | Reverse Color | Text Zoom | Settings

The image above shows a tubulevilleous **adenomatous polyp** composed of a fibrovascular stalk with tubular glands and villous components. The

Exhibit Display

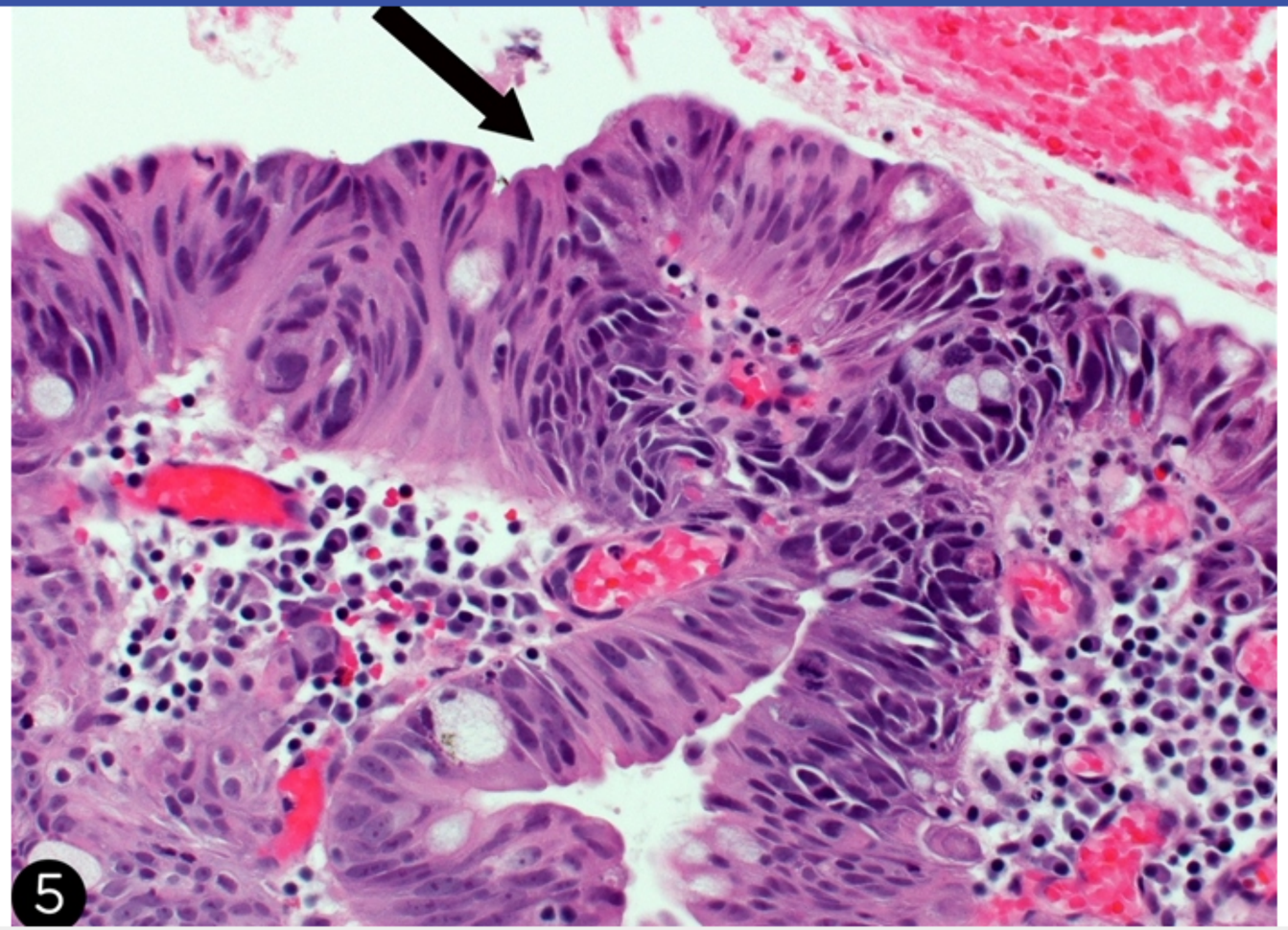

Zoom In | Zoom Out | Reset | Add To New Card | Existing Card

Block Time Remaining: 00:01:44
TUTOR

5 | Feedback | Suspend | End Block

An 18-year-old man is admitted to the hospital with cough, fever, and hypoxemia. Despite multiple intravenous antibiotics and frequent chest physiotherapy, the patient decompensates and is transferred to the intensive care unit for mechanical ventilation. Sputum cultures grow >100,000 colony-forming units of a non-lactose-fermenting gram-negative rod. After several days, the patient dies of overwhelming pneumonia complicated by respiratory failure. Since age 1, he had been hospitalized for recurrent episodes of multi-lobar pneumonia, sinusitis, and poor growth. On autopsy, both vas deferens are absent. Which of the following findings is also likely to be present on autopsy?

A. Distension and obstruction of pancreatic ducts

B. Lobar sequestration

C. Lymphocytic infiltrate of pancreatic islet cells

D. Nodular lymphoid hyperplasia in the intestine

E. Situs inversus

Submit

An 18-year-old man is admitted to the hospital with cough, fever, and hypoxemia. Despite multiple intravenous antibiotics and frequent chest physiotherapy, the patient decompensates and is transferred to the intensive care unit for mechanical ventilation. Sputum cultures grow >100,000 colony-forming units of a non-lactose-fermenting gram-negative rod. After several days, the patient dies of overwhelming pneumonia complicated by respiratory failure. Since age 1, he had been hospitalized for recurrent episodes of multi-lobar pneumonia, sinusitis, and poor growth. On autopsy, both vas deferens are absent. Which of the following findings is also likely to be present on autopsy?

- ✓ A. Distension and obstruction of pancreatic ducts (69%)
- B. Lobar sequestration (1%)
- C. Lymphocytic infiltrate of pancreatic islet cells (3%)
- D. Nodular lymphoid hyperplasia in the intestine (1%)
- E. Situs inversus (24%)

Omitted
Correct answer
A

69%
Answered correctly

01 sec
Time Spent

04/05/2020
Last Updated

Explanation

Clinical features of cystic fibrosis	
	• Obstructive lung disease → bronchiectasis

Clinical features of cystic fibrosis	
Respiratory	• Obstructive lung disease → bronchiectasis • Recurrent pneumonia • Chronic rhinosinusitis

Gastrointestinal	• Obstruction (10%-20%)
	  ○ Meconium ileus
	  ○ Distal intestinal obstruction syndrome
	• Pancreatic disease
	  ○ Exocrine pancreatic insufficiency
	  ○ CF-related diabetes (~25%)
	• Biliary cirrhosis

Reproductive	• Infertility (>95% men, ~20% women)
Musculoskeletal	• Osteopenia → fractures • Kyphoscoliosis • Digital clubbing

©UWorld

Cystic fibrosis transmembrane conductance regulator (CFTR) normally allows for transport of chloride into gastrointestinal and respiratory lumens, followed by sodium and water, leading to thin mucus. In cystic fibrosis (CF), the dysfunctional or absent *CFTR* gene leads to decreased water within the lumen, resulting in **thick, dehydrated, and viscous mucus** within organs.

This patient's **recurrent sinopulmonary infections** and **congenital absence of the vas deferens** are consistent with CF. Pneumonia due to a non-lactose-fermenting, gram-negative rod (*Pseudomonas aeruginosa* or *Burkholderia cepacia*) is very common.

©UWorld

Cystic fibrosis transmembrane conductance regulator (CFTR) normally allows for transport of chloride into gastrointestinal and respiratory lumens, followed by sodium and water, leading to thin mucus. In cystic fibrosis (CF), the dysfunctional or absent *CFTR* gene leads to decreased water within the lumen, resulting in **thick, dehydrated, and viscous mucus** within organs.

This patient's **recurrent sinopulmonary infections** and **congenital absence of the vas deferens** are consistent with CF. Pneumonia due to a non-lactose-fermenting, gram-negative rod (*Pseudomonas aeruginosa* or *Burkholderia cepacia*) is very common.

The most common gastrointestinal manifestation of CF is **pancreatic insufficiency (PI)**. Pancreatic duct obstruction and distension due to viscous mucus and subsequent inflammation develop in utero, eventually leading to fibrosis. PI is present from birth in most patients with CF. The loss of pancreatic tissue prevents these patients from developing pancreatitis. PI results in inability to absorb fats and fat-soluble vitamins (ADEK), leading to **steatorrhea** and **failure to thrive**. Patients with PI require **pancreatic enzyme supplementation**.

(Choice B) Bronchopulmonary sequestration is a congenital malformation characterized by extra, nonfunctional lung tissue without communication to the tracheobronchial tree. The extra tissue can be within a lung lobe or outside of the lungs and can present as recurrent pneumonia in the same focal site.

(Choice C) Lymphocytic infiltration of pancreatic islet cells is seen in the pathogenesis of type 1 diabetes mellitus. One or more autoantigens within these cells serves as a target for autoimmune attack, eventually leading to destruction of insulin-producing pancreatic cells.

(Choice D) Nodular lymphoid hyperplasia of the intestine is classically seen in common variable immunodeficiency syndrome (CVID), a disorder of low immunoglobulin and B lymphocyte levels that predisposes to recurrent sinopulmonary and gastrointestinal infections. Congenital absence of the vas deferens is not associated with CVID.

(Choice E) Situs inversus refers to transposition of the major internal organs (eg, dextrocardia). It is associated with primary ciliary dyskinesia (or Kartagener syndrome), in which inefficient cilia in multiple organs fail to beat synchronously and clear mucus. Recurrent sinopulmonary infections and bronchiectasis result, but absence of the vas deferens does not occur.

Educational objective:
The most common gastrointestinal disorder in patients with cystic fibrosis is pancreatic insufficiency. Mutations in the cystic fibrosis transmembrane conductance regulator gene lead to thick, viscous secretions in the lumens of the pancreas, resulting in obstruction, inflammation,

(ABER), leading to **steatorrhea** and **failure to thrive**. Patients with P require **pancreatic enzyme supplementation**.

(Choice B) Bronchopulmonary sequestration is a congenital malformation characterized by extra, nonfunctional lung tissue without communication to the tracheobronchial tree. The extra tissue can be within a lung lobe or outside of the lungs and can present as recurrent pneumonia in the same focal site.

(Choice C) Lymphocytic infiltration of pancreatic islet cells is seen in the pathogenesis of type 1 diabetes mellitus. One or more autoantigens within these cells serves as a target for autoimmune attack, eventually leading to destruction of insulin-producing pancreatic cells.

(Choice D) Nodular lymphoid hyperplasia of the intestine is classically seen in common variable immunodeficiency syndrome (CVID), a disorder of low immunoglobulin and B lymphocyte levels that predisposes to recurrent sinopulmonary and gastrointestinal infections. Congenital absence of the vas deferens is not associated with CVID.

(Choice E) Situs inversus refers to transposition of the major internal organs (eg, dextrocardia). It is associated with primary ciliary dyskinesia (or Kartagener syndrome), in which inefficient cilia in multiple organs fail to beat synchronously and clear mucus. Recurrent sinopulmonary infections and bronchiectasis result, but absence of the vas deferens does not occur.

Educational objective:
The most common gastrointestinal disorder in patients with cystic fibrosis is pancreatic insufficiency. Mutations in the cystic fibrosis transmembrane conductance regulator gene lead to thick, viscous secretions in the lumens of the pancreas, resulting in obstruction, inflammation, and subsequent fibrosis. Clinical manifestations include steatorrhea, failure to thrive, and deficiency of fat-soluble vitamins.

References

- Cystic fibrosis.
- Gastrointestinal disorders in cystic fibrosis.

Pathology	Gastrointestinal & Nutrition	Cystic fibrosis
Subject	System	Topic

Copyright © UWorld. All rights reserved.

A 65-year-old man with a history of chronic gastroesophageal reflux comes to the clinic due to dysphagia. The patient has had difficulty swallowing foods such as steak or hard-boiled eggs but is able to drink hot tea and coffee without any issues. Increasing the frequency of his proton pump inhibitor to twice daily did not improve symptoms. He has also lost 6.8 kg (15 lb) over the past 4 months. The patient has a history of hypertension, hyperlipidemia, and osteoarthritis. Medications include amlodipine, atorvastatin, and ibuprofen as needed. He drinks 2 or 3 glasses of wine with dinner most nights but does not use tobacco or illicit drugs. Vital signs are within normal limits. BMI is 32 kg/m^2. Physical examination is unremarkable. Esophagogastroduodenoscopy reveals a 4-cm mass surrounded by a large segment of discolored mucosa in the lower half of the esophagus. Esophagogastrectomy results are shown in the image below:

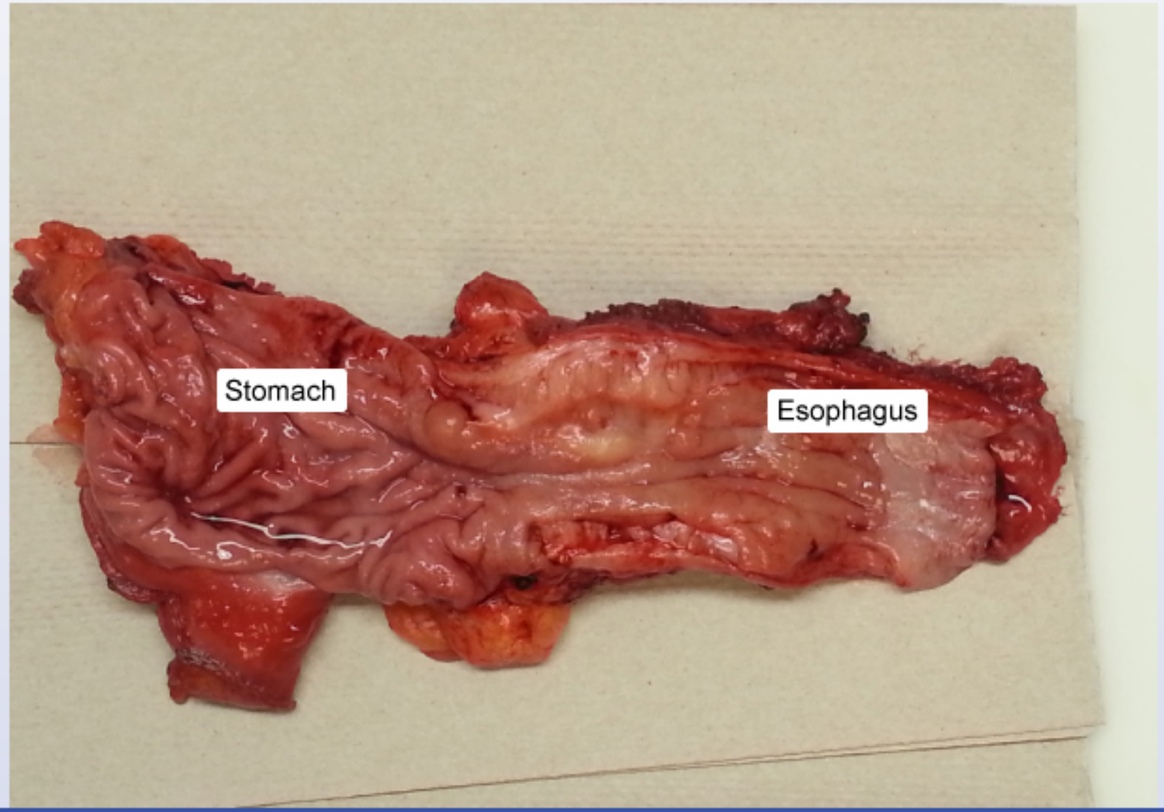

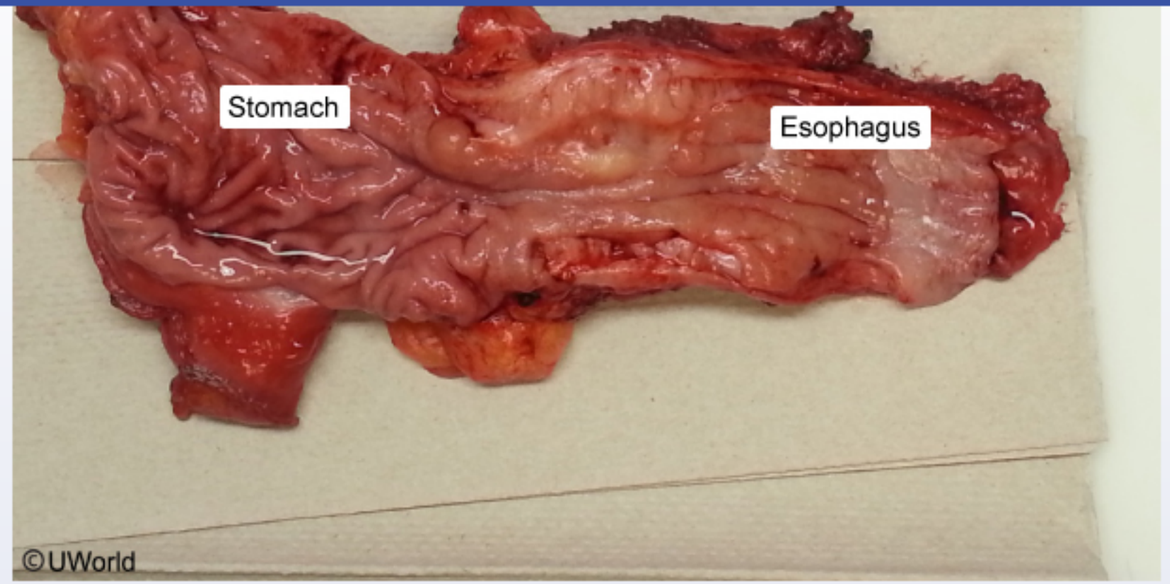

Which of the following is the most likely predisposing factor for this patient's esophageal disease?

- A. Alcohol use
- B. Chronic nonsteroidal anti-inflammatory drug use
- C. *Helicobacter pylori* infection
- D. Obesity
- E. Repeated thermal injury

Submit

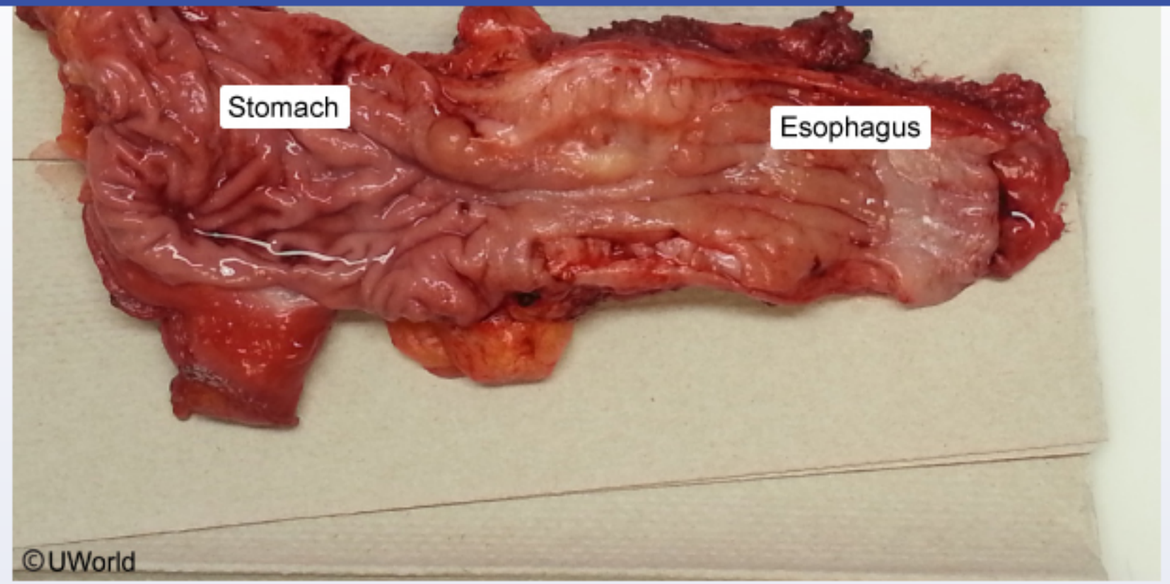

Which of the following is the most likely predisposing factor for this patient's esophageal disease?

- A. Alcohol use (24%)
- B. Chronic nonsteroidal anti-inflammatory drug use (8%)
- C. *Helicobacter pylori* infection (16%)
- ✓ D. Obesity (39%)
- E. Repeated thermal injury (11%)

Omitted
Correct answer

39%
Answered correctly

04 secs
Time Spent

01/28/2020
Last Updated

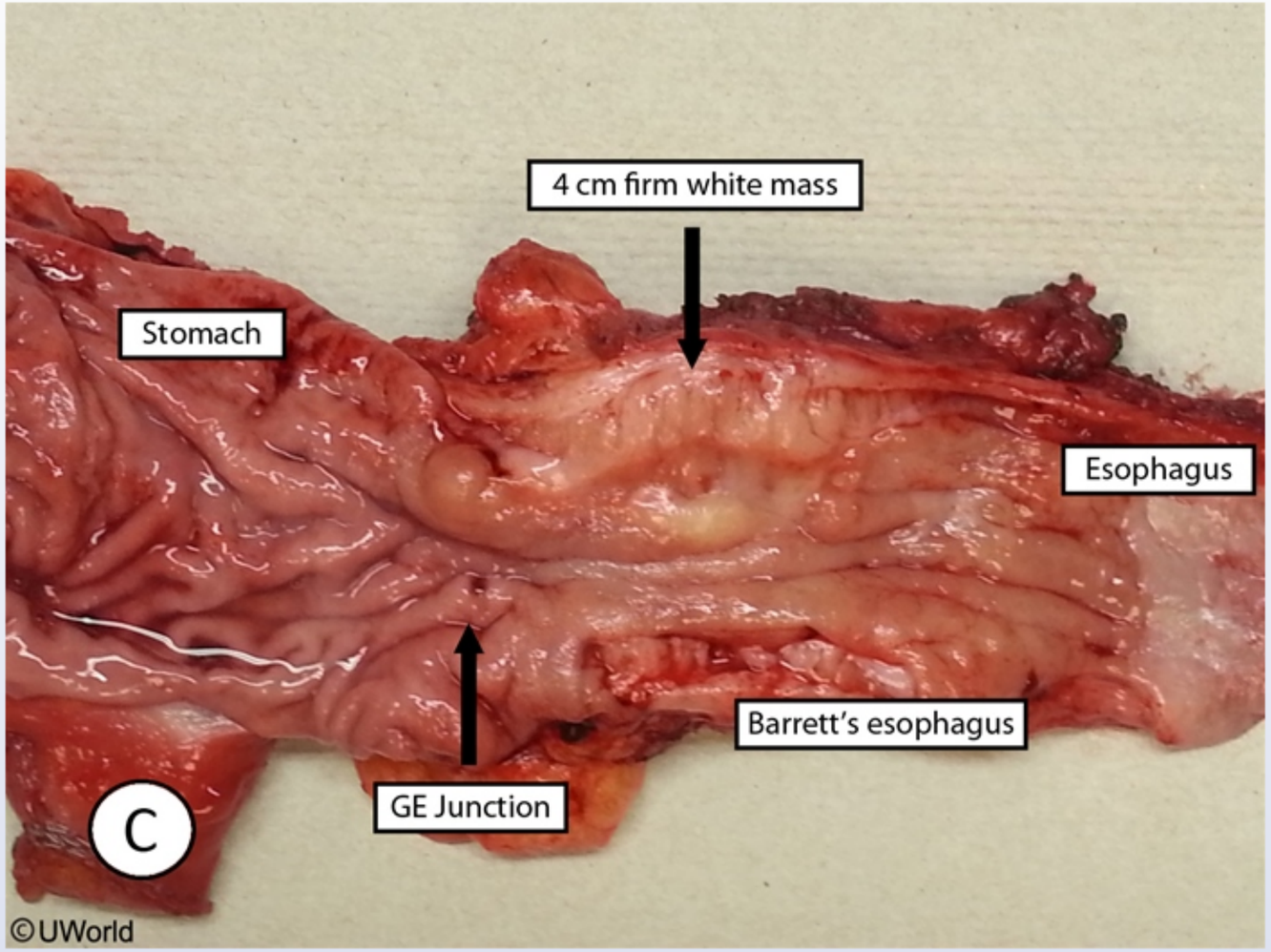

This patient with chronic gastroesophageal reflux disease (GERD) now has dysphagia with solid foods, weight loss, and a mass in his lower esophagus, raising strong suspicion for **esophageal adenocarcinoma**. Most cases of esophageal adenocarcinoma arise in the setting of **Barrett esophagus**, a metaplastic condition whereby the normal stratified squamous epithelium in the distal esophagus is replaced with intestine-like columnar cells in response to chronic acidic damage. Although these metaplastic columnar cells are better suited to handle the presence of acid

This patient with chronic gastroesophageal reflux disease (GERD) now has dysphagia with solid foods, weight loss, and a mass in his lower esophagus, raising strong suspicion for **esophageal adenocarcinoma**. Most cases of esophageal adenocarcinoma arise in the setting of **Barrett esophagus**, a metaplastic condition whereby the normal stratified squamous epithelium in the distal esophagus is replaced with intestine-like columnar cells in response to chronic acidic damage. Although these metaplastic columnar cells are better suited to handle the presence of acid in the distal esophagus, they are also much more likely to become dysplastic and undergo malignant transformation into esophageal adenocarcinoma.

Major risk factors for esophageal adenocarcinoma are similar to those that promote Barrett esophagus and include:

- **Chronic GERD**
- **Obesity** - increases intragastric pressure, frequency of lower esophageal sphincter relaxation, and rates of hiatal hernia, which promote GERD
- Smoking
- Use of medications that lower esophageal sphincter pressure (eg, nitroglycerin)
- Consumption of foods containing nitroso compounds (eg, processed meats)

(Choice A) Alcohol is a risk factor for esophageal squamous cell carcinoma, which typically arises in the mid-esophagus from areas of esophageal squamous dysplasia. Alcohol does not appear to increase the risk of Barrett esophagus, and wine may be protective.

(Choice B) Aspirin and other nonsteroidal anti-inflammatory drugs may be protective against esophageal cancer, especially in the setting of Barrett esophagus. These drugs may also be protective against colorectal cancer.

(Choice C) *Helicobacter pylori* is an important risk factor for gastric adenocarcinoma and gastric mucosa–associated lymphoid tissue; it does not appear to increase risk for esophageal adenocarcinoma.

(Choice E) Thermal injury due to drinking hot beverages may increase the risk of esophageal squamous cell carcinoma but is not clearly associated with esophageal adenocarcinoma.

- Smoking
- Use of medications that lower esophageal sphincter pressure (eg, nitroglycerin)
- Consumption of foods containing nitroso compounds (eg, processed meats)

(Choice A) Alcohol is a risk factor for esophageal squamous cell carcinoma, which typically arises in the mid-esophagus from areas of esophageal squamous dysplasia. Alcohol does not appear to increase the risk of Barrett esophagus, and wine may be protective.

(Choice B) Aspirin and other nonsteroidal anti-inflammatory drugs may be protective against esophageal cancer, especially in the setting of Barrett esophagus. These drugs may also be protective against colorectal cancer.

(Choice C) *Helicobacter pylori* is an important risk factor for gastric adenocarcinoma and gastric mucosa–associated lymphoid tissue; it does not appear to increase risk for esophageal adenocarcinoma.

(Choice E) Thermal injury due to drinking hot beverages may increase the risk of esophageal squamous cell carcinoma but is not clearly associated with esophageal adenocarcinoma.

Educational objective:
Esophageal adenocarcinoma usually occurs in the distal esophagus due to underlying Barrett esophagus. Long-standing gastroesophageal reflux disease is the most important risk factor. Obesity, smoking, use of medications that lower esophageal sphincter pressure, and consumption of foods containing nitroso compounds also increase the risk.

References

- Epidemiology, diagnosis, and management of esophageal adenocarcinoma.
- Etiology and prevention of esophageal cancer.

Pathology	Gastrointestinal & Nutrition	Esophageal cancer
Subject	System	Topic

Copyright © UWorld. All rights reserved.

A 68-year-old woman comes to the emergency department due to shortness of breath, poor appetite, and abdominal distension for the past 3 months. Her symptoms have progressively worsened, and now she is unable to perform her daily activities. The patient has a history of coronary artery disease and underwent coronary artery bypass grafting 3 years ago. She also has myelodysplastic syndrome for which she receives intermittent blood transfusions. Physical examination shows jugular venous distension, abdominal distension, hepatomegaly, and lower extremity edema. A representative liver biopsy image is shown in the exhibit. Which of the following is the most likely cause of this patient's liver findings?

A. Autoimmune biliary destruction

B. Excessive deposition of iron

C. Hepatitis virus infection

D. Metastatic spread to the liver

E. Passive hepatic congestion

Submit

Settings

1 2 3 4 5 6 7 8 9 10 11 12 13 14 15 16 17 18 19 20 21 22 23 24 25 26 27 28 29 30

Item 40 of 40
Question Id: 15535

Mark | Previous | Next | Full Screen | Tutorial | Lab Values | Notes | Calculator | Reverse Color | Text Zoom | Settings

Exhibit Display

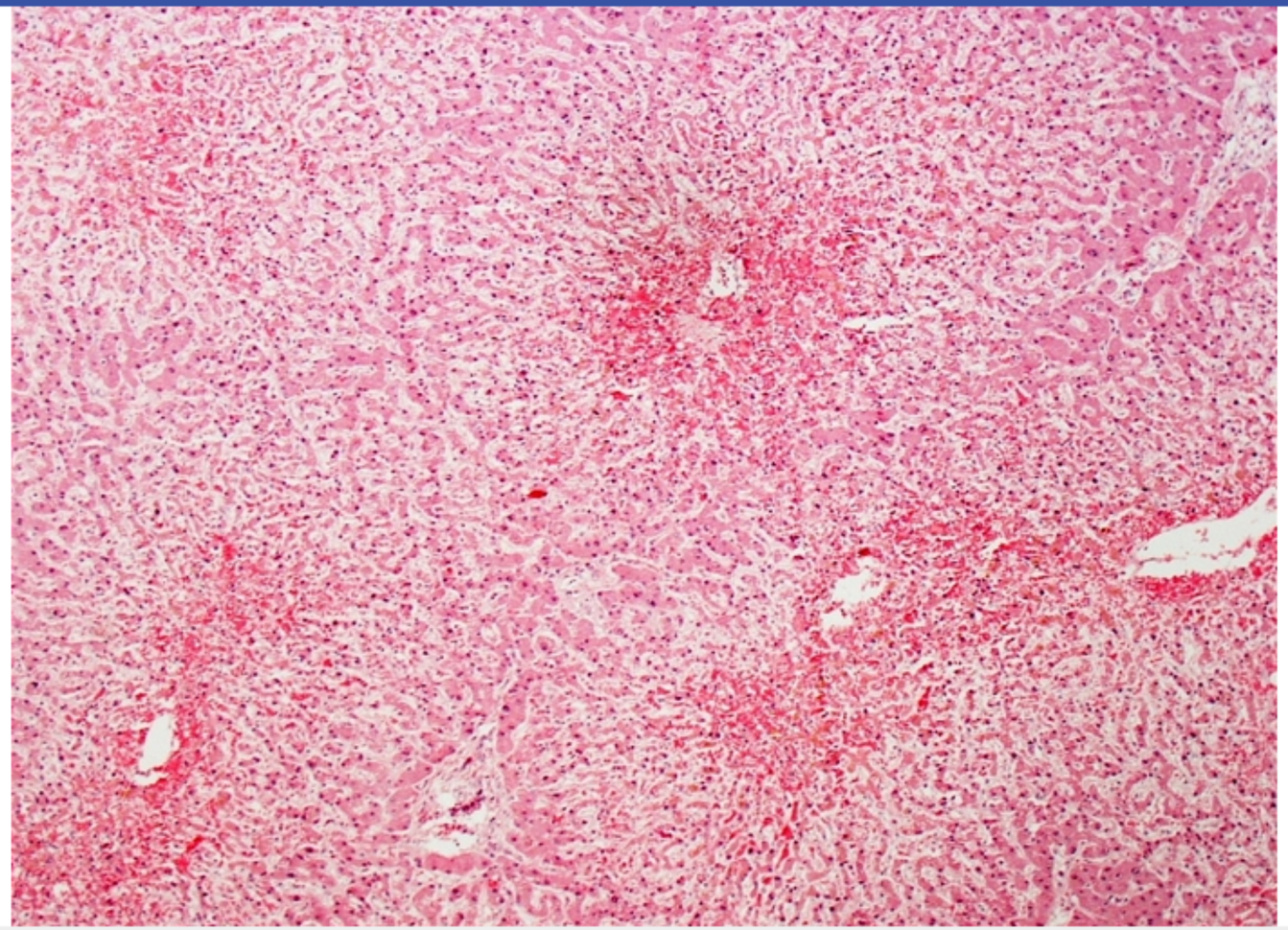

Zoom In | Zoom Out | Reset | Add To New Card | Existing Card

Block Time Remaining: 00:01:53
TUTOR

8 | Feedback | Suspend | End Block

A 68-year-old woman comes to the emergency department due to shortness of breath, poor appetite, and abdominal distension for the past 3 months. Her symptoms have progressively worsened, and now she is unable to perform her daily activities. The patient has a history of coronary artery disease and underwent coronary artery bypass grafting 3 years ago. She also has myelodysplastic syndrome for which she receives intermittent blood transfusions. Physical examination shows jugular venous distension, abdominal distension, hepatomegaly, and lower extremity edema. A representative liver biopsy image is shown in the exhibit. Which of the following is the most likely cause of this patient's liver findings?

- A. Autoimmune biliary destruction (3%)
- B. Excessive deposition of iron (25%)
- C. Hepatitis virus infection (8%)
- D. Metastatic spread to the liver (1%)
- ✓ E. Passive hepatic congestion (61%)

Omitted
Correct answer
E

61%
Answered correctly

06 secs
Time Spent

01/27/2020
Last Updated

Explanation

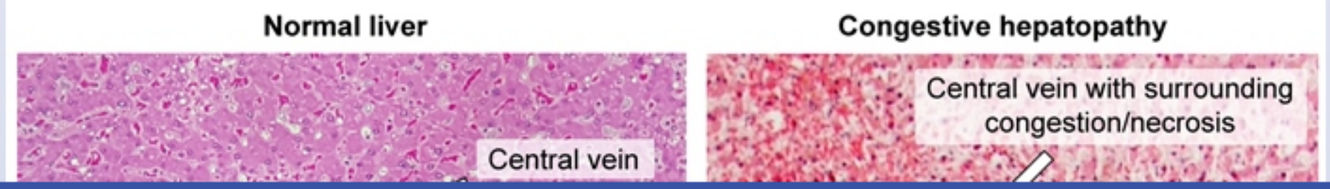

1 2 3 4 5 6 7 8 9 10 11 12 13 14 15 16 17 18 19 20 21 22 23 24 25 26 27 28 29 30

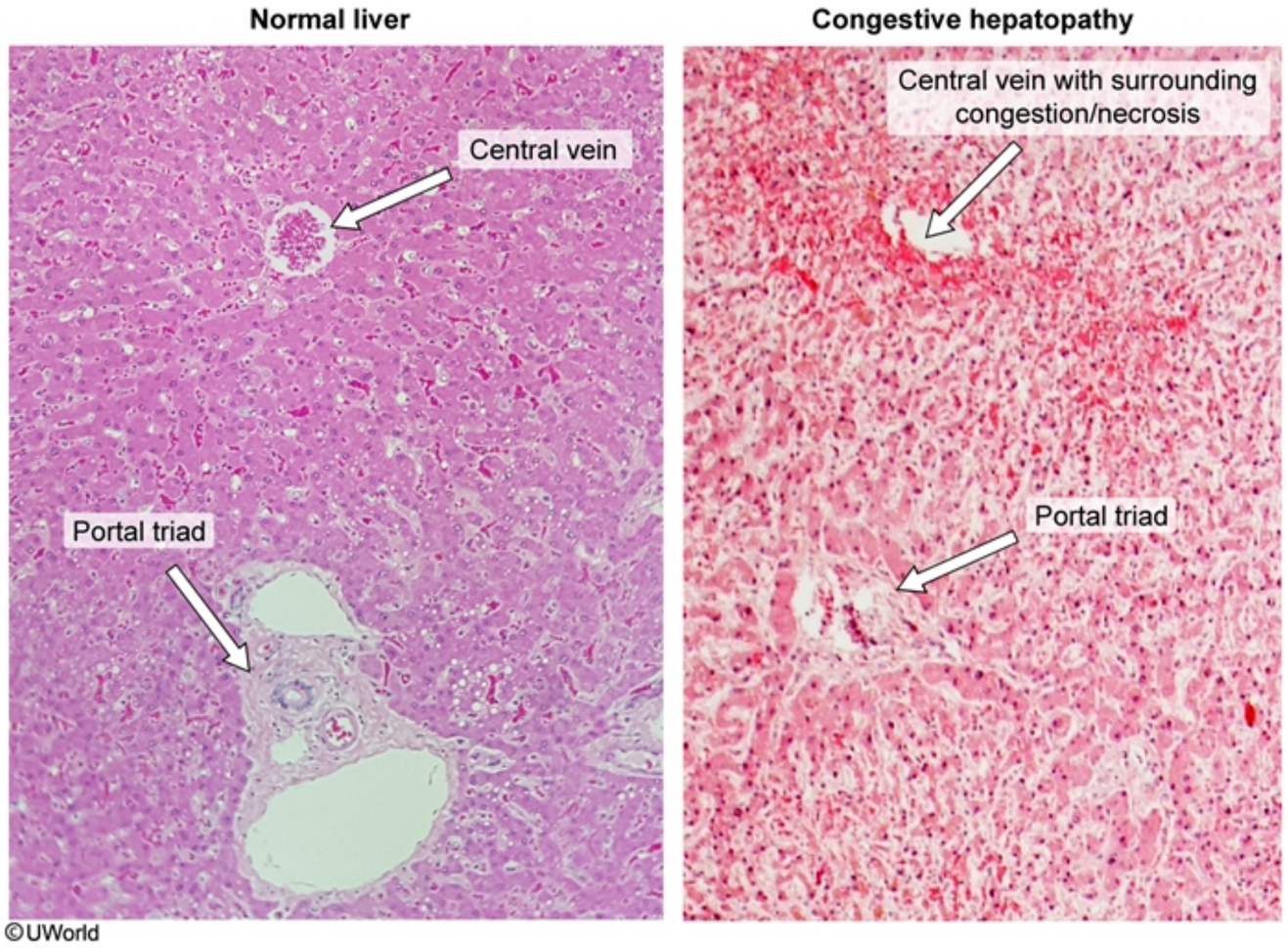

This patient's shortness of breath—accompanied by abdominal distension (ascites), hepatomegaly, jugular venous distension, and lower extremity edema—is consistent with **right-sided heart failure**; her liver biopsy demonstrates evidence of **congestive hepatopathy**.

In congestive hepatopathy, outflow of blood from the hepatic veins is impeded by elevated right atrial and vena caval pressures, which leads to **increased hydrostatic pressure** in the central veins of the liver. There is consequent seepage of fluid into the surrounding hepatocytes with

This patient's shortness of breath—accompanied by abdominal distension (ascites), hepatomegaly, jugular venous distension, and lower extremity edema—is consistent with **right-sided heart failure**; her liver biopsy demonstrates evidence of **congestive hepatopathy**.

In congestive hepatopathy, outflow of blood from the hepatic veins is impeded by elevated right atrial and vena caval pressures, which leads to **increased hydrostatic pressure** in the central veins of the liver. There is consequent seepage of fluid into the surrounding hepatocytes with resulting congestion and hepatic necrosis. The hepatocellular damage favors the centrilobular areas (zone 3) where congestion is most prominent. On microscopy, patchy hemorrhage is seen surrounding the central veins consistent with **centrilobular necrosis**. These areas of necrosis contrast with the relatively normal-appearing hepatocytes in the periportal regions (zone 1), creating an overall heterogenous appearance sometimes referred to as "**nutmeg liver**."

In addition to signs and symptoms of right-sided heart failure, patients with congestive hepatopathy may have localized right upper quadrant pain (due to stretching of the hepatic capsule), and laboratory results may demonstrate modest elevations in serum bilirubin and transaminases.

(Choice A) Autoimmune destruction of intrahepatic biliary ducts occurs in primary biliary cholangitis (formerly primary biliary cirrhosis). Because intrahepatic bile ducts are concentrated in the periportal regions, histopathology demonstrates periductal fibrosis predominantly in those regions.

(Choice B) Excessive hepatic deposition of iron most commonly occurs due to hemochromatosis. Patients receiving frequent blood transfusions are also at risk; however, histopathology would demonstrate periportal fibrosis and numerous brown pigments representing iron deposits. Fibrosis favors the periportal regions likely because those hepatocytes are exposed to the highest concentrations of iron-rich blood coming from the portal vein.

(Choice C) Histopathology in chronic viral hepatitis (eg, chronic hepatitis C) reveals dense infiltrate of mononuclear inflammatory cells in the periportal regions; there is often gradual development of periportal fibrosis that may eventually bridge to the centrilobular regions.

(Choice D) Histopathology of metastatic spread to the liver is unlikely to demonstrate a consistent pattern of lobular necrosis, but it can reveal an abrupt demarcation between normal hepatocellular tissue and the metastatic tumor.

Educational objective:
Congestive hepatopathy is a common complication of right-sided heart failure. Patchy hemorrhage and necrosis predominantly affect the centrilobular regions (zone 3) where hepatic congestion is most prominent. The centrilobular necrosis, combined with relatively normal-appearing periportal regions (zone 1), creates an overall heterogenous appearance sometimes referred to as "nutmeg liver."

©UWorld

Exhibit Display

The Liver

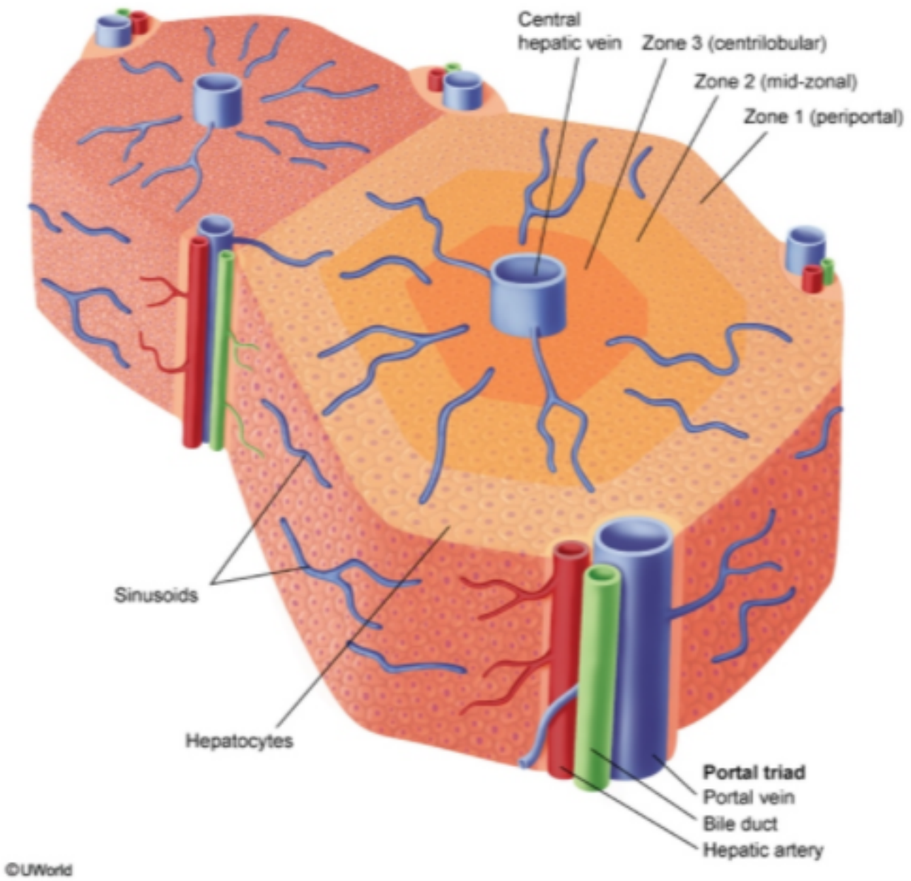

Zoom In | Zoom Out | Reset | Add To New Card | Existing Card

centrilobular regions (zone 3) where hepatic congestion is most prominent. The centrilobular necrosis, combined with relatively normal appearing

Settings

1 2 3 4 5 6 7 8 9 10 11 12 13 14 15 16 17 18 19 20 21 22 23 24 25 26 27 28 29 30

Item 40 of 40
Question Id: 15535

Mark | Previous | Next | Full Screen | Tutorial | Lab Values | Notes | Calculator | Reverse Color | Text Zoom | Settings

©UWorld

Exhibit Display

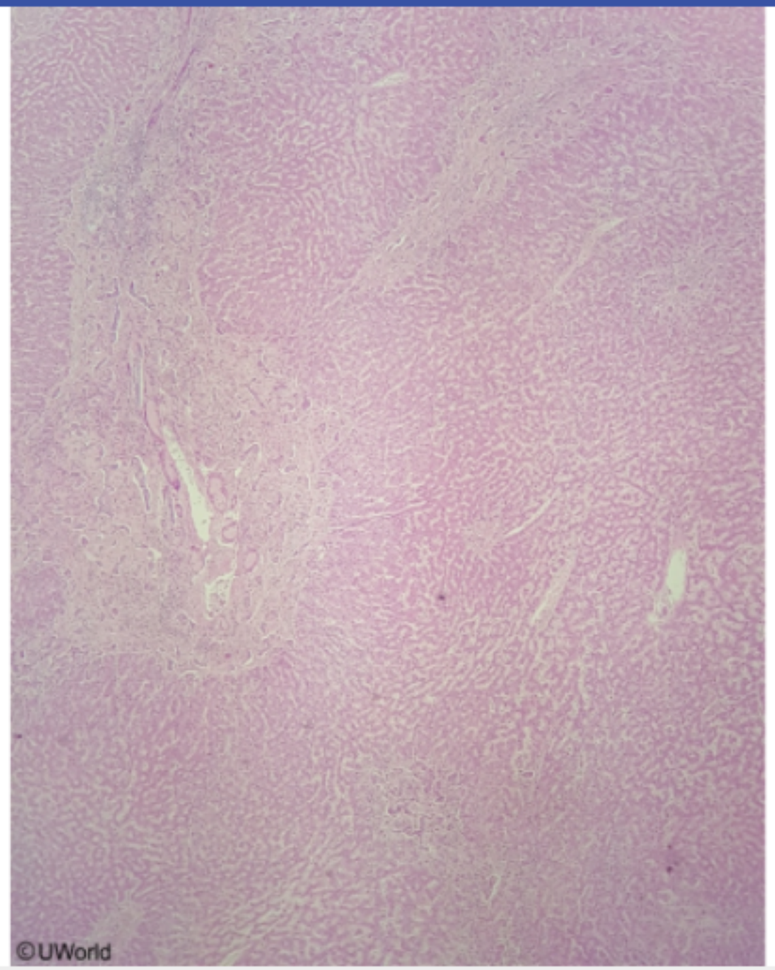

Zoom In | Zoom Out | Reset | Add To New Card | Existing Card

centrilobular regions (zone 3) where hepatic congestion is most prominent. The centrilobular necrosis, combined with relatively normal appearing

Block Time Remaining: 00:01:55
TUTOR

8 | Feedback | Suspend | End Block

Settings

1 2 3 4 5 6 7 8 9 10 11 12 13 14 15 16 17 18 19 20 21 22 23 24 25 26 27 28 29 30

Item 40 of 40
Question Id: 15535

Mark | Previous | Next | Full Screen | Tutorial | Lab Values | Notes | Calculator | Reverse Color | Text Zoom | Settings

©UWorld

Exhibit Display

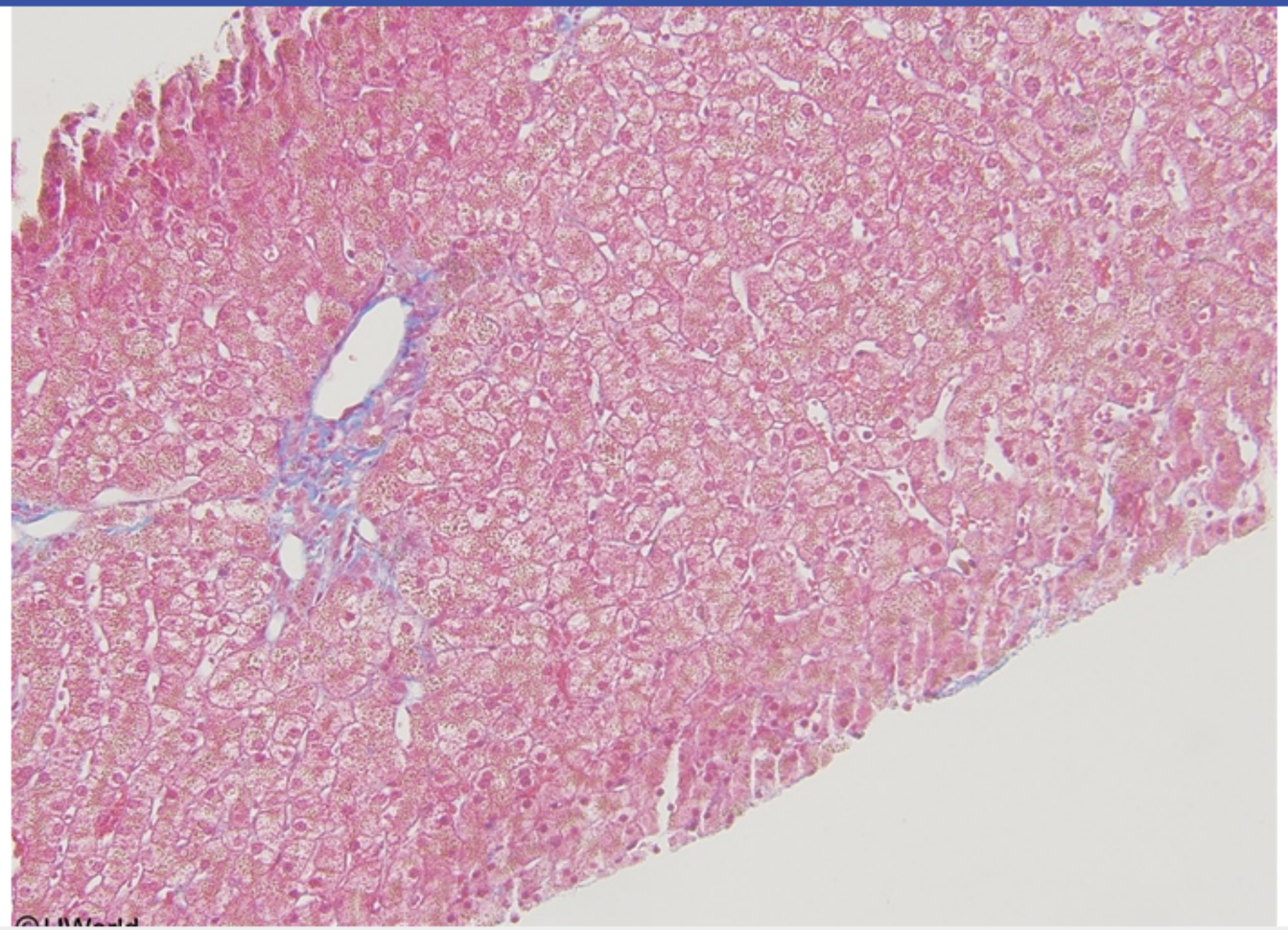

Zoom In | Zoom Out | Reset | Add To New Card | Existing Card

centrilobular regions (zone 3) where hepatic congestion is most prominent. The centrilobular necrosis, combined with relatively normal appearing

Block Time Remaining: 00:01:55
TUTOR

8 | Feedback | Suspend | End Block

Settings

1 2 3 4 5 6 7 8 9 10 11 12 13 14 15 16 17 18 19 20 21 22 23 24 25 26 27 28 29 30

Item 40 of 40
Question Id: 15535

Mark | Previous | Next | Full Screen | Tutorial | Lab Values | Notes | Calculator | Reverse Color | Text Zoom | Settings

©UWorld

Exhibit Display

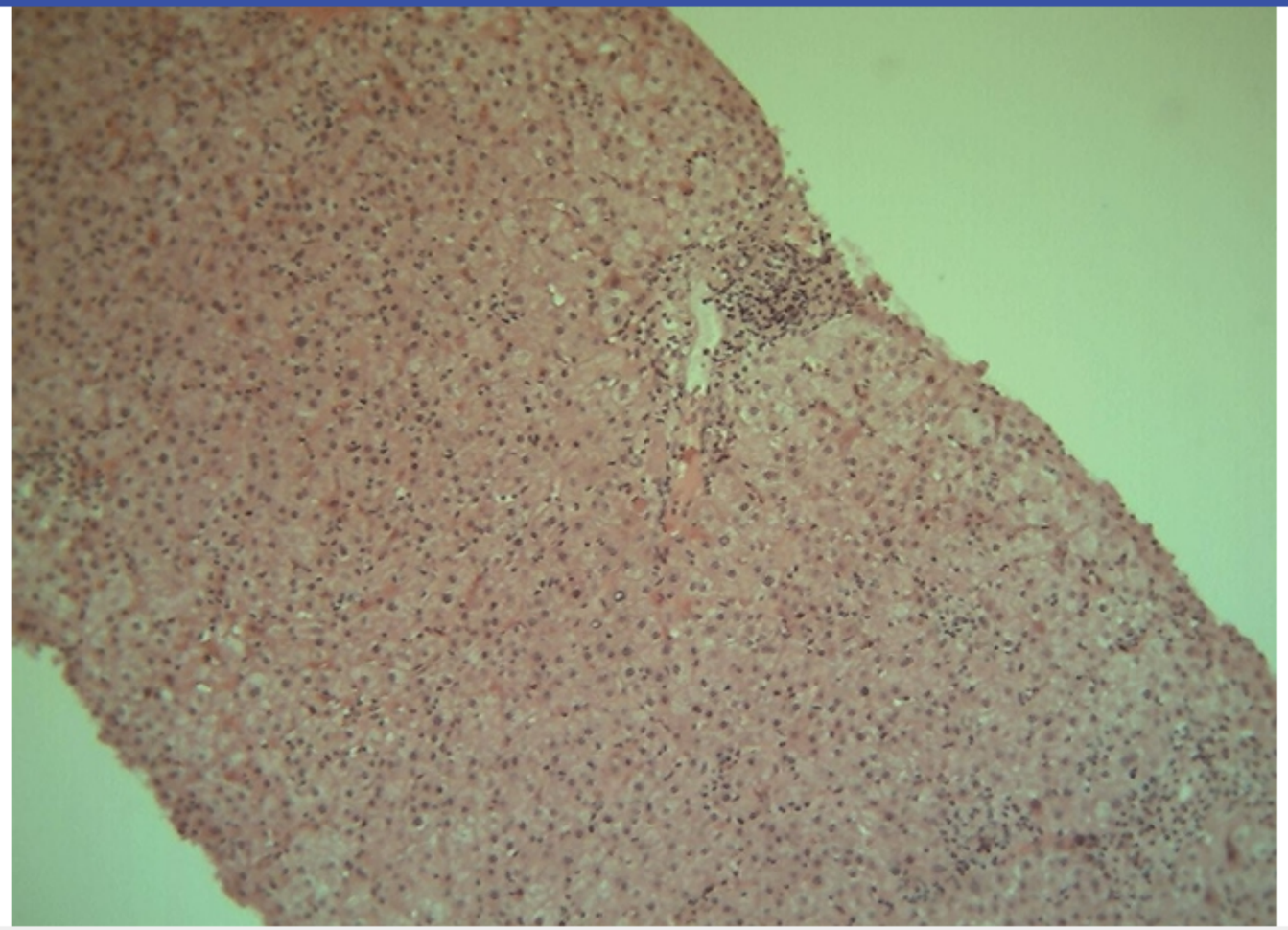

Zoom In | Zoom Out | Reset | Add To New Card | Existing Card

centrilobular regions (zone 3) where hepatic congestion is most prominent. The centrilobular necrosis, combined with relatively normal appearing

Block Time Remaining: 00:01:55
TUTOR

8 | Feedback | Suspend | End Block

prominent. On microscopy, patchy hemorrhage is seen surrounding the central veins consistent with **centrilobular necrosis**. These areas of

Exhibit Display

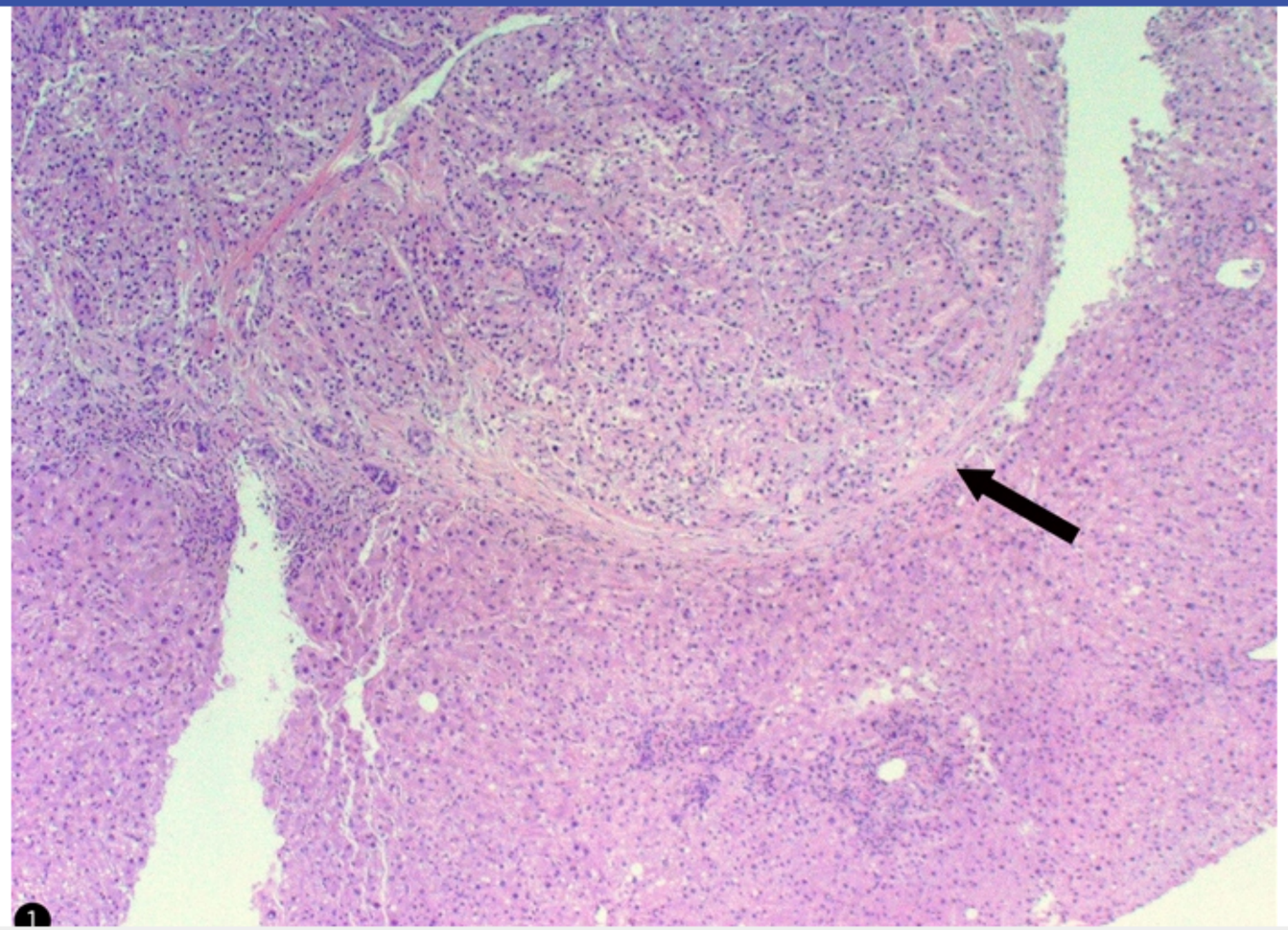

Zoom In | Zoom Out | Reset | Add To New Card | Existing Card